3,655/C/2 Vol 2 Plates 1-372

A 376 2 Bde

FRORIEP, L. F. & R.

267
48

Dr Landry.
DOCTEUR LANDRY
AU LOCLE
Suisse

WELLCOME
HISTORICAL
MEDICAL
LIBRARY
30716z

Luxationen.

A.

Fig. 1.

Fig. 2.

Fig. 3.

Fig. 5.

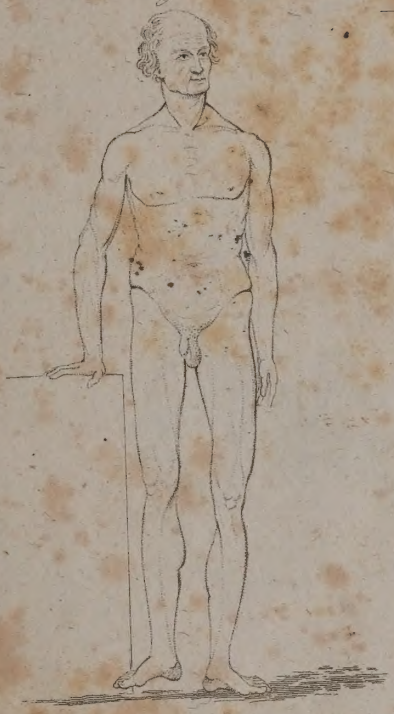

Fractur des Schenkelhalses.

Fig. 4.

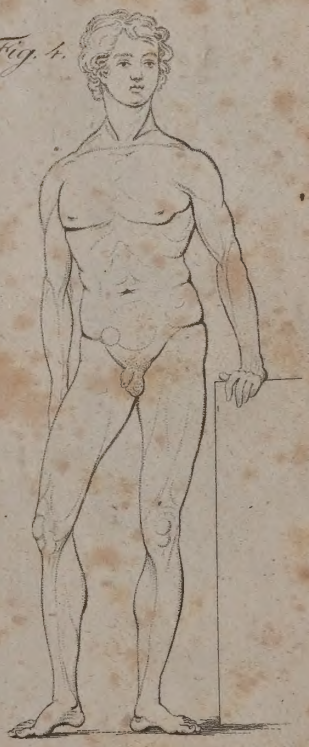

(nach A. Cooper)

Taf. II.

Luxationen
B.

Fig. 1.

Fig. 3.

Fig. 4.

Fig. 5.

Fig. 2.

(nach A. Cooper)

Luxationen.

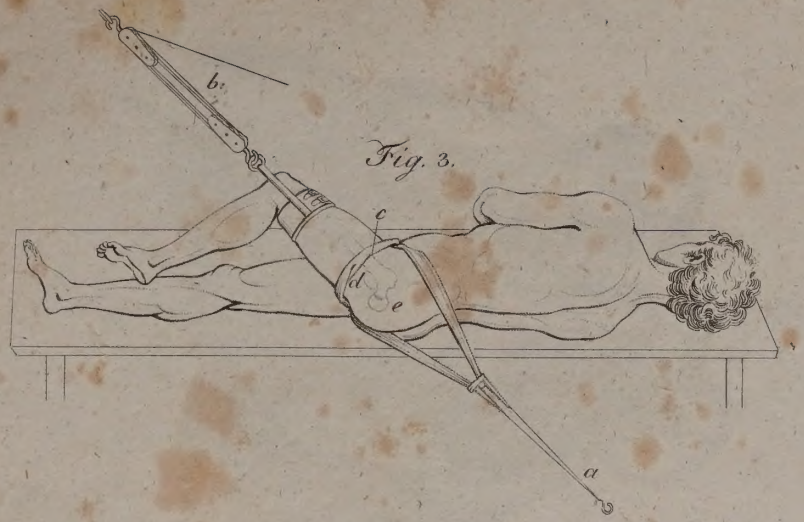

Fig. 3.

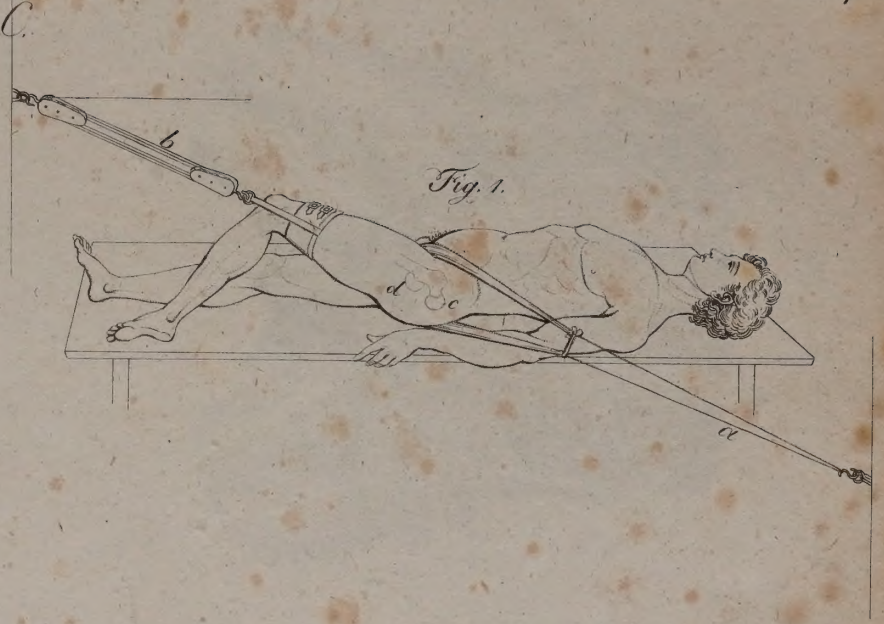

Fig. 1.

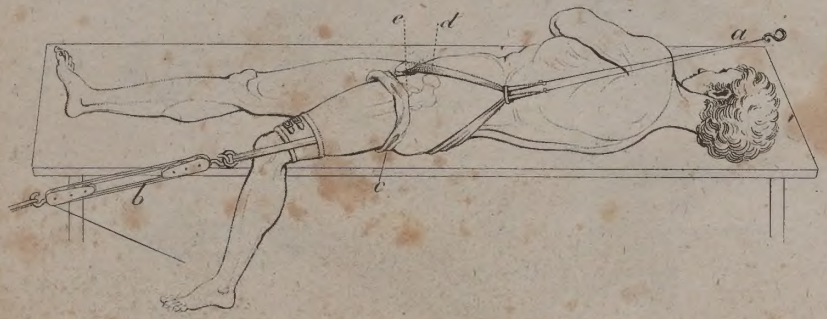

Fig. 4.

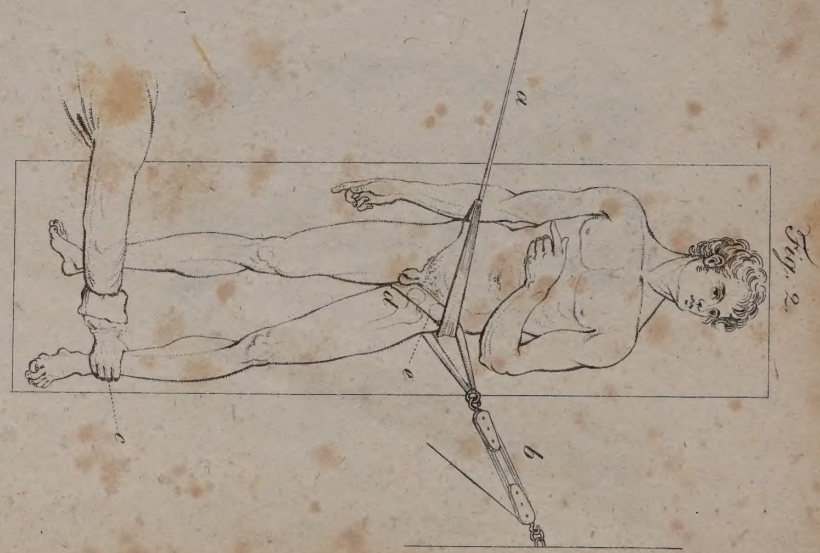

Fig. 2.

(nach A. Cooper)

Hernia

A.

Fig. 1.

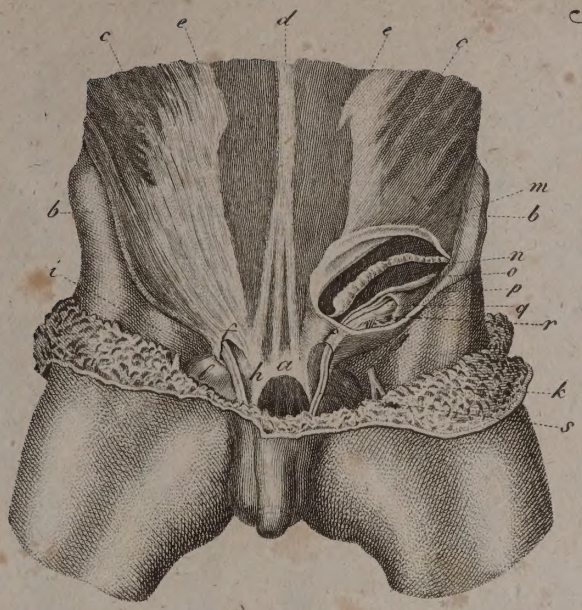

Fig. 2.

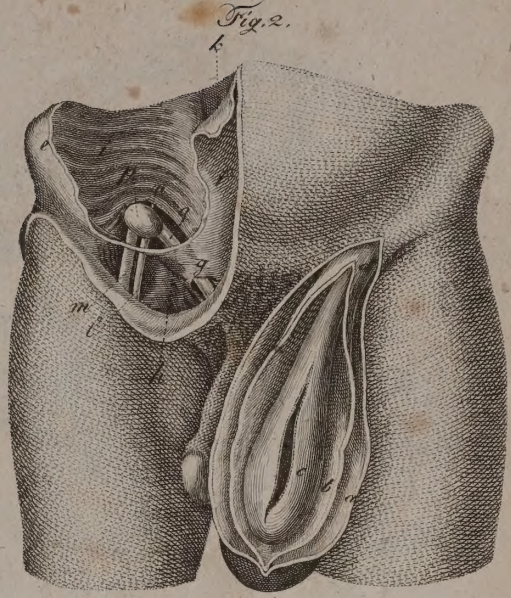

Fig. 3.

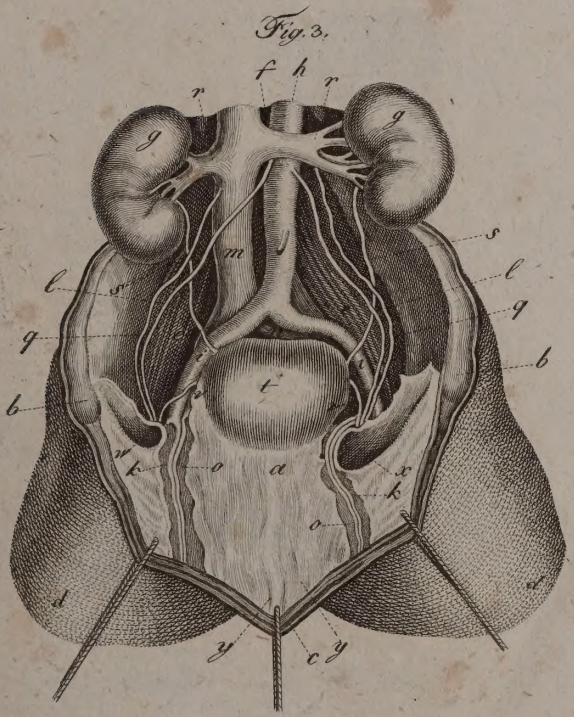

Fig. 4.

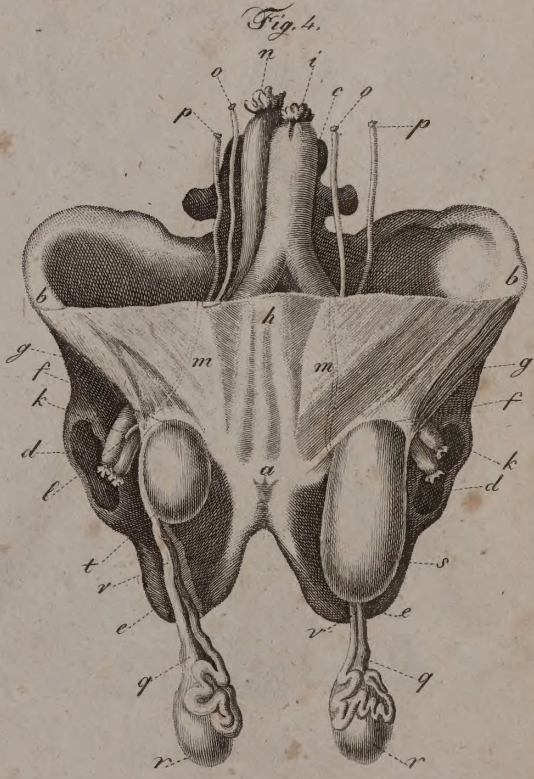

(nach A. Cooper)

Hernia B.

Fig. 1.

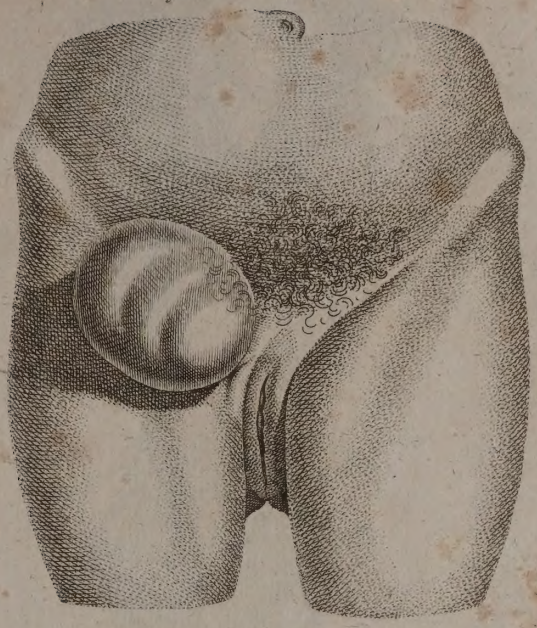

nach Hesselbach

Fig. 2.

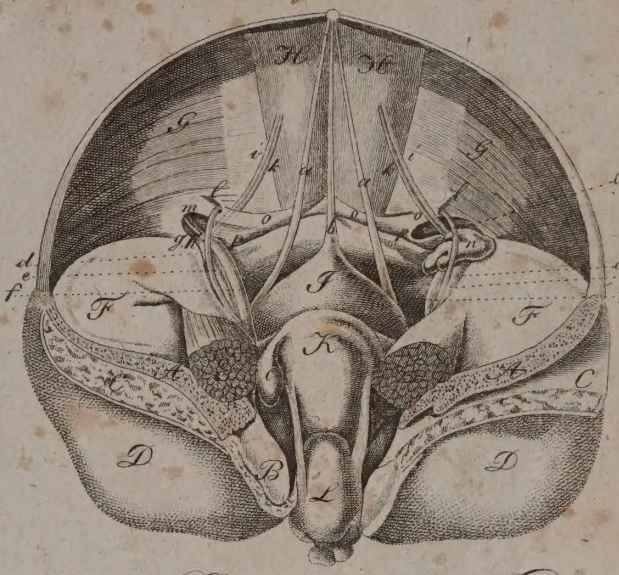

nach Rosenmüller und Walther

Fig. 3.

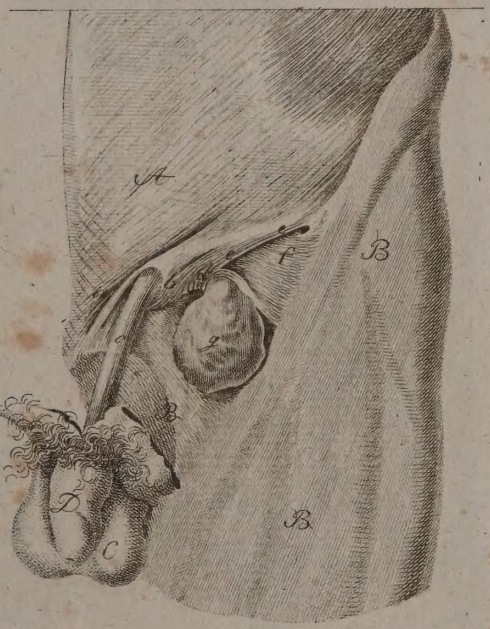

nach Rosenmüller und Walther

Fig. 4.

nach Scarpa.

Taf. VI.

Fractura A.

Fig. 1.

Fig. 5.

Fig. 2.

Fig. 4.

Fig. 3.

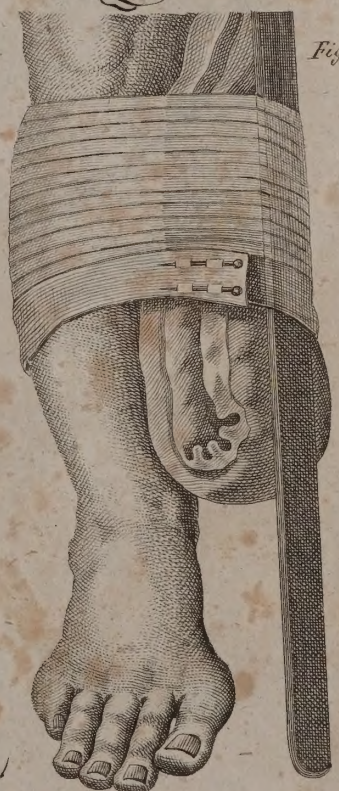

(nach Dupuytren)

Fig. 4.

Hernia C.

Fig. 7. Taf. VII.

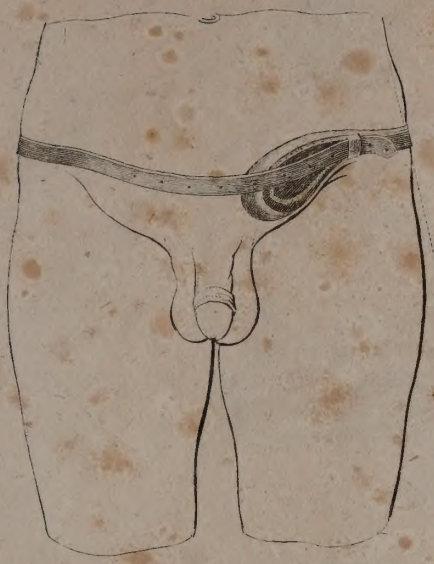

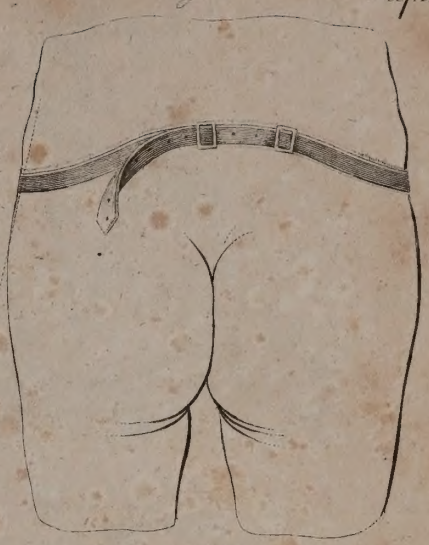

Fig. 3.

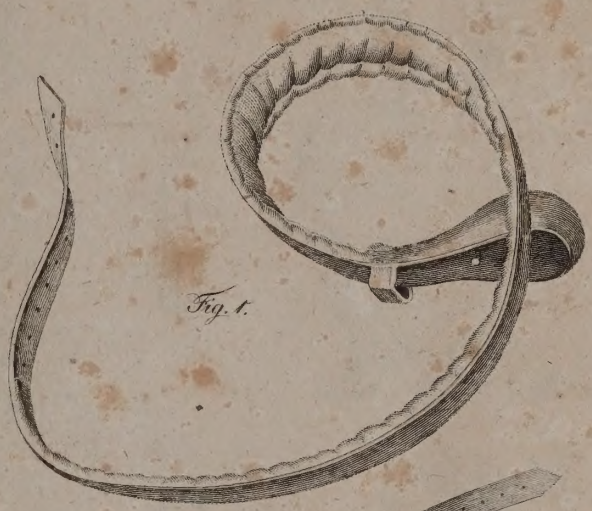

Fig. 1.

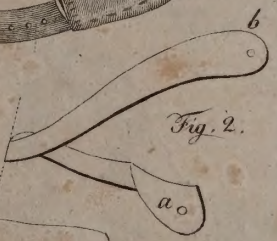

Fig. 2.

Fig. 6.

Fig. 5.

Fractura B.

Fig. 1.

Fig. 2.

Fig. 4.

Fig. 3.

Fig. 5.

Fig. 6.



Fig. 8.

Fig. 7.

Fig. 9.

nach Brüninghausen, Desault und Boyer.

Abscessus coxarius — Luxatio spontanea.

A.

Fig. 1.

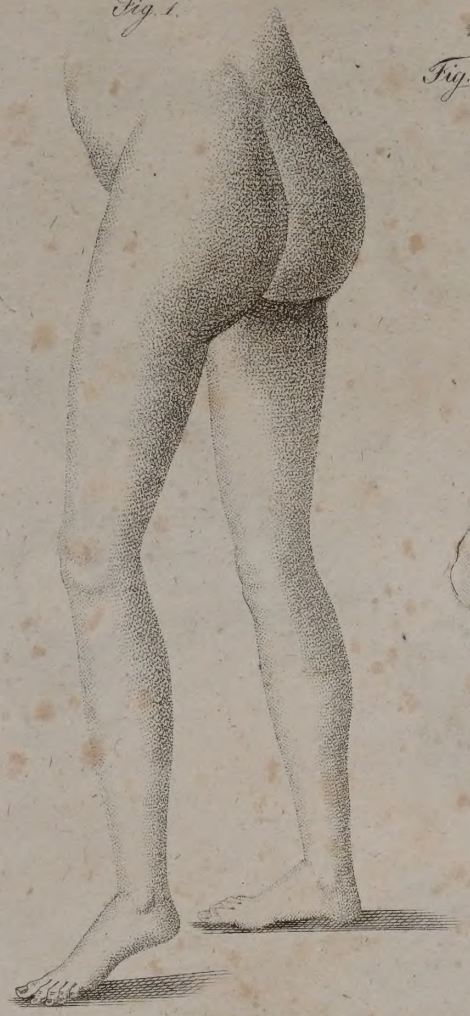

Fig. 4.

Fig. 3.

Fig. 2.

nach Ford und Charles Bell.

Fractura. C.

Fig. 1.

Fig. 4.

Fig. 2.

Fig. 5.

Fig. 3.

Fig. 7.

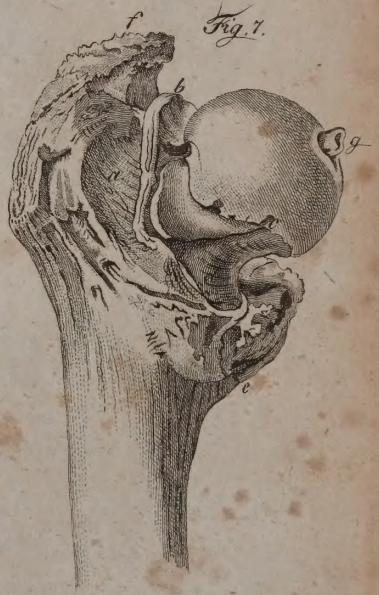

Fig. 6.

nach A. Cooper und Liston.

Stricturа urethrae etc.

Taf. XI.

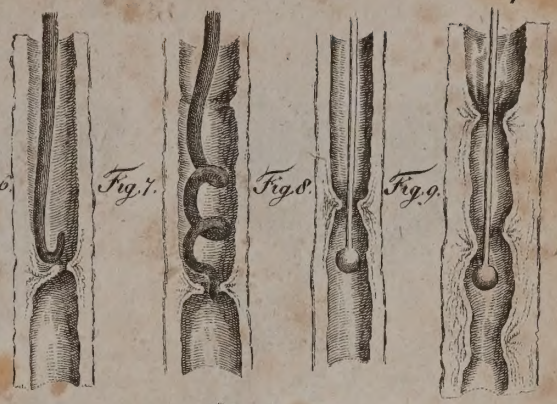

nach Langenbeck u. Charles Bell.

Hernia.

D.

Fig. 1.

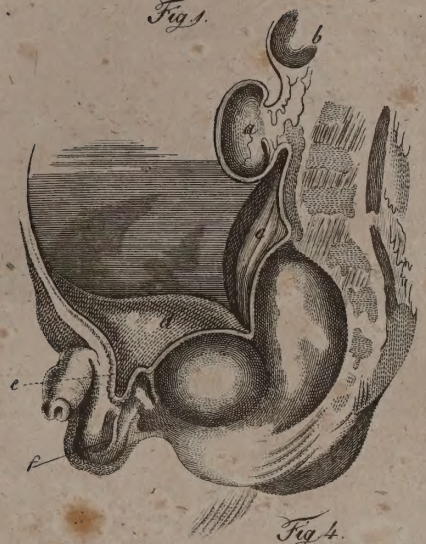

Fig. 2.

Fig. 3.

Fig. 4.

Fig. 5.

Fig. 6.

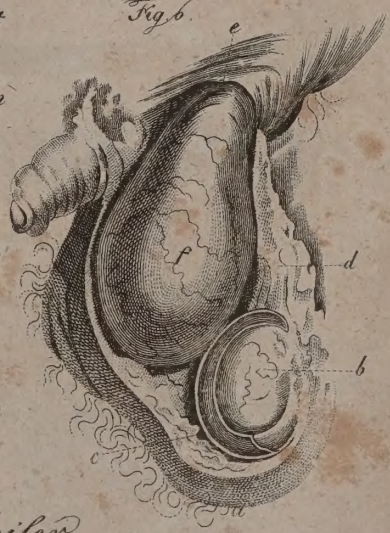

nach John Bell und Seiler.

Fractura D.

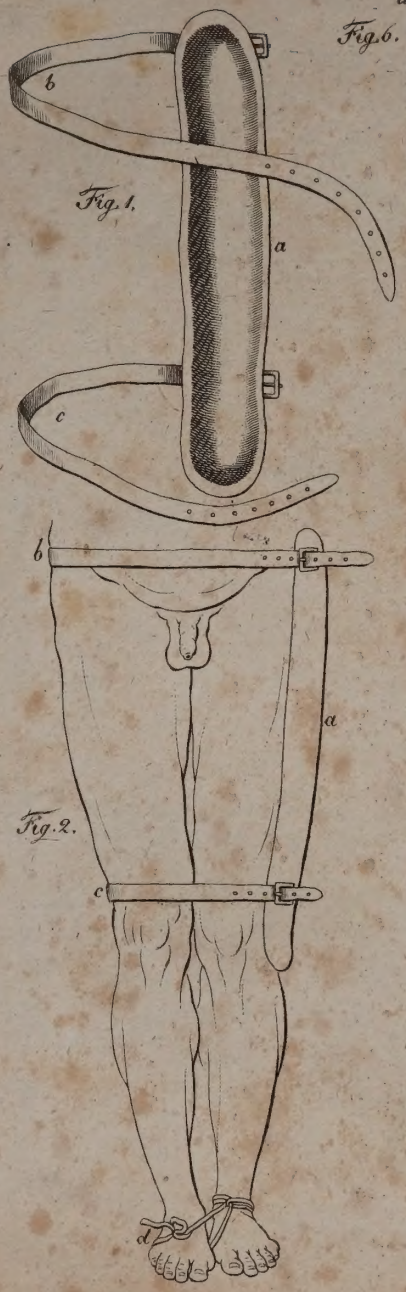

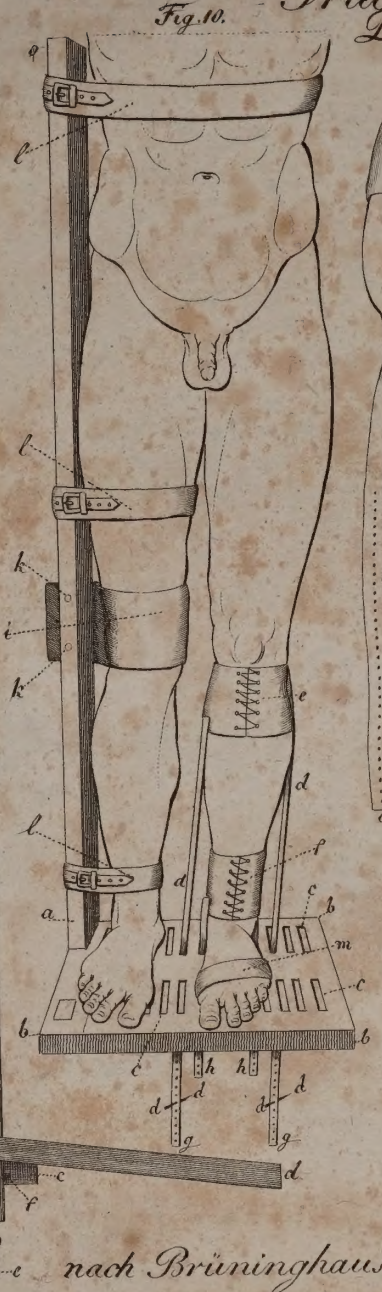



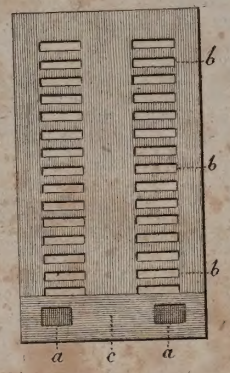

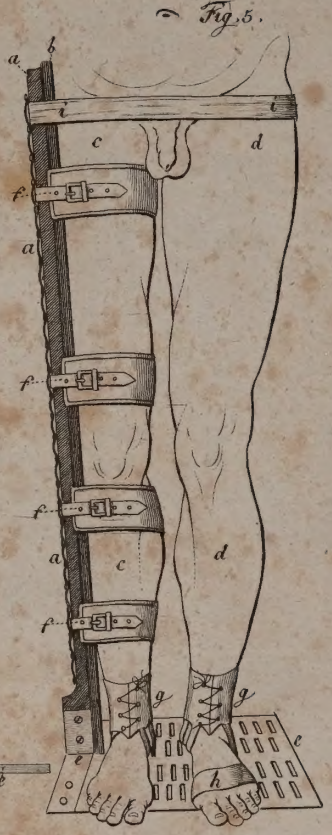

nach Brüninghausen, Hagedorn und Dzondi.

Hydrocele.

Taf. XIV.

nach Cloquet, Schreger und John Bell.

Hydrocele.

Taf. XV.

Fig. 1.

Fig. 2.

Fig. 3.

Fig. 6.

Fig. 4.

Fig. 9.

Fig. 10.

Fig. 8.



Fig. 7.

Fig. 5.

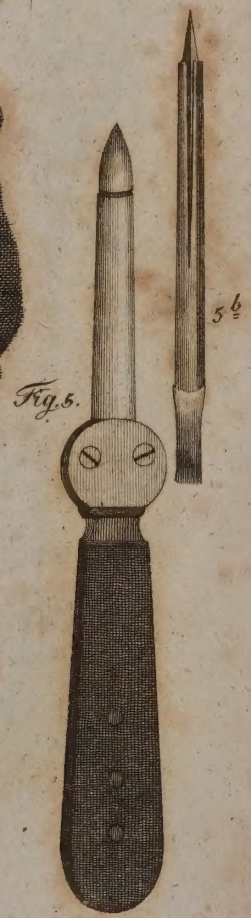

nach Charles Bell, Pott, Earle, Sarigny.

Ligatura. A.

Fig. 3.

Fig. 1.

Fig. 6.

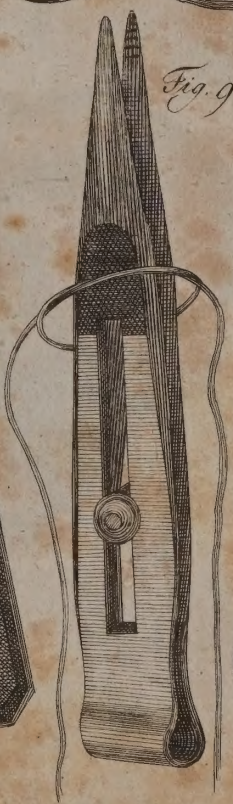

Fig. 9.

Fig. 10.



Fig. 7.

Fig. 8.

Fig. 2.

Fig. 5.

Fig. 4.

Nach Ch. Bell, Savigny u. Ysalini.

Hernia E.

Fig. 1.

Fig. 2.

Fig. 3.

Fig. 5.

Fig. 4.

nach Sandifort und Scarpa.

Sutura.

A.

Fig. 1.

Fig. 2.

Fig. 3.



Fig. 4.

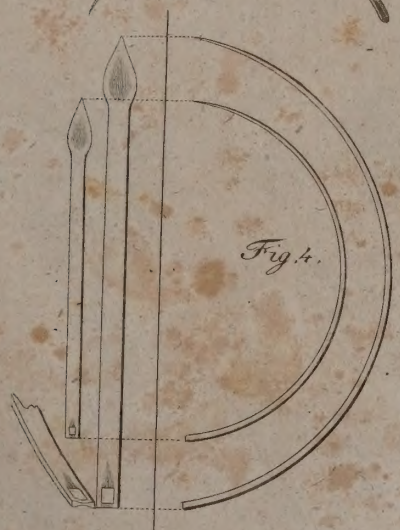

Fig. 5.



Fig. 9.

Fig. 10.

Fig. 8.

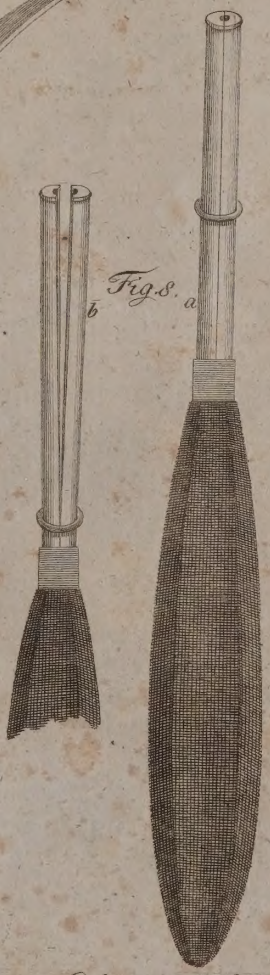

Fig. 6.

Fig. 7.



nach John u. Boni, Bell, Larrey, Savigny, Wolstein, Leber, Asfalini und Graefe.

Herpes.

Fig. 2.

Fig. 3.

Fig. 1.

Fig. 4.

nach Bateman.

Varus et Valgus.

A.

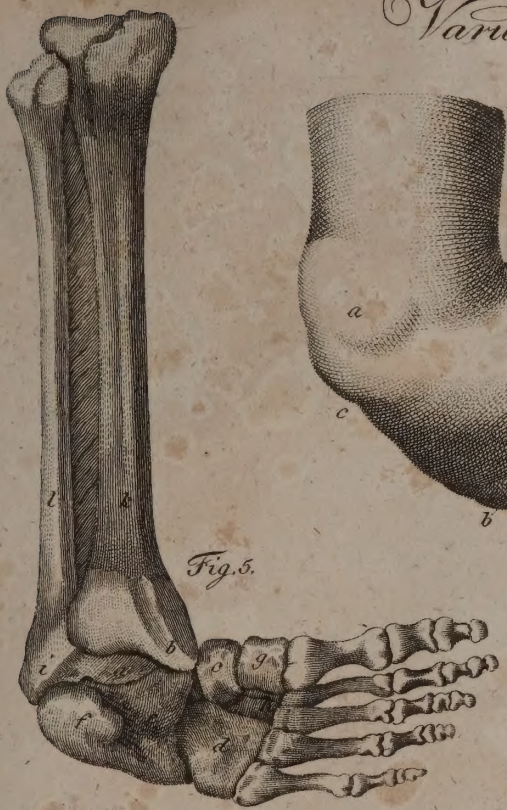

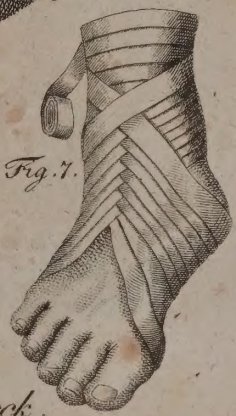

nach Brückner, Scarpa, Joerg u. Langenbeck.

Hernia.

Fig. 2.

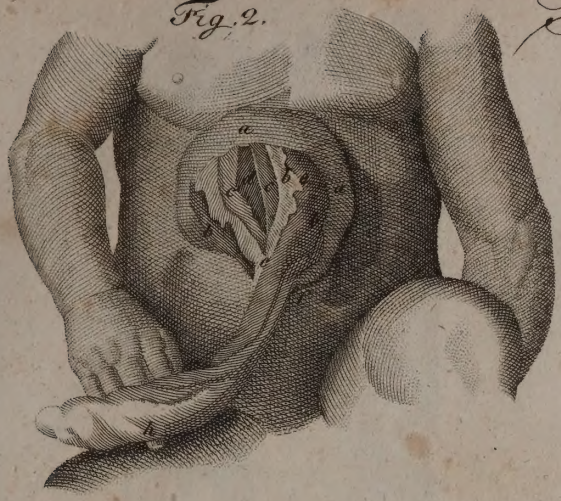

Fig. 3.

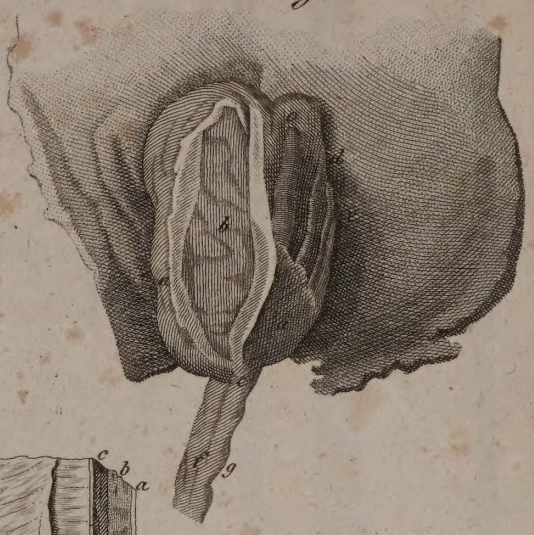

Fig. 1.

Fig. 6.

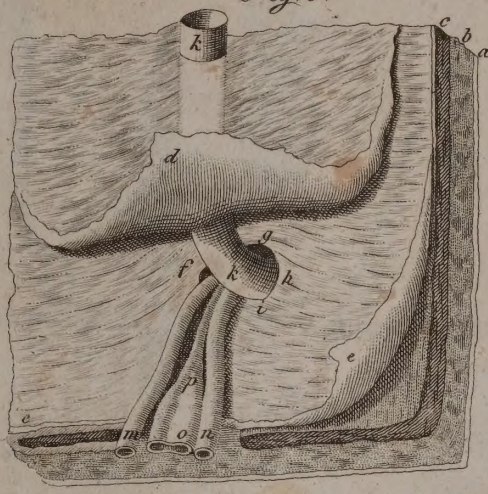

Fig. 4.

Fig. 5.



nach Scarpa und Soemmering.

Fractura E.

Fig. 3.

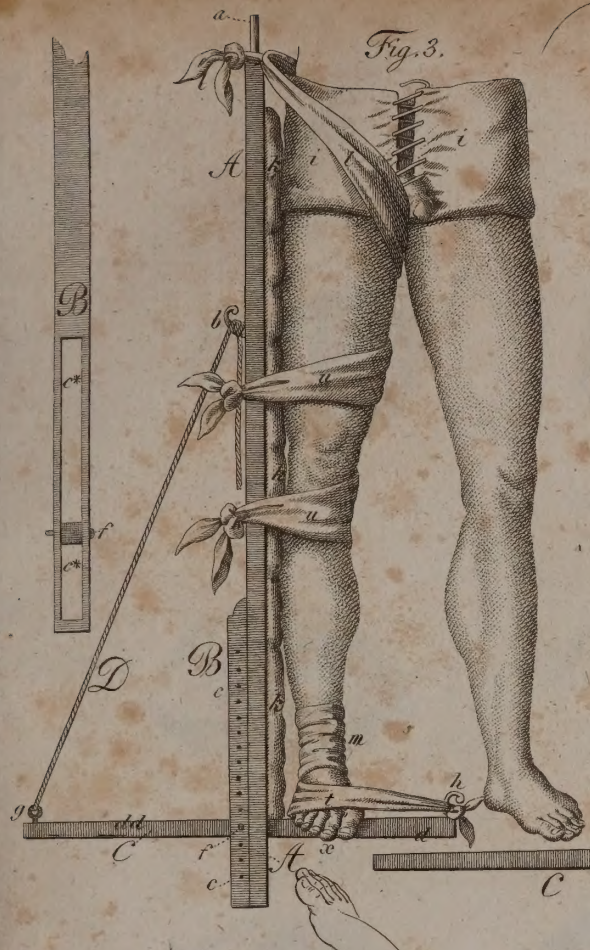

Fig. 4.

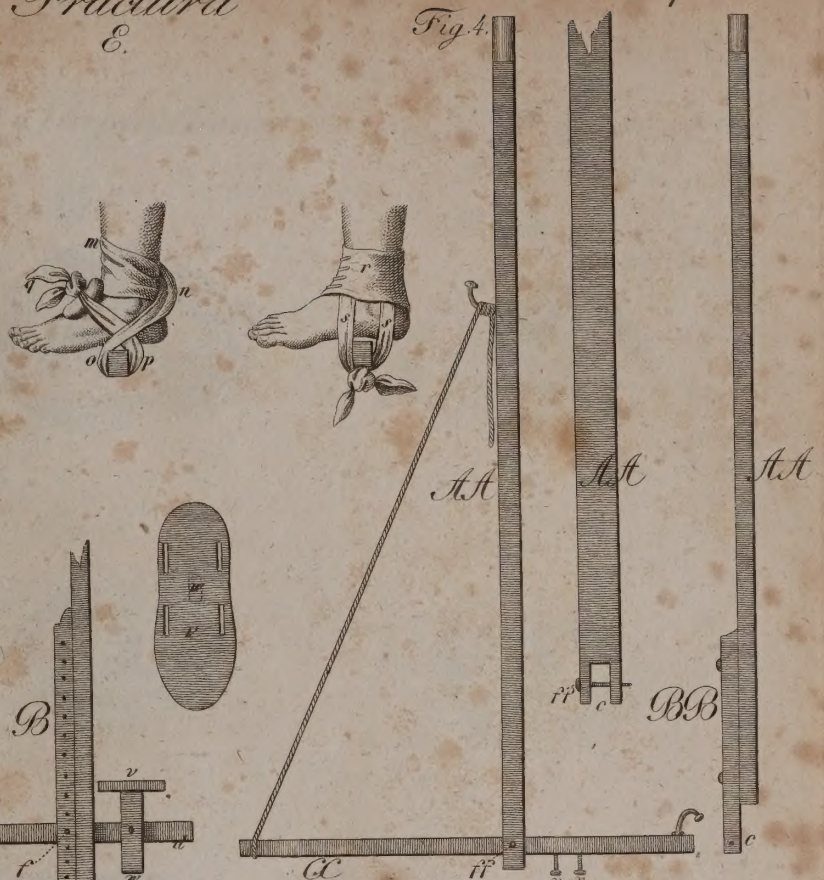

Fig. 2.

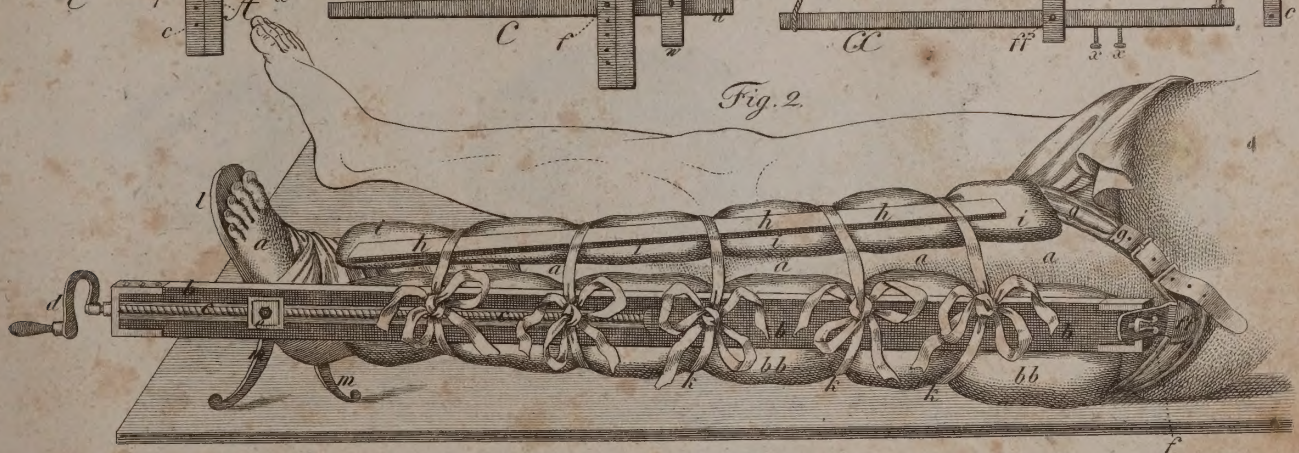

Fig. 1.

nach Desault, Boyer u. Langenbeck.

Staphyloma.

Taf. XXIV. XXV.

Fig. 1.

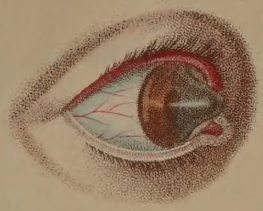

Fig. 2.

Fig. 3.

Fig. 4.

Fig. 5.

Fig. 6.

Fig. 7.

Fig. 8.

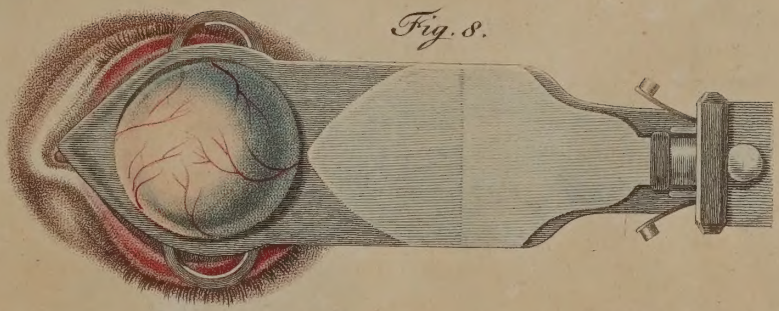

Fig. 9.

Fig. 10.

Fig. 11.

Fig. 12.

nach Demours u. Beer.

Entropium et Trichiasis.

Fig. 1. a.

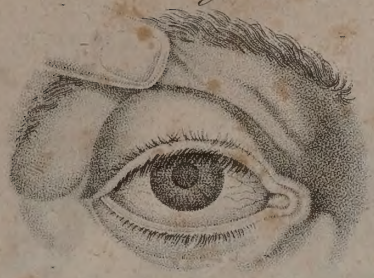

Fig. 1. b.

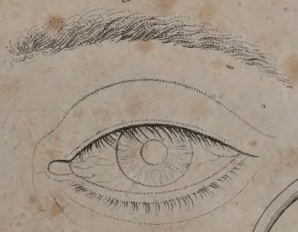

Fig. 3.

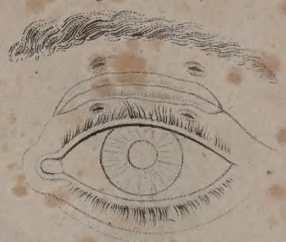

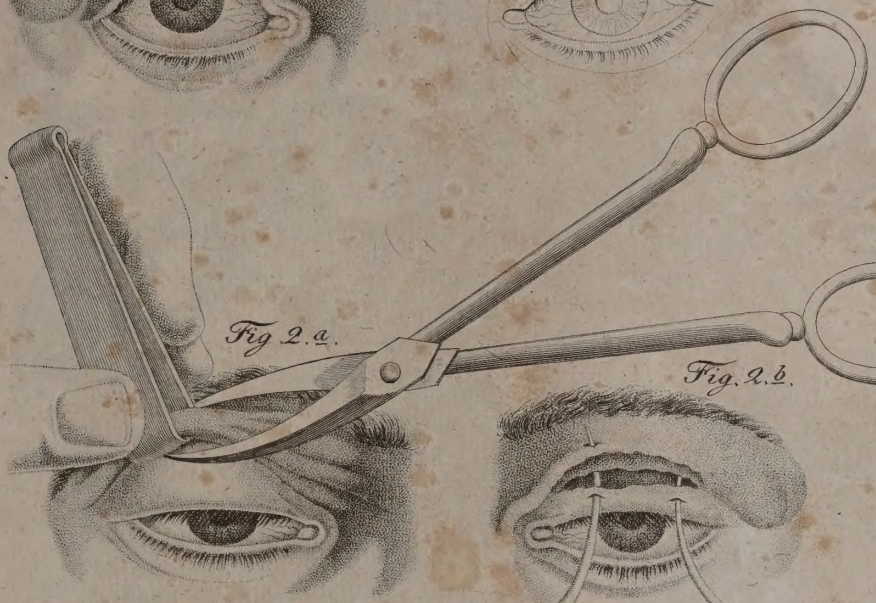

Fig. 10.

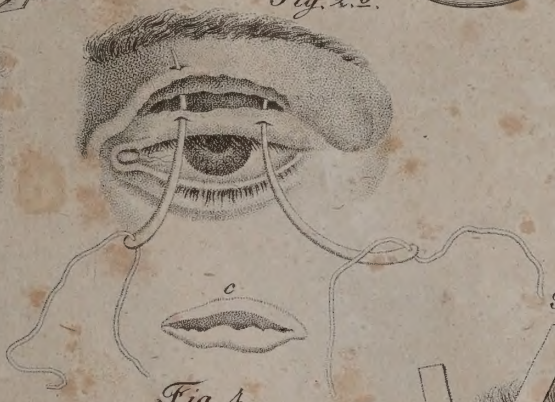

Fig. 4.

Fig. 5.

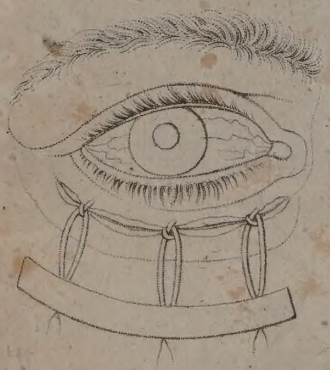

Fig. 9.

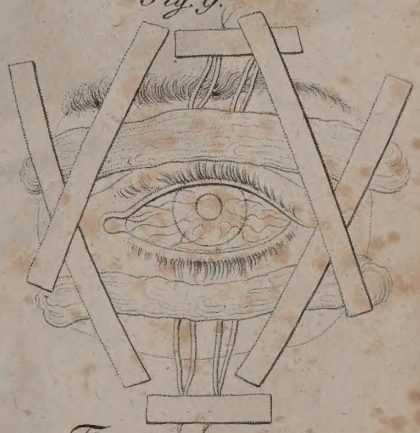

Fig. 6.

Fig. 7.

Fig. 8.

nach Quadri und Beer.

Nach Charles Bell.

Trepanatio

C.

Taf. XXVIII.

Fig. 1.

Fig. 2.

Fig. 3.

Fig. 4.

Fig. 5.



Fig. 6.

Fig. 7.



Nach Charles Bell.

Fig. 1. *Morbi venerei.* Taf. XXIX. XXX.

A.

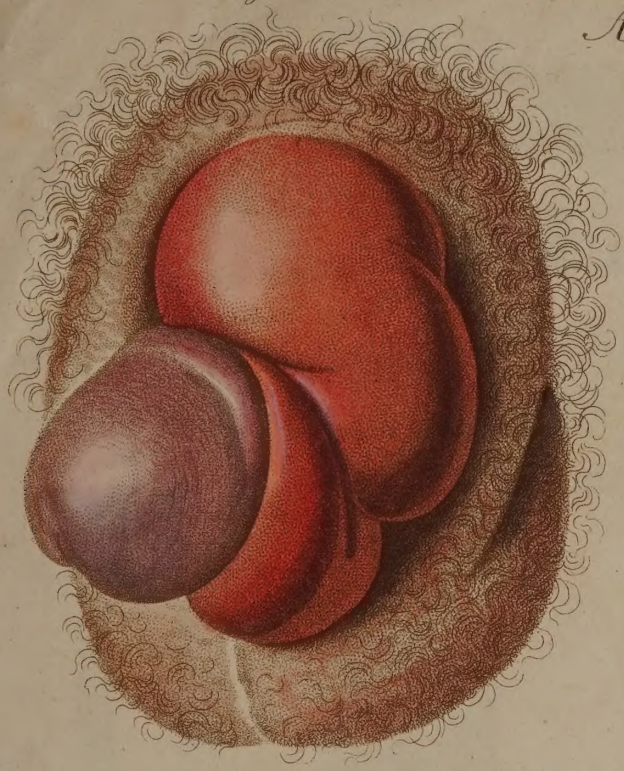

Fig. 2.

Fig. 3.

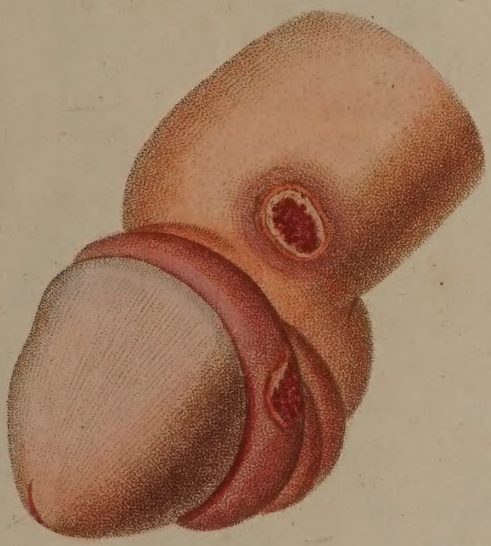

Fig. 4.

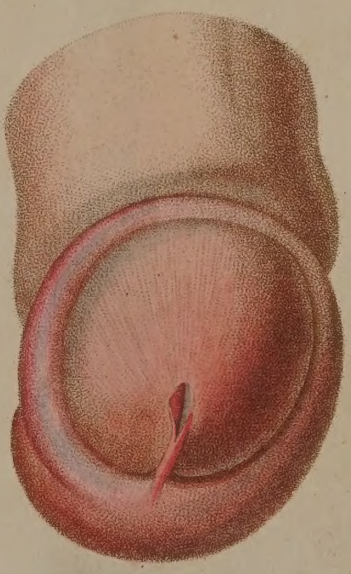

nach Original Zeichnungen.

Trepanatio.

A.

Taf. XXXI.

nach Charles Bell, Savigny und Heine.

Stricturа urethrae

Taf. XXXII.



Fig. 2.

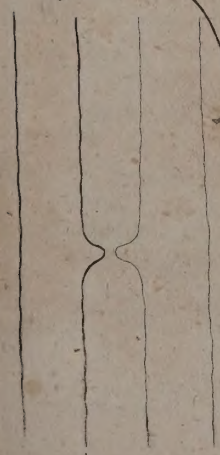

Fig. 3.

Fig. 1.

Fig. 6.

Fig. 4.

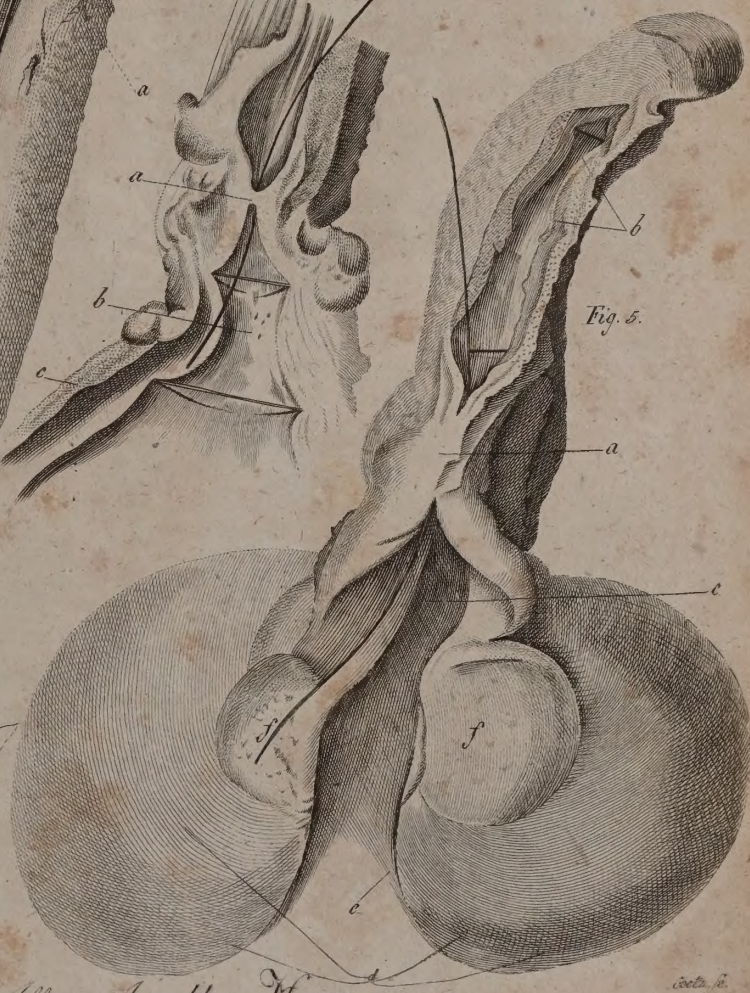

Fig. 5.

nach Allan, Arnott u. Home.

coelt. fe.

Fractura.

F.

Fig. 1.

Fig. 2.

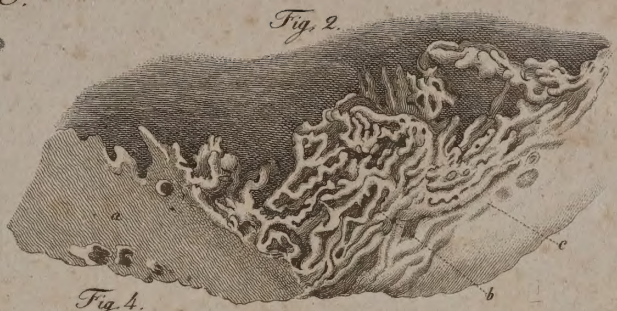

Fig. 3.

Fig. 4.

Fig. 6.

Fig. 5.

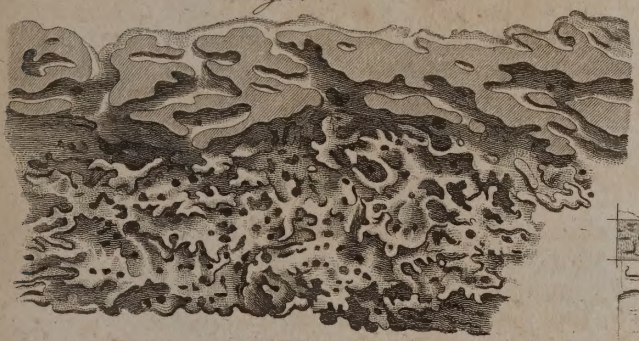

Fig. 7.

Fig. 8.

nach Howship.

Cataracta.

A.

Fig. 1.

Fig. 2.

Fig. 3.

Fig. 4.

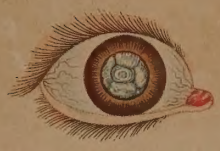

Fig. 5.

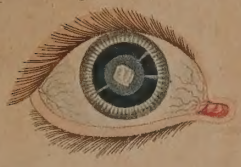

Fig. 6.

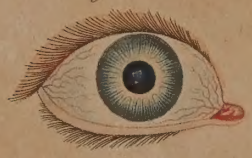

Fig. 7.

Fig. 8.

Fig. 9.

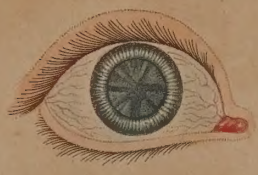

Fig. 10.

Fig. 11.

Fig. 12.

nach Demours, Saunders u. Beer.

Varus et Valgus.

B.

Fig. 1.

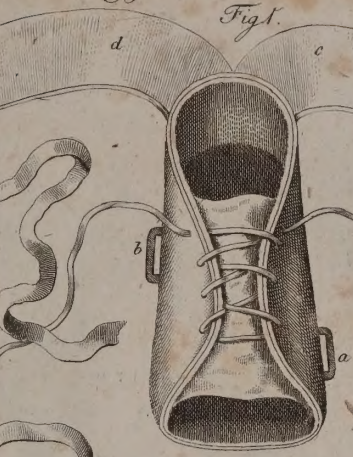

Fig. 2.



Fig. 3.

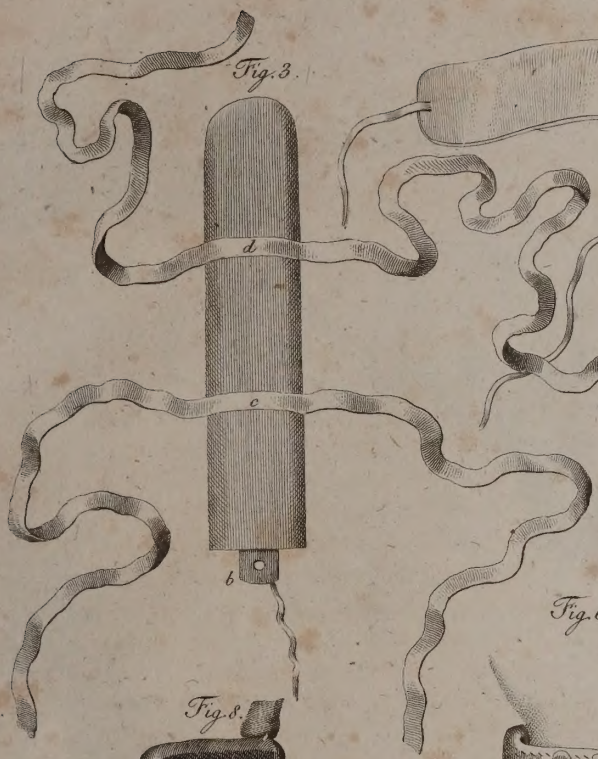

Fig. 4.

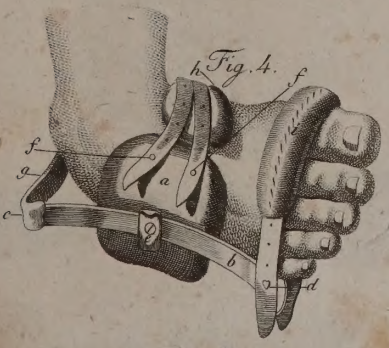

Fig. 5.

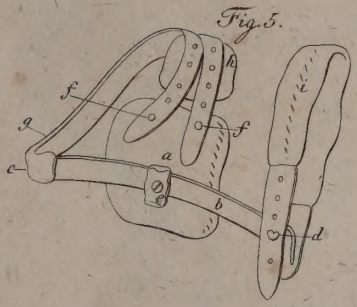

Fig. 6.

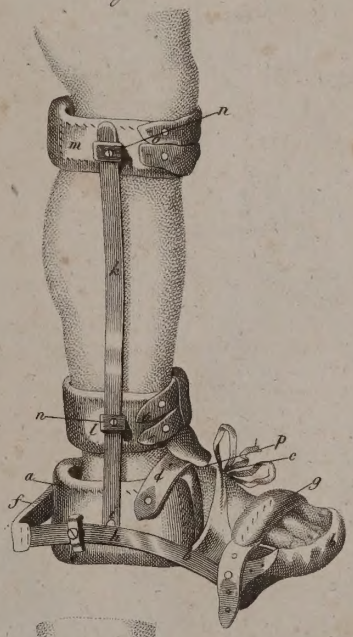

Fig. 7.



Fig. 8.

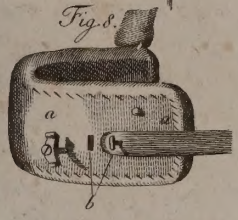

Fig. 9.

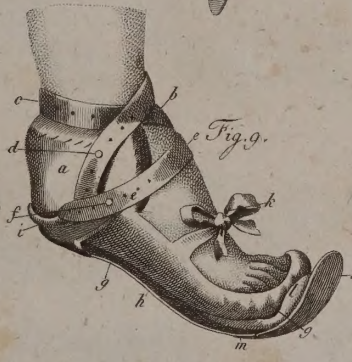

Fig. 10.

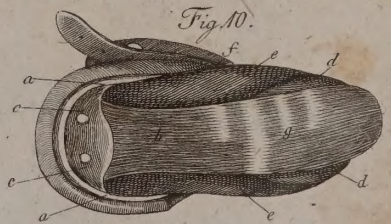

nach Colles und Scarpa.

Fig. 1. *Phimosis et Paraphimosis.* Taf. XXXVII.

Fig. 3.

Fig. 2.

Fig. 4

Fig. 5.

Fig. 6.

Fig. 7.



nach Wadd und Savigny.

Fig. 1.

Fig. 2.

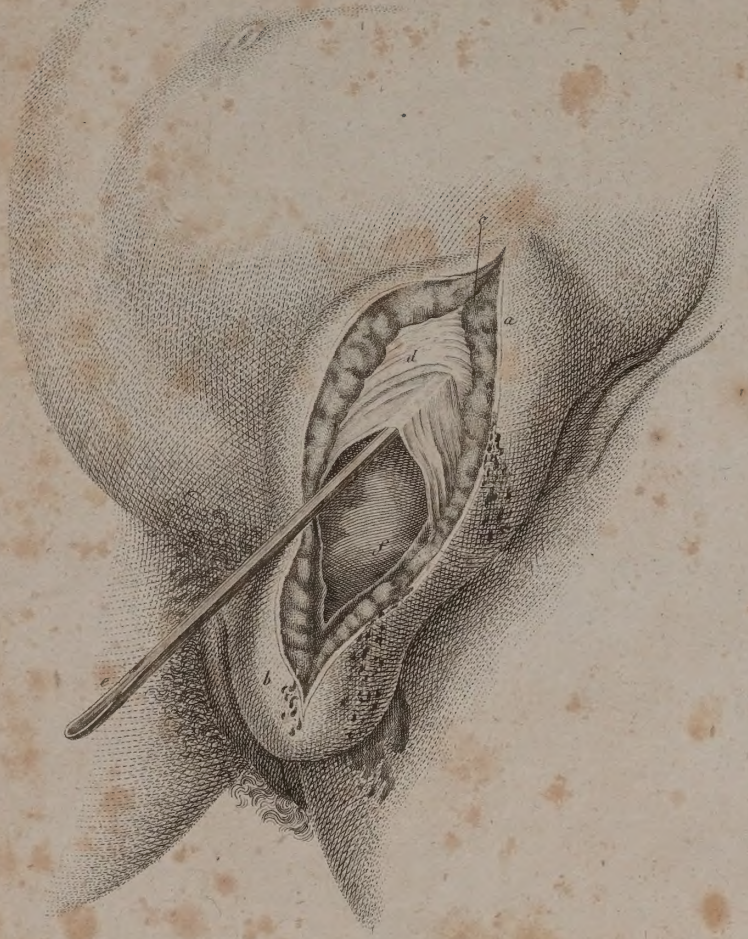

nach Charles Bell.

Porrigo.

Fig. 1.

Fig. 2.

nach Alibert u. Bateman.

39-40

Aneurysma.

A.

Fig. 7.



Fig. 1.

Fig. 5.

Fig. 6.

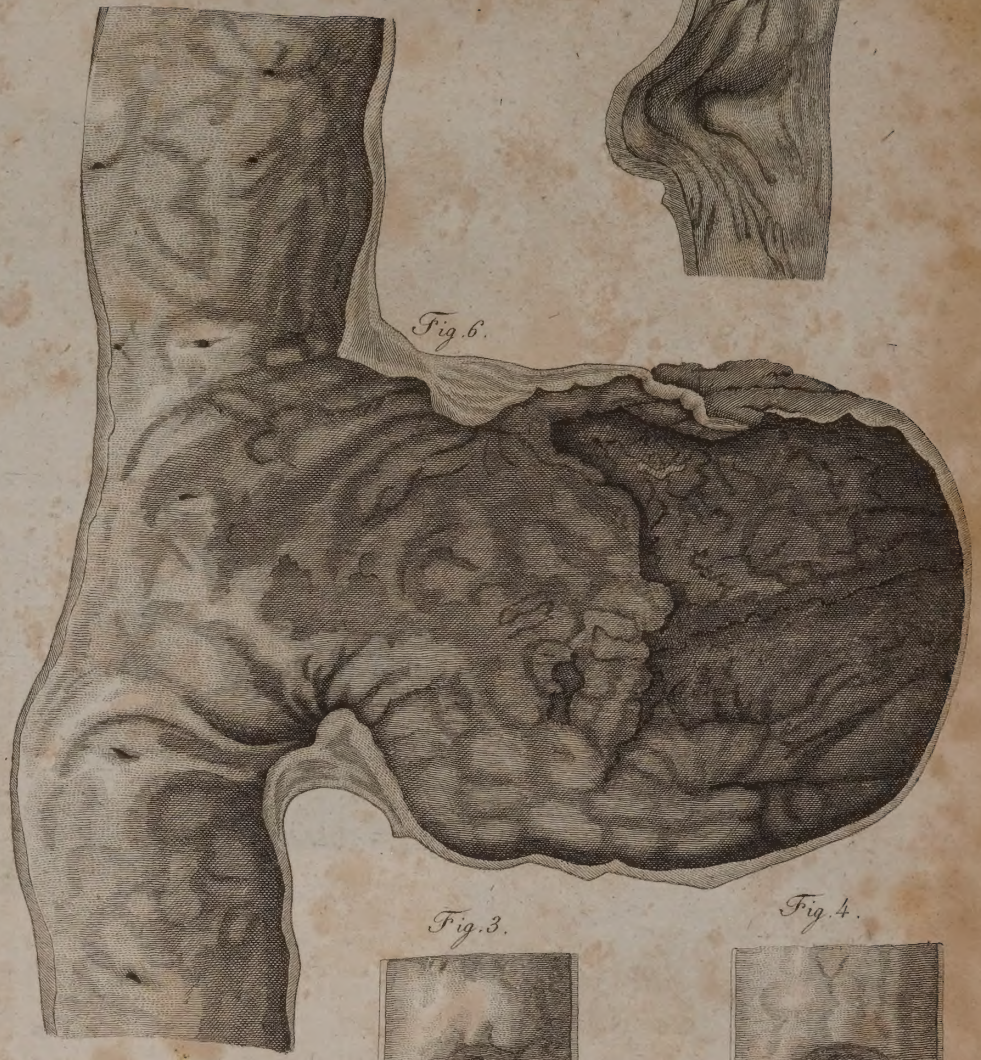

Fig. 2.

Fig. 3.

Fig. 4.

nach Hodgson.

Fig. 1.

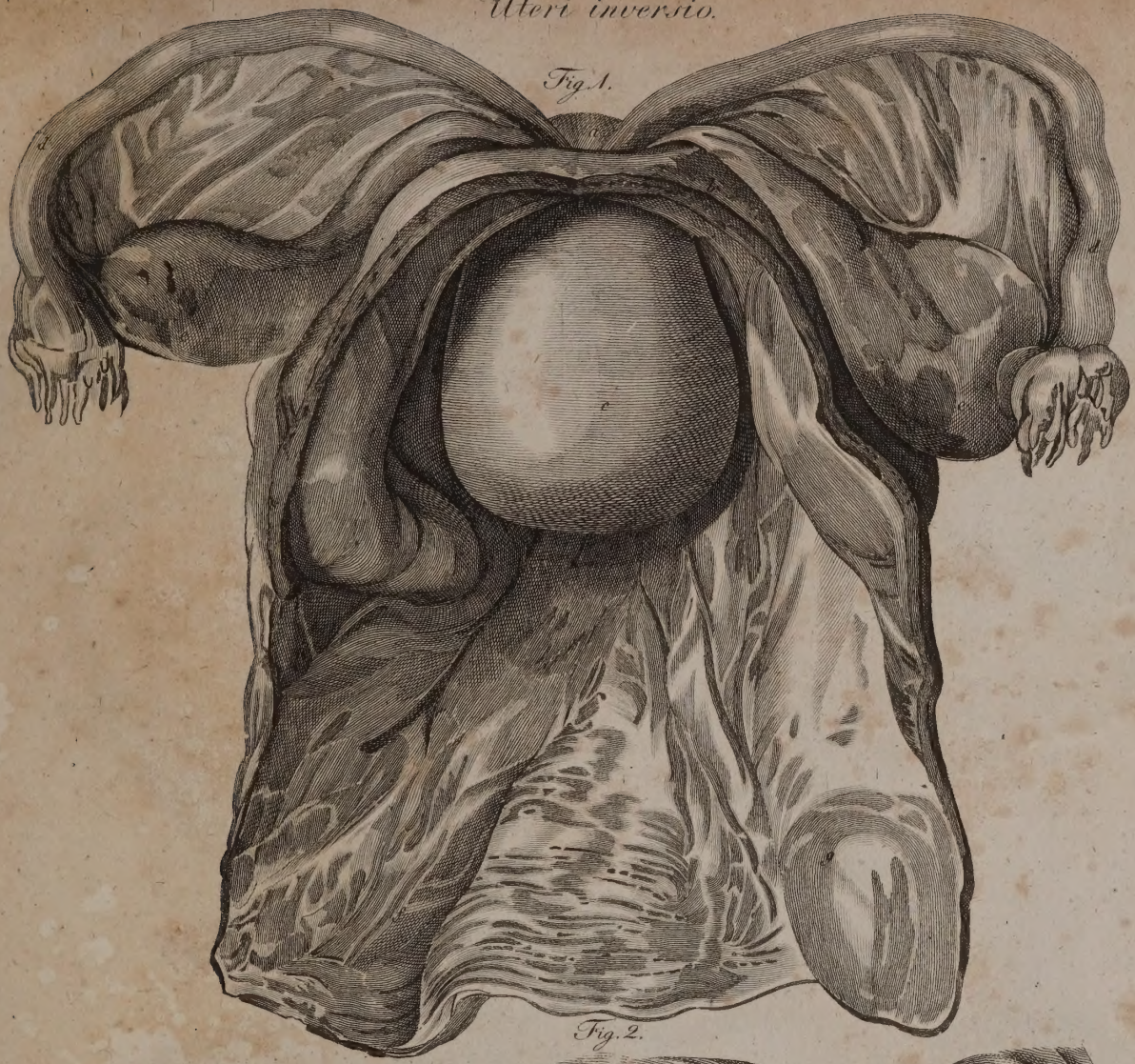

Fig. 2.

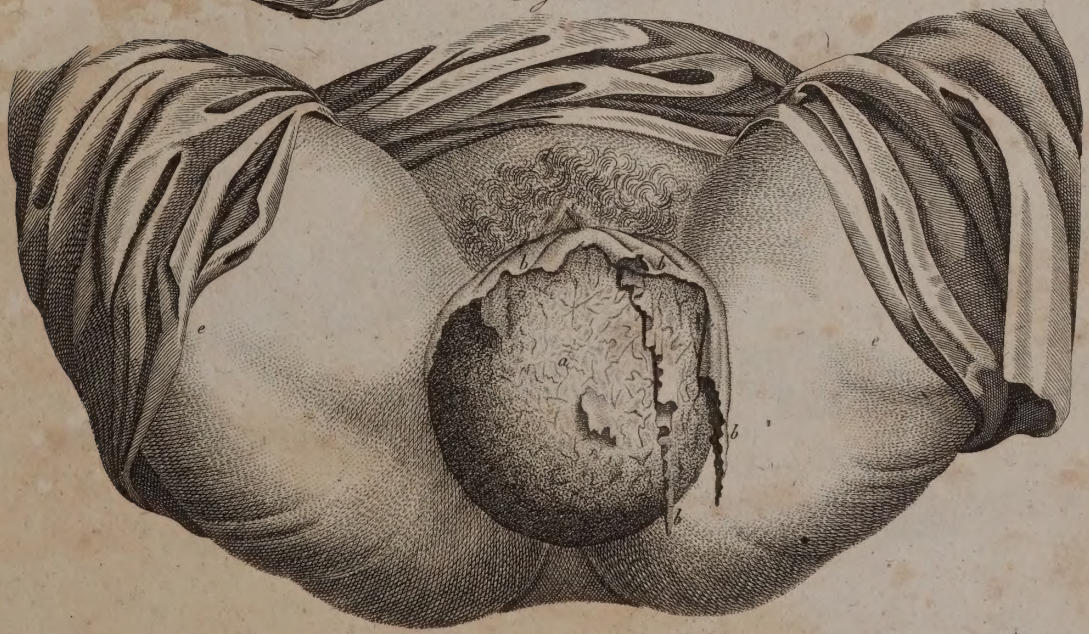

nach Baillie und Fries.

Hernia.

H.

Fig. 2.

Fig. 1.

Fig. 3.

Fig. 4.

Fig. 5.



Fig. 6.

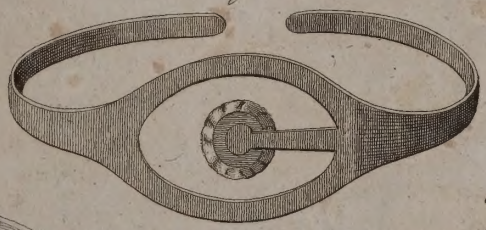

Fig. 7.

Fig. 8.



Fig. 9.

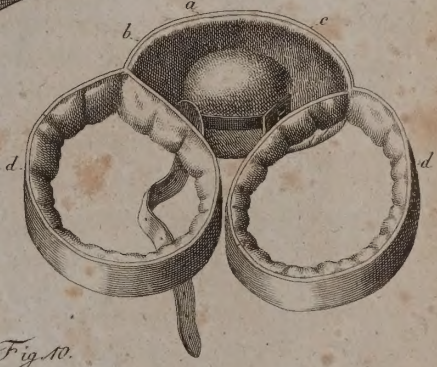

Fig. 10.

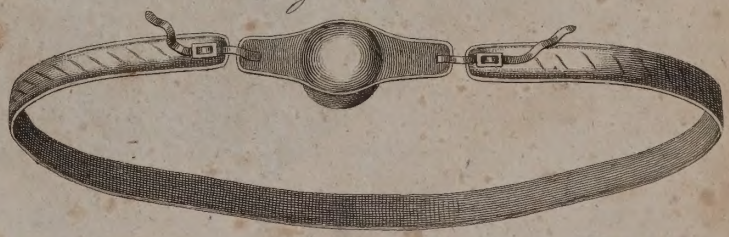

Elephantiasis. *Taf.* XLIV. XLV.

nach Bateman.

Fistula ani.

Taf. XLVII.

A.

Fig. 1.

Fig. 2.

nach Baillie und Richerand

Hernia.

Fig. 1.

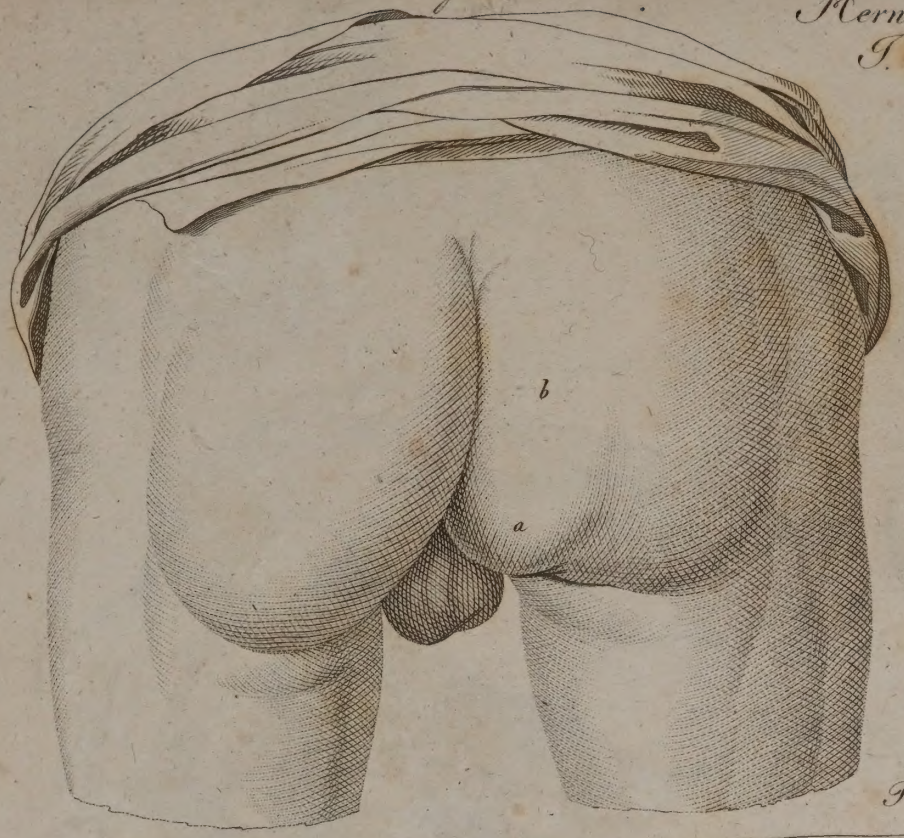

Fig. 3.

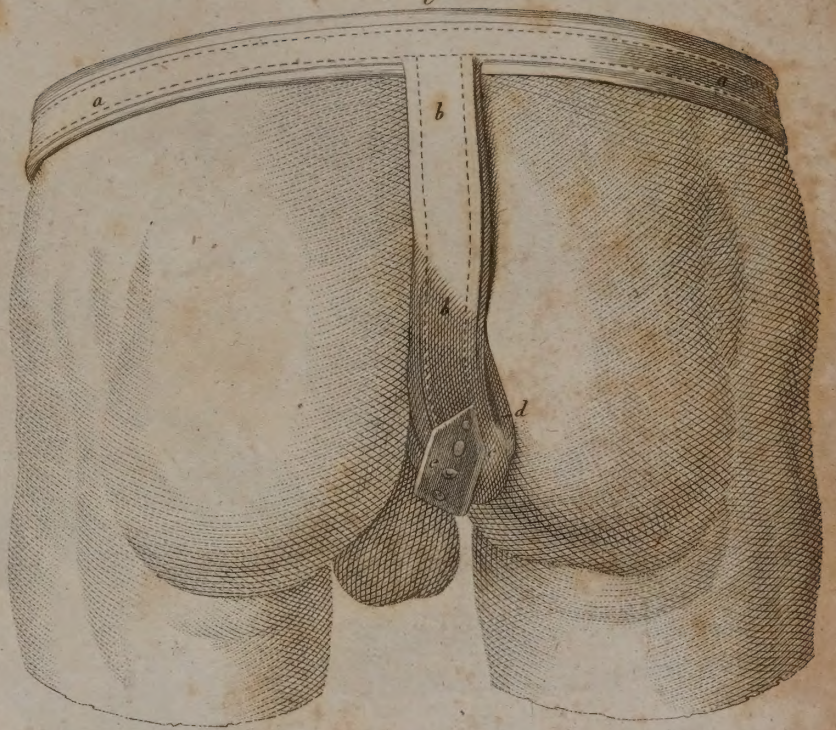

Fig. 2.



Scarpa.

Hernia.

Naevus

Fig. 2.

Fig. 3.

Fig. 4.

Fig. 1.

nach Batemann.

Exarticulatio A.

Fig. 2.

Fig. 1.

Fig. 3. b.

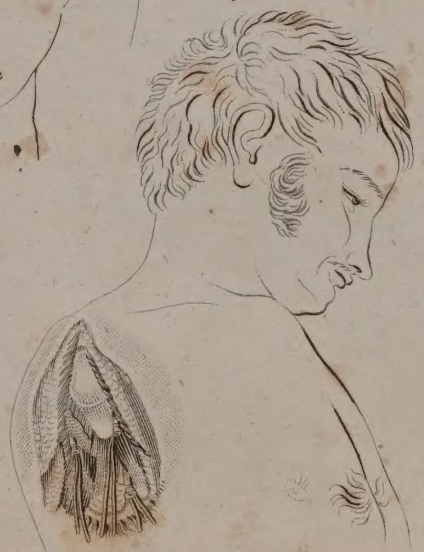

Fig. 3. a.

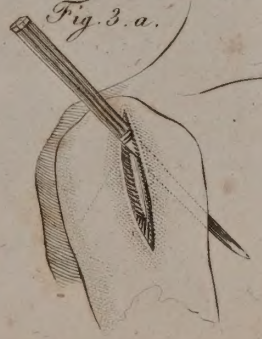

Fig. 3. c.

Lithotomie.

B.

Fig. 1.

Fig. 2.

Fig. 3.

Fig. 4.

Fig. 5.

Fig. 6.

nach Ch. Bell.

Aneurysma.

B.

Fig. 1.

Fig. 2.

Fig. 3.

Fig. 4.

Fig. 5.

nach, Hodgson.

B. Fig. 1.

Fig. 3.



Fig. 4.

Fig. 5.

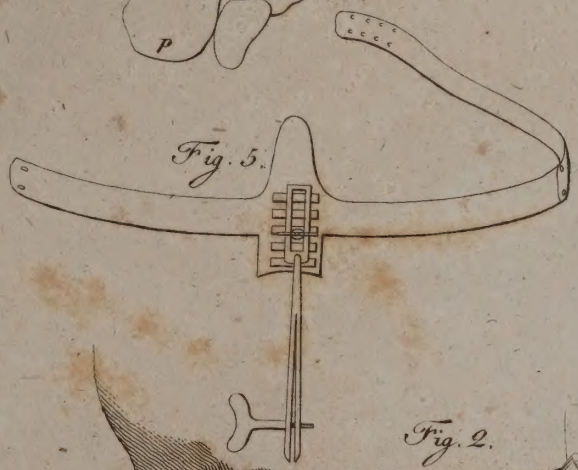

Fig. 2.

Luxatio.
D.

Fig. 1.

Fig. 3.

Fig. 5.

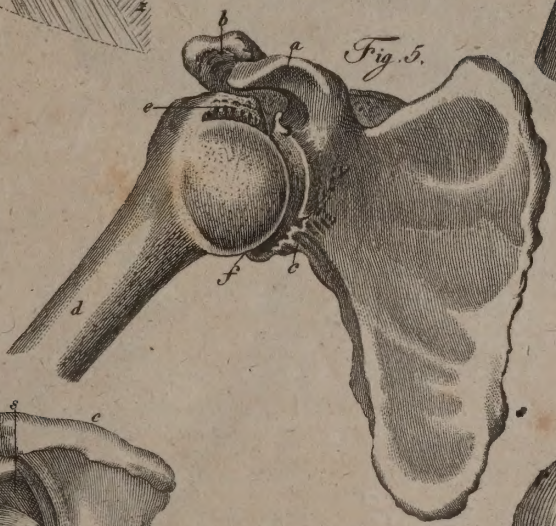

Fig. 2.

Fig. 4.

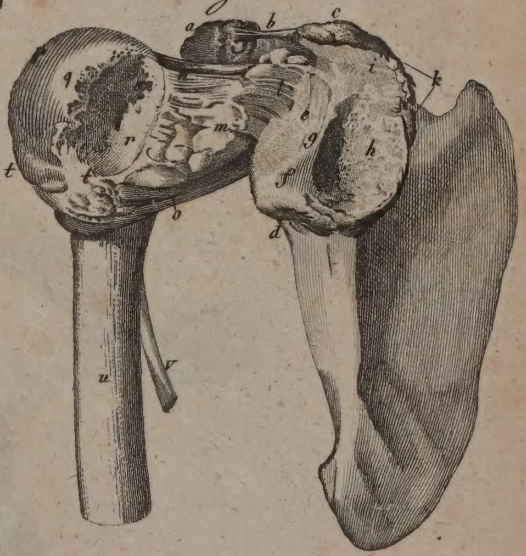

nach Bonn und Howship.

Anus praeternaturalis.

Fig. 2.

Fig. 3.

Fig. 1.

Fig. 4.

nach Scarpa, Lawrence u. Juville.

Anus praeternaturalis.

Taf. LVII.

B.

Fig. 7.

Fig. 8.

Fig. 9.

Fig. 5.



Fig. 4.

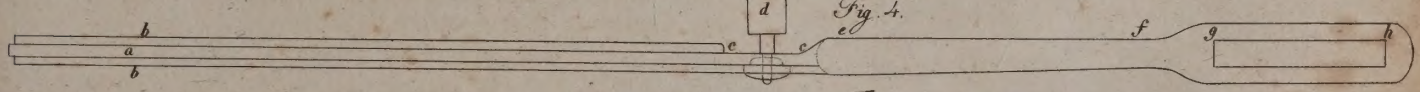

Fig. 3.



Fig. 2.

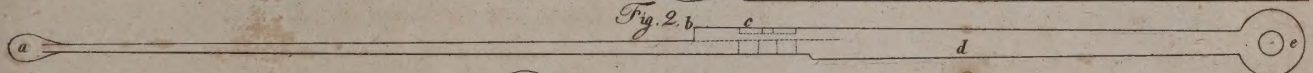

Fig. 6.

Fig. 1.

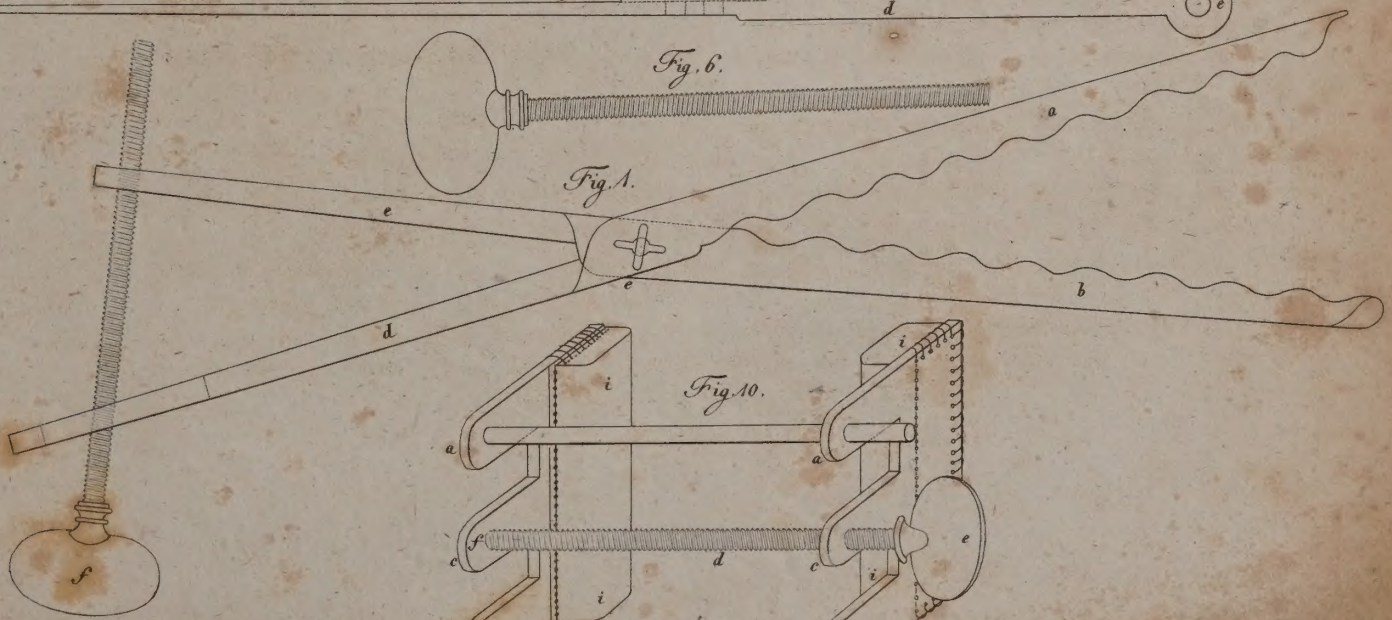

Fig. 10.

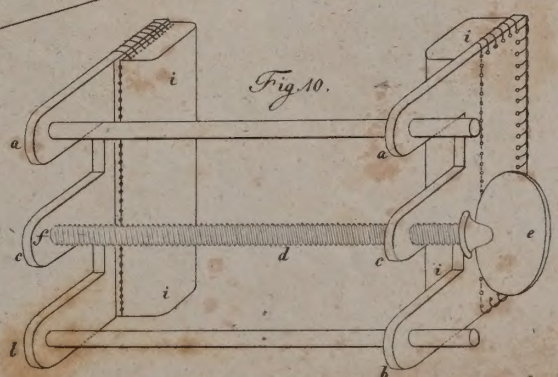

Iritis.

Fig. 1.

Fig. 2.

Fig. 3.

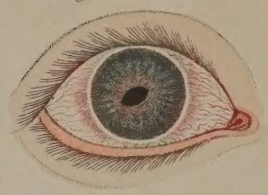

Fig. 4.

Fig. 5.

Fig. 6.

Fig. 7.

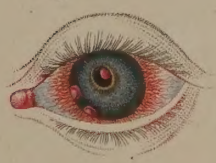

Fig. 8.

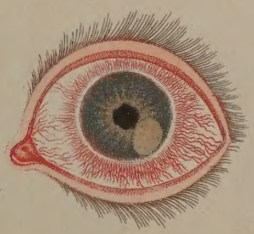

Fig. 9.

Fig. 10.

Fig. M.

nach Beer, Travers und Saunders.

Prolapsus uteri

Taf. LXI

A.

Das Original befindet sich in der Starkschen jetzt mit dem grossherz. Museum vereinigten anat. path. Samlung zu Jena

Fig. 1.

Prolapsus uteri.

Fig. 3.

Taf. LXII.

Fig. 4.

Fig. 2.

Fig. 4.*

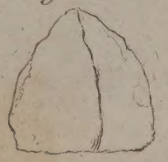

Fig. 4.**

Exarticulatio.

B.

Taf. LXIII.

Fig. 1.

Fig. 2.

Fig. 3.

Fig. 4.

Fig. 5.

Fig. 6.

Fig. 7.

Plica polonica.

Fig. 1.

Fig. 2.

Fig. 3.



Fig. 4.



nach Alibert

Morbi aurium.

A.

Fig. 2.

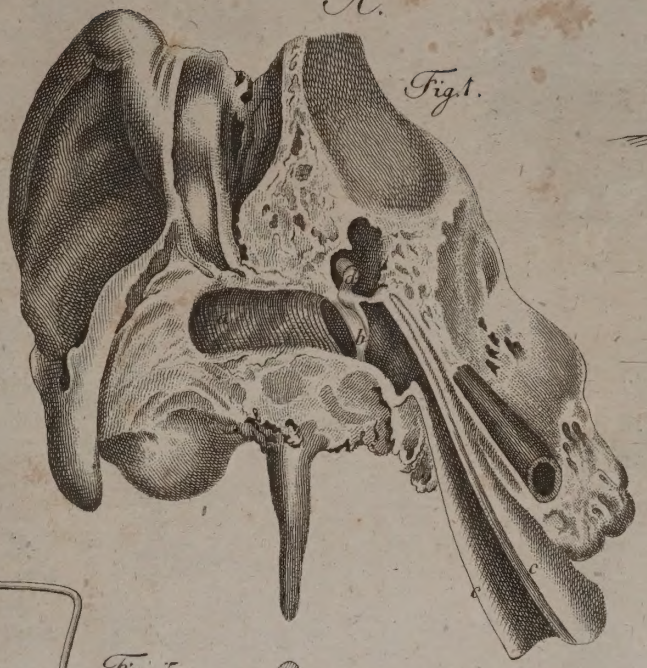

Fig. 1.

Fig. 4.

Fig. 3.



Fig. 5.



Fig. 6.

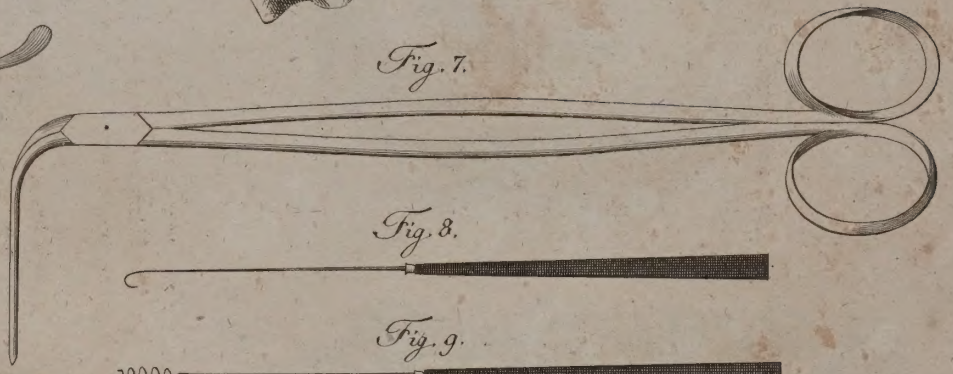

Fig. 7.



Fig. 10.

Fig. 8.

Fig. 9.

Fig. 11.

Spina bifida.

Fig. 1.

Fig. 3.

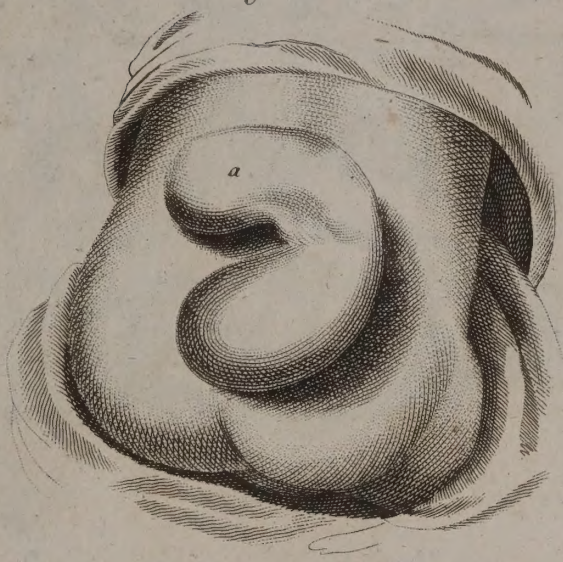

Fig. 2.

Fig. 4.

Exarticulatio humeri.

C.

Taf. LXVII.

Fig. 1.

Fig. 2.

Fig. 3.

Fig. 4.

nach Ch. Bell und Maingault.

Pterygium.

Taf. LXVIII, LXIX, LXX.

Fig. 1.

Fig. 2.

Fig. 3.

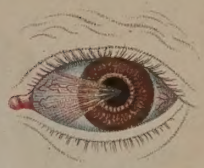

Fig. 4.

Fig. 5.

Fig. 6.

Fig. 8.

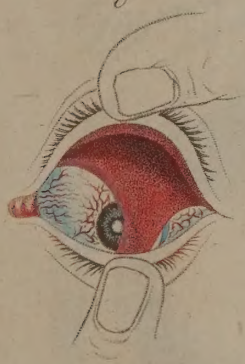

Fig. 9.

Fig. 7.

Fig. 10.

Fig. 11.

nach Demours, Beer, Wardrop und Travers.

Lithotomia.

Fig. 1.

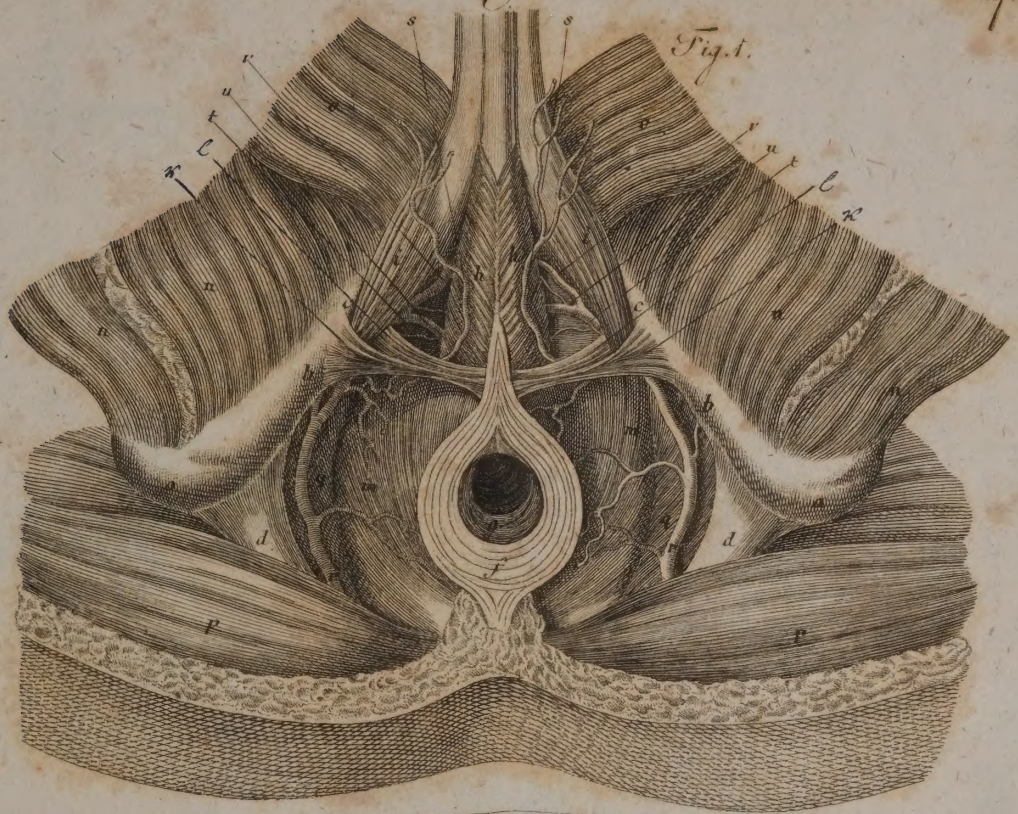

Fig. 2.

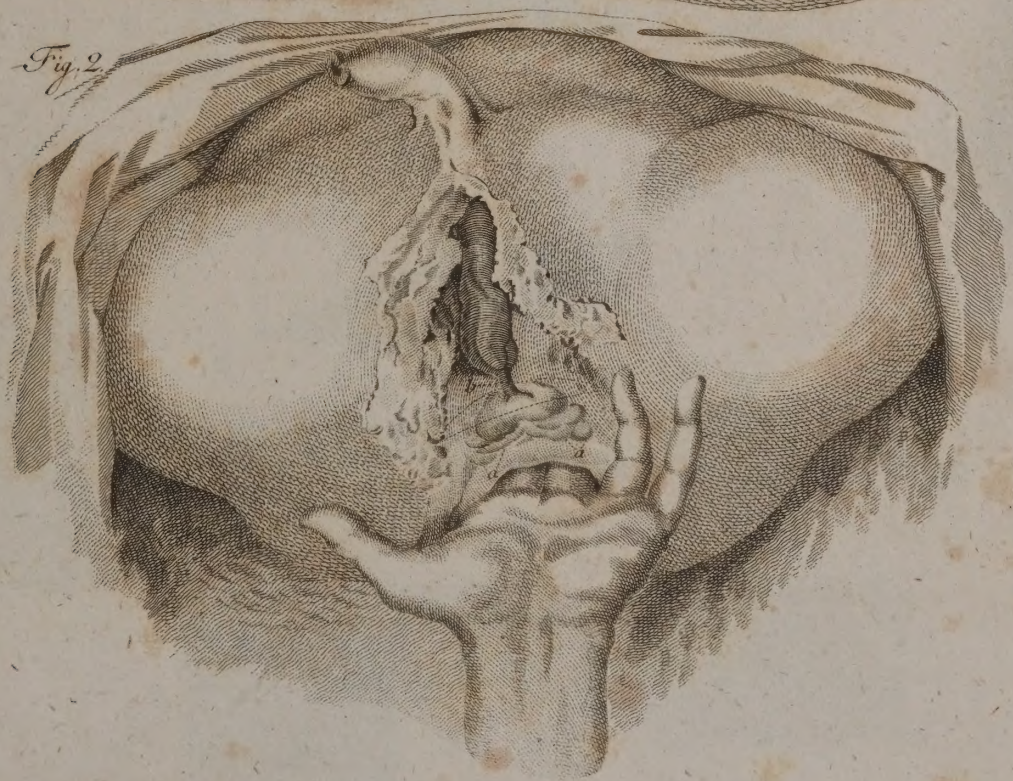

Trepanatio.

D.

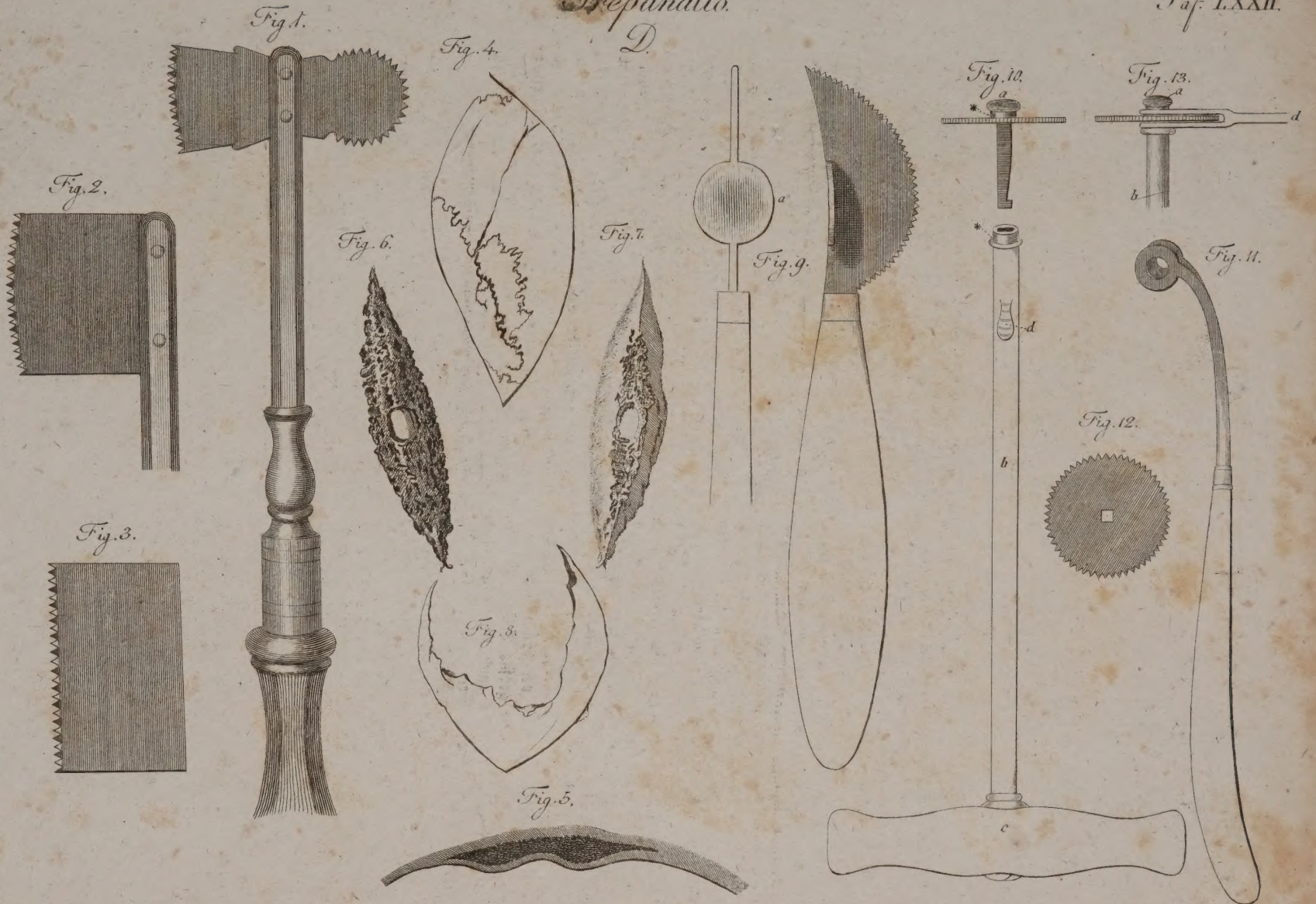

nach Hey, Fahl und Griffith.

Exarticulatio.

Taf. LXXIII.

D

Fig. 1.

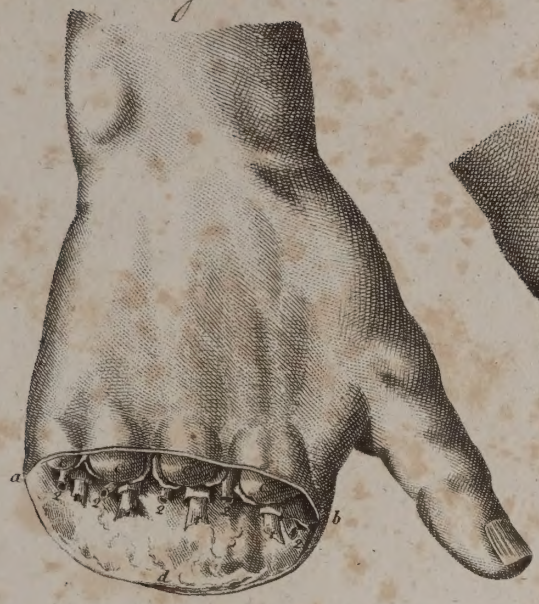

Fig. 2.

Fig. 3.

Fig. 4.

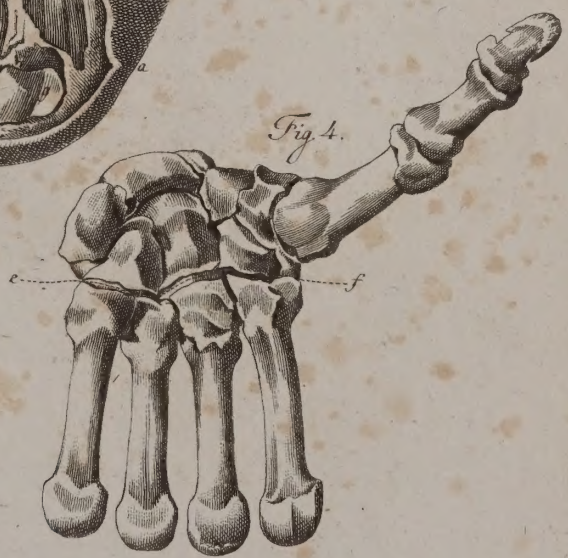

Fig. 5.

Catheterismus

B.

Fig. 1.

Fig. 2.

Fig. 3.

Fig. 4.

Amputatio.
A.

Taf. LXXV.

Fig. 1.

Fig. 3.

Fig. 4.



Fig. 2.

Fig. 1.

Fig. 2.

Fig. 3.

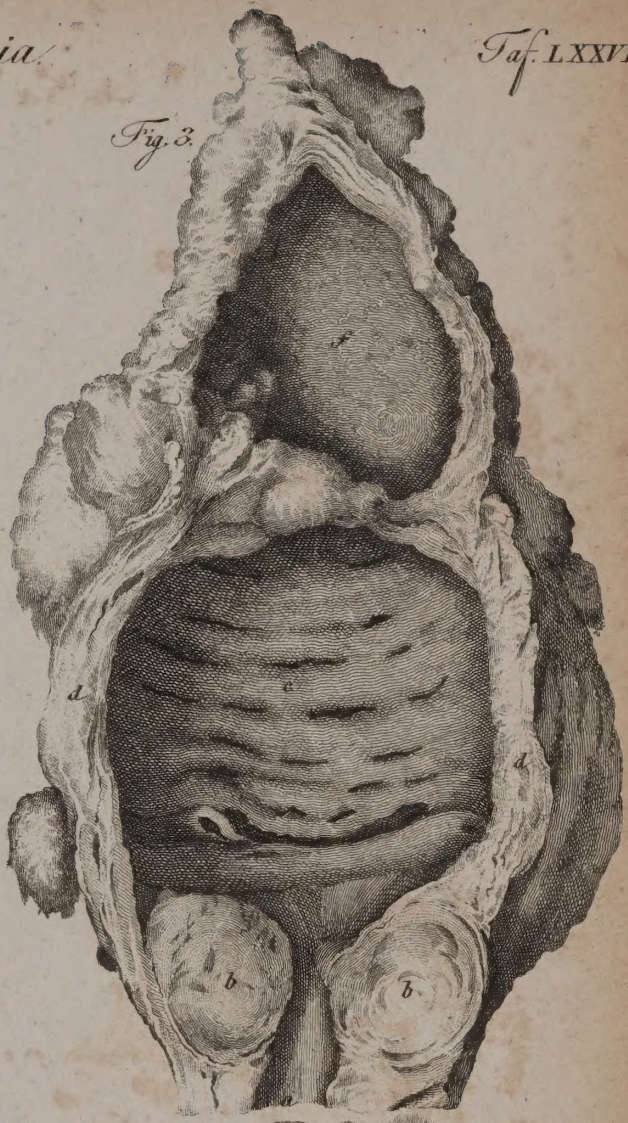

Fig. 4.

Trepanatio.

Taf. LXXVII.

Fig. 1.

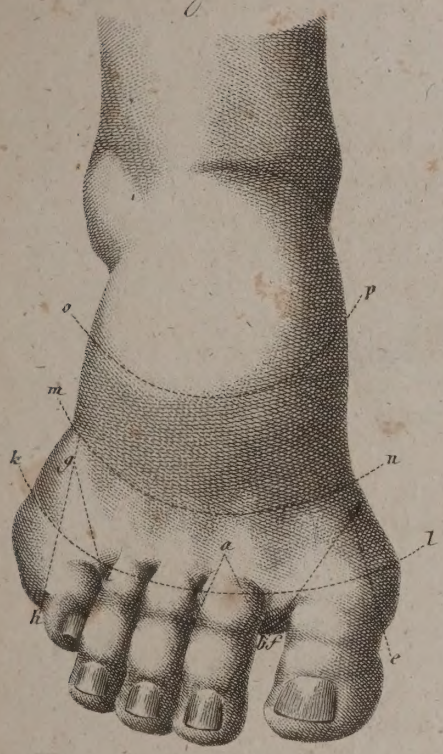

Fig. 2.

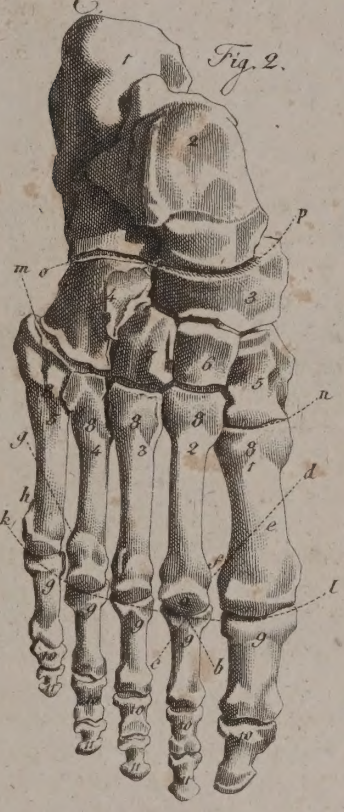

Fig. 3.

Fig. 4.

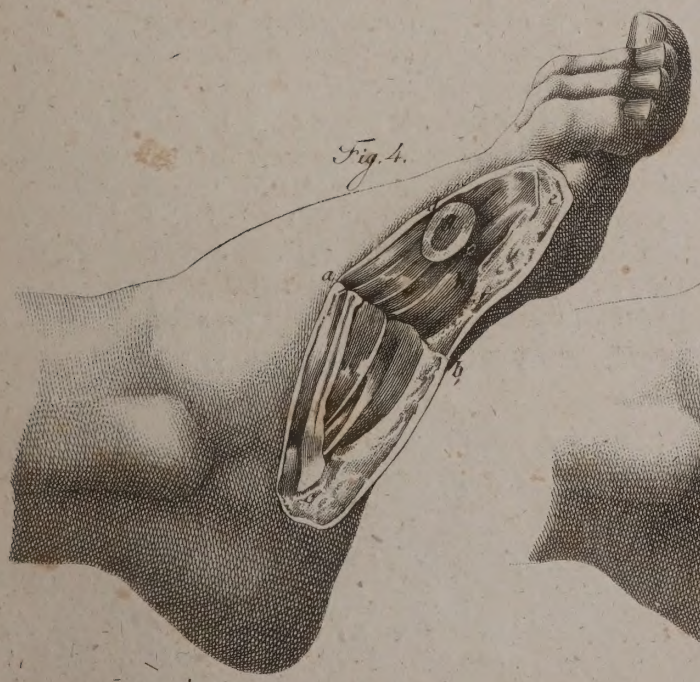

Fig. 5.

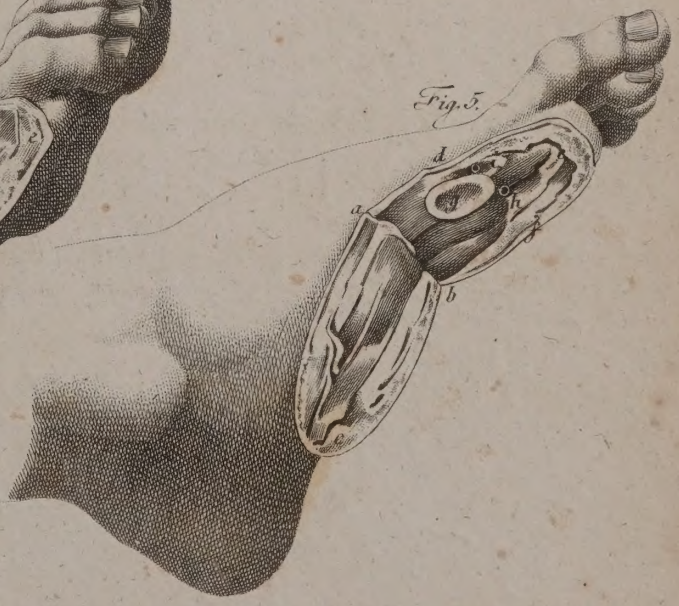

Stricturа Urethrae.

Taf. LXXIX.

C.

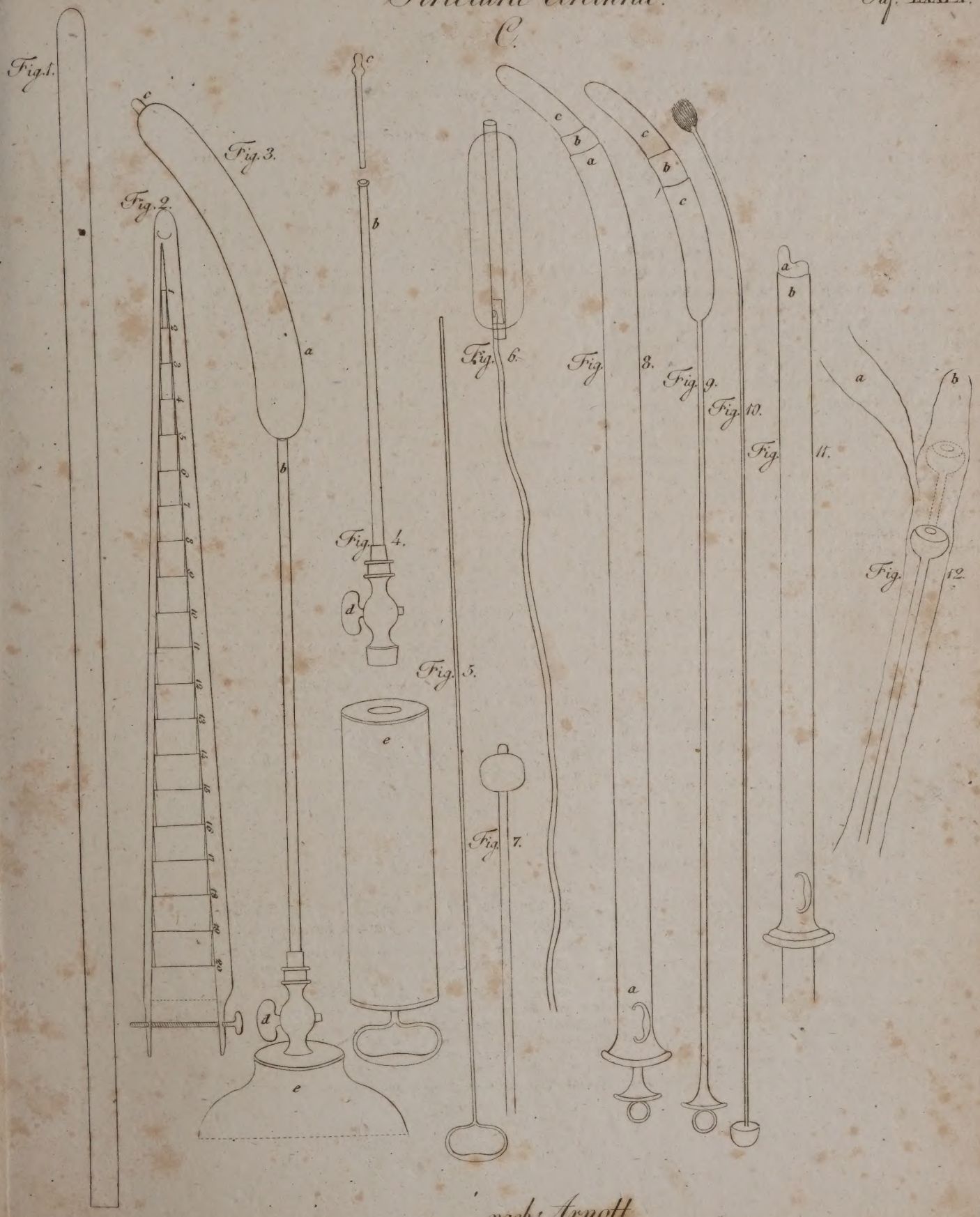

nach Arnott.

Taf. LXXX.

Excarticulatio.

F.

Fig. 1.

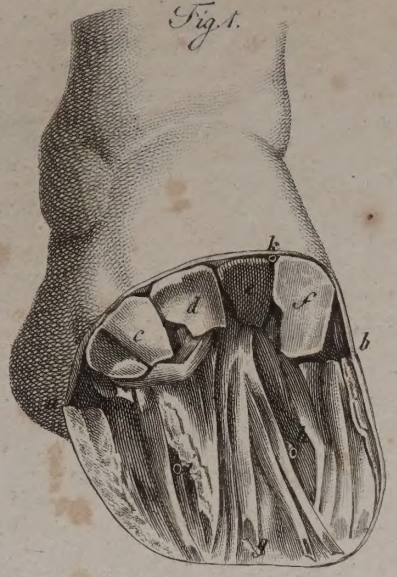

Fig. 5.

Fig. 4.

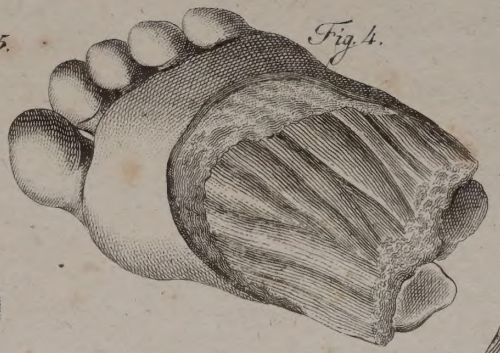

Fig. 3.

Fig. 2.

Fig. 6.

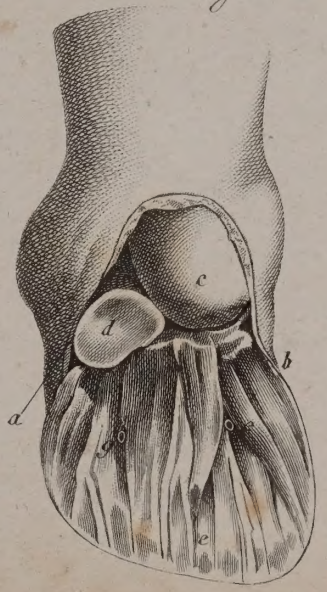

Fig. 7.

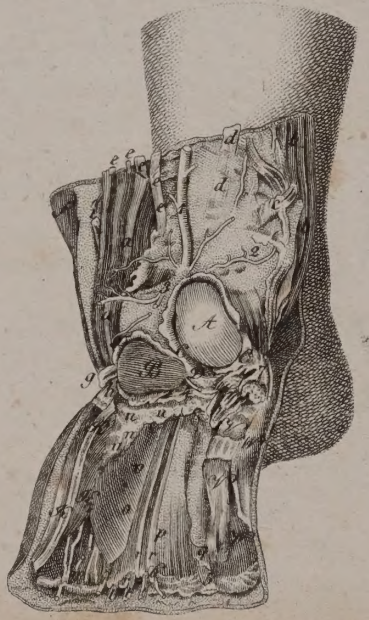

Fig. 8.

Strictura urethrae.

D.



nach Ducamp



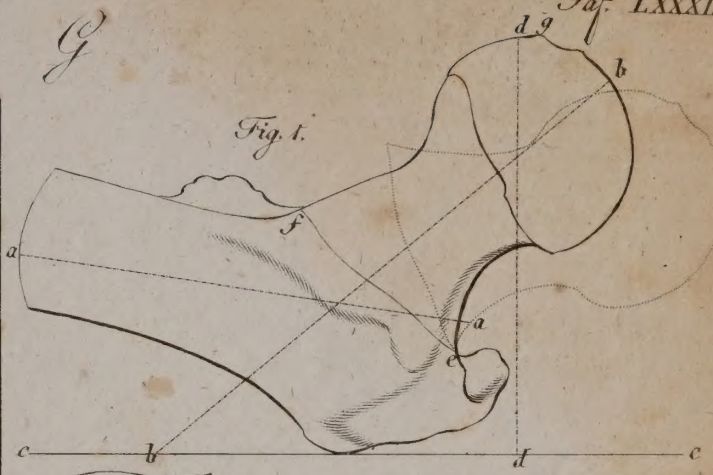

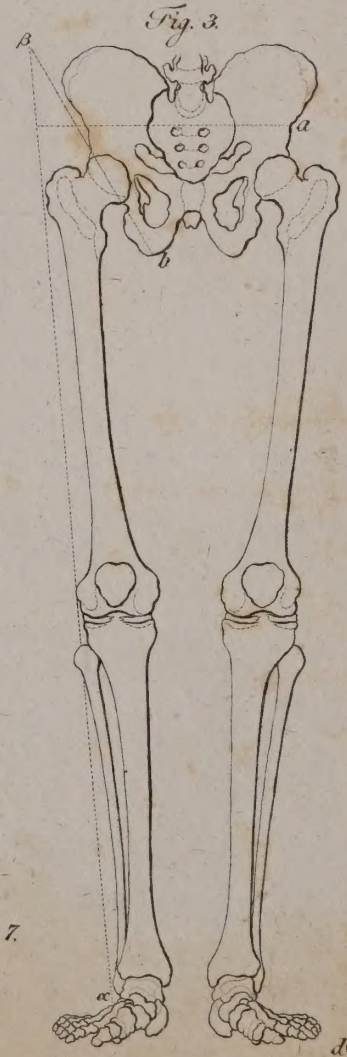



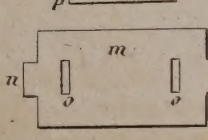



nach van Houte und Volpi.

J. F. Schröter sc.

nach Original Zeichnung.

Fig. 1.

Fig. 2.

Fig. 3.

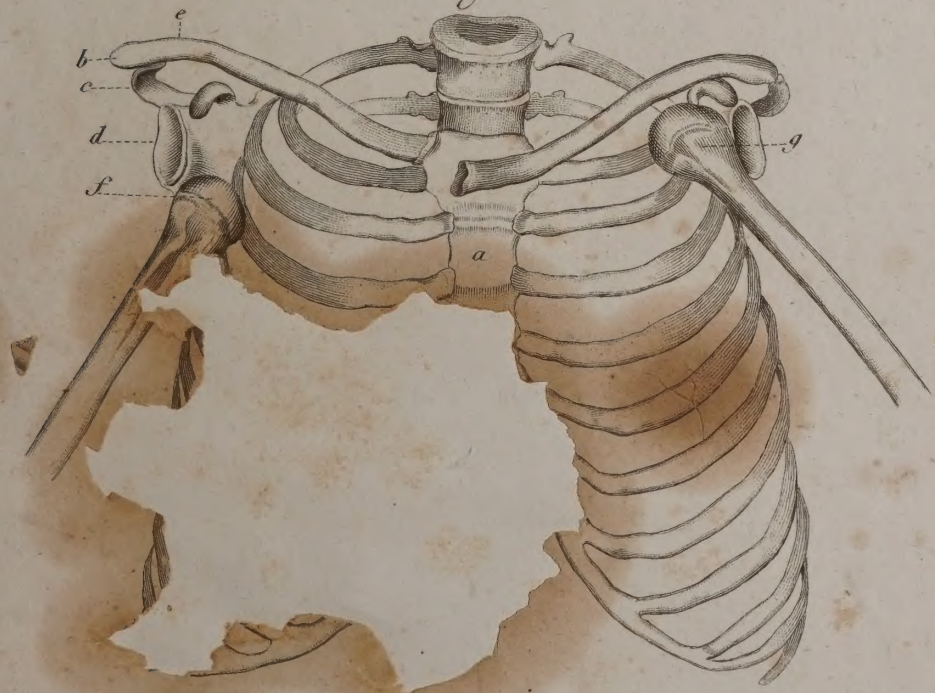

Fig. 4.

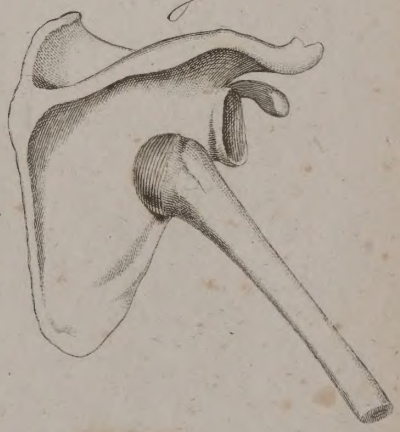

Luxatio F.

Taf: LXXXVII.

Fig: 1.

Fig: 3.

Fig: 2.

Fig: 4.

Fig: 5.

Luxatio.
G.

Taf. LXXXVIII.

Fig. 1.

Fig. 5.

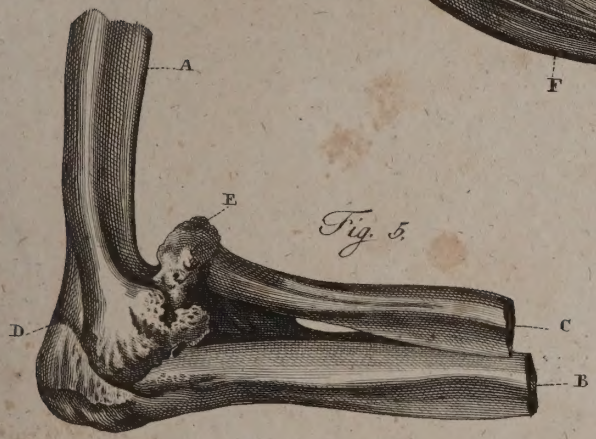

Fig. 2.

Fig. 4.

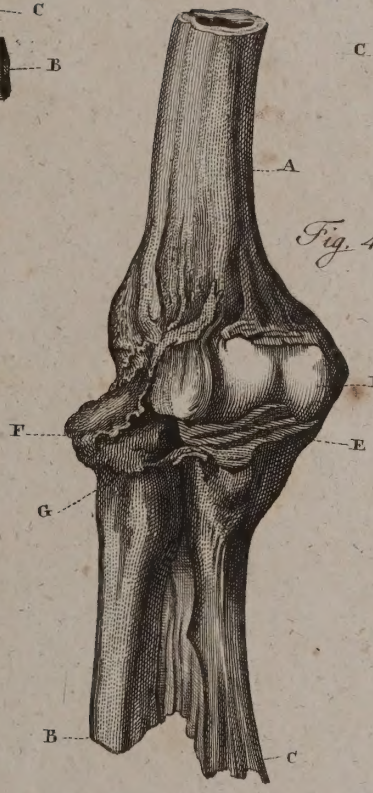

Fig. 3.

Fig. 6.

Th. Goetz sc. 1823.

Hernia.

Taf. LXXIX.

Fig. 5.

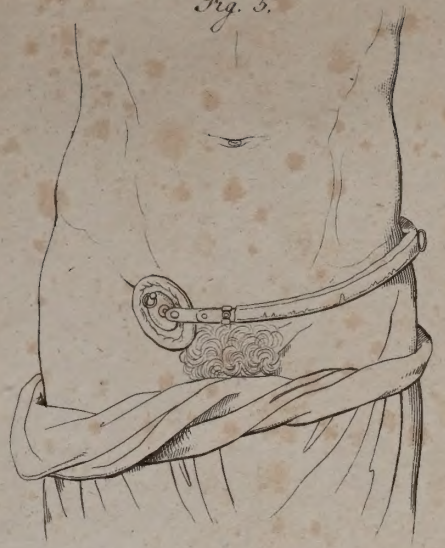

Fig. 6.

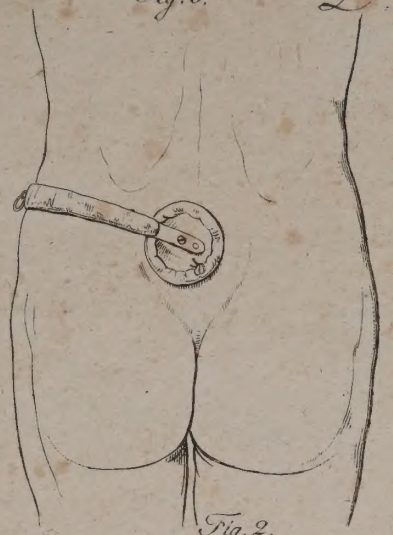

Fig. 7.



Fig. 10.

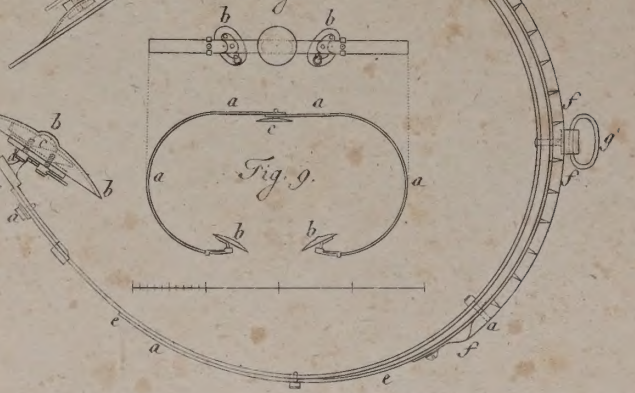

Fig. 8.

Fig. 9.

Fig. 1.

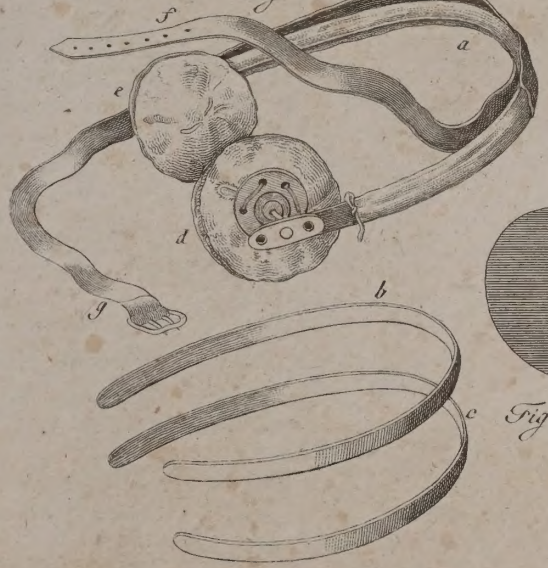

Fig. 2.

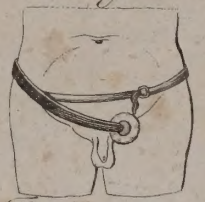

Fig. 4.

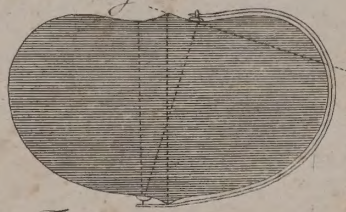

Fig. 3.

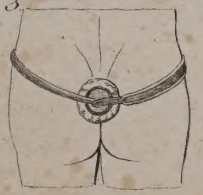

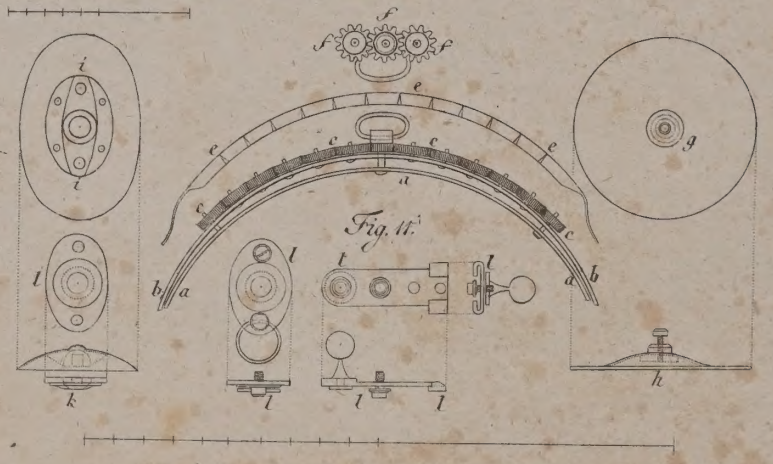

Fig. 1.

Fig. 2.

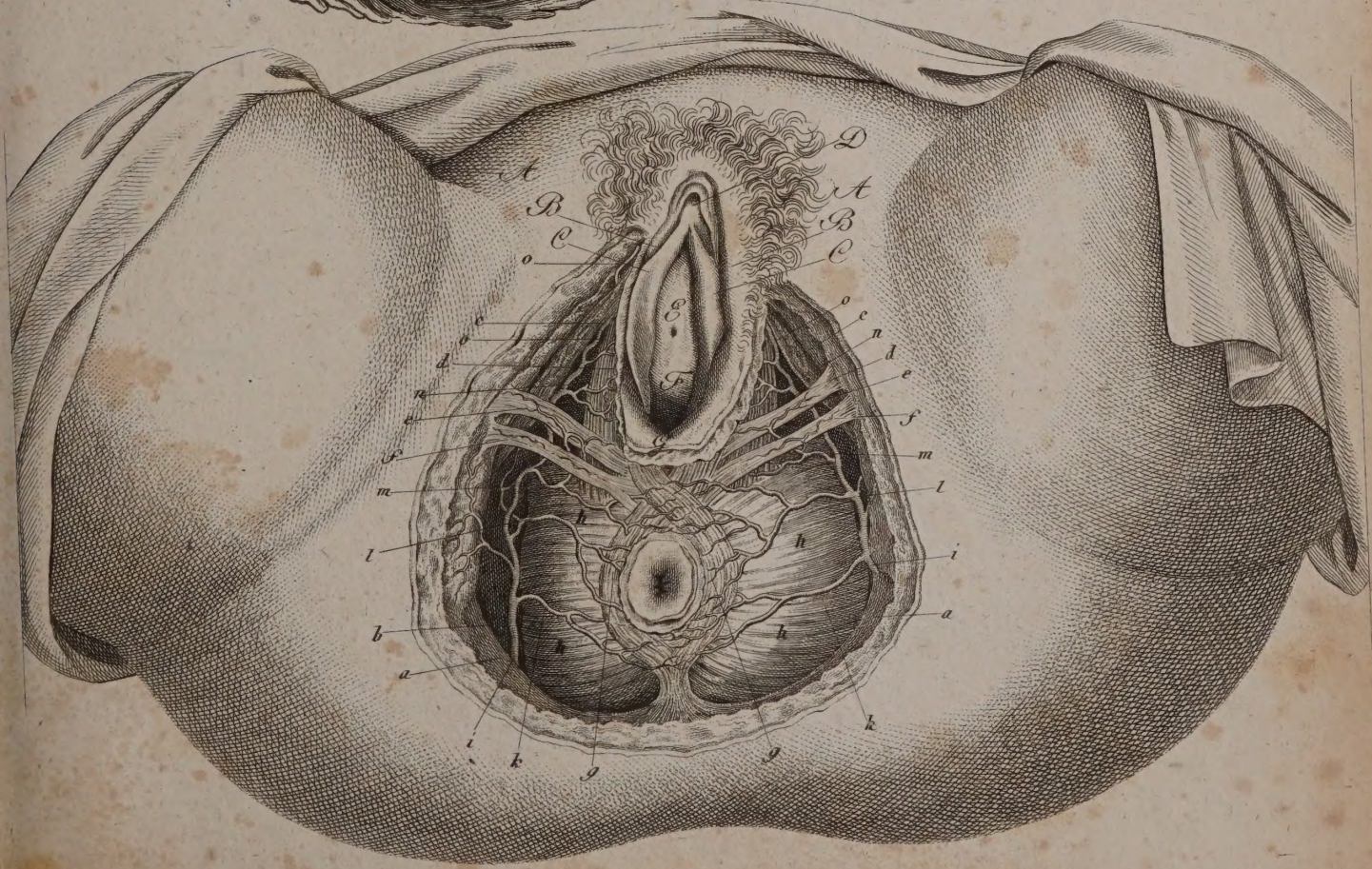

Fig: 1.

Fig: 2.

Fig: 3.

Fractura H.

Fig: 4.

Fig: 1.

Fig: 2.

Fig: 3.

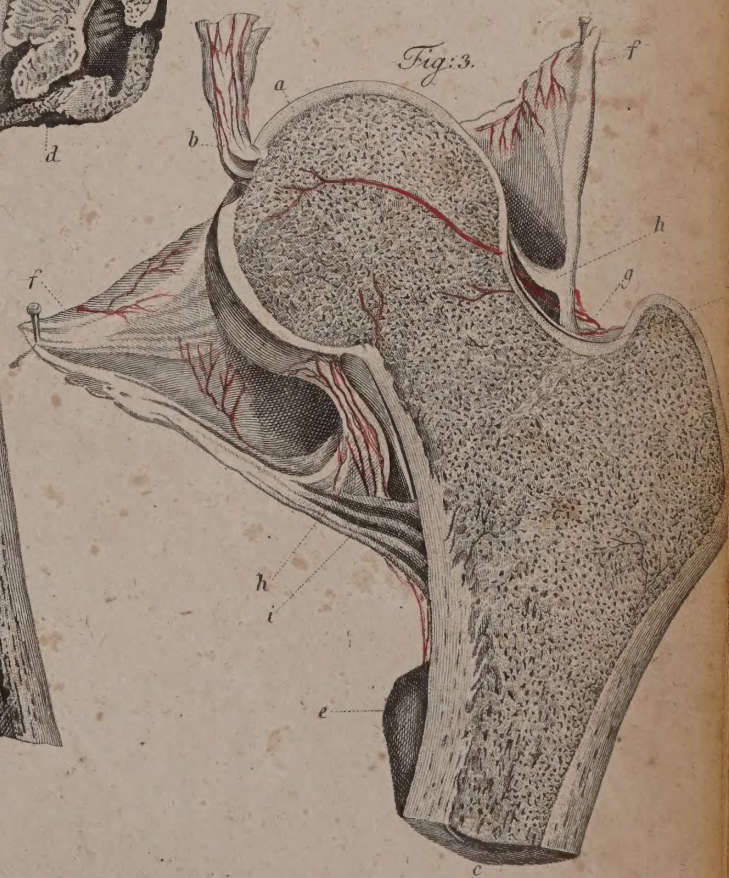

Exarticulatio.

G

Fig. 2.

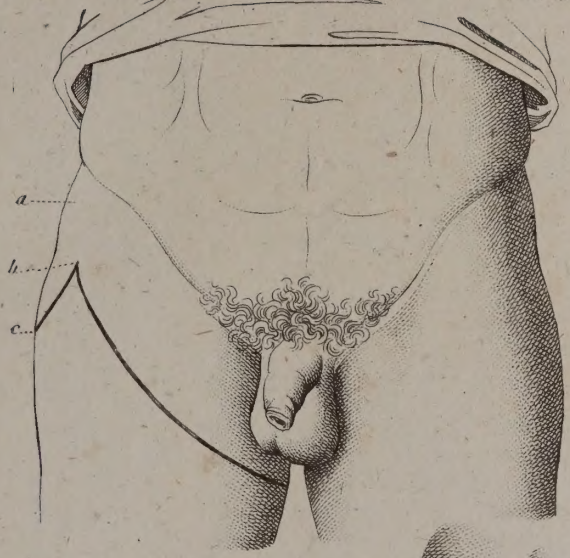

Fig. 4.

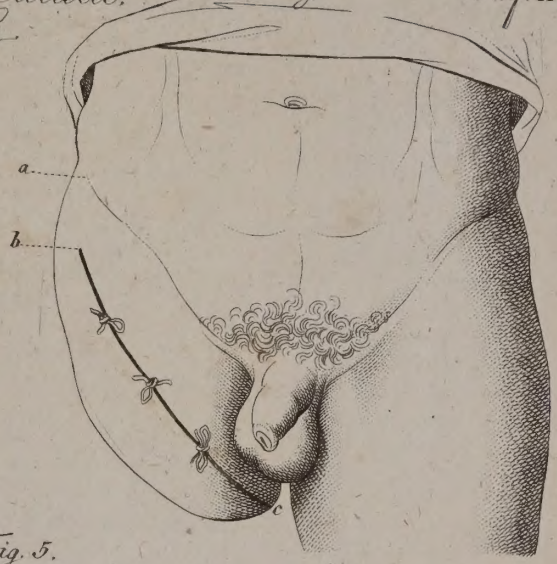

Fig. 5.

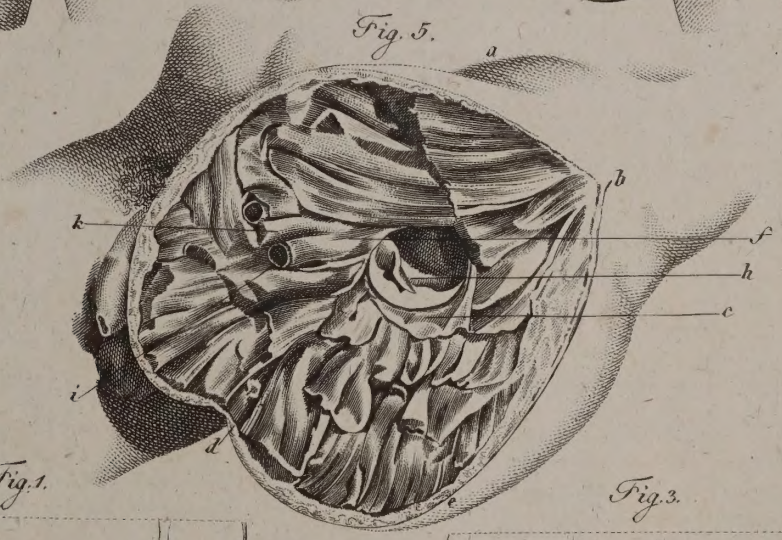

Fig. 1.

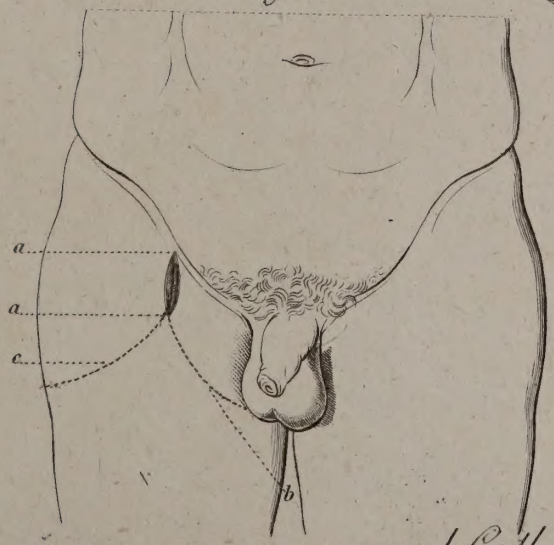

Fig. 3.

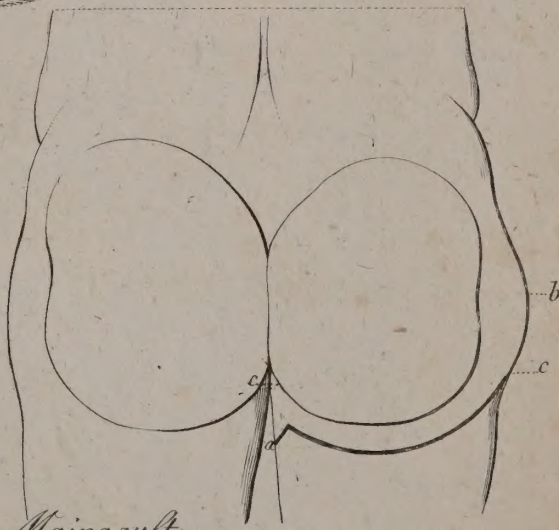

nach Guthrie und Maingault.

Lepra.

Taf. XCIV. XCV.

Fig. 2.

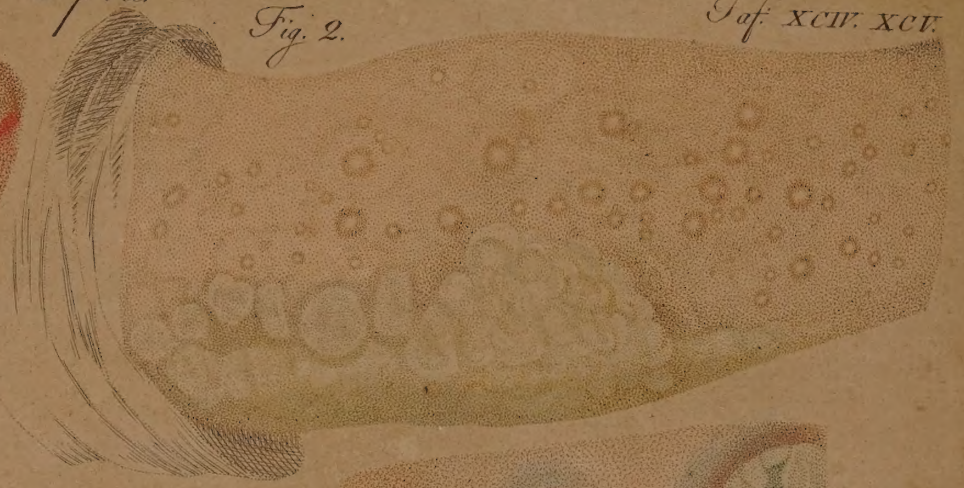

Fig. 1.

Fig. 3.

Luxatio
I.

Fig: 1.

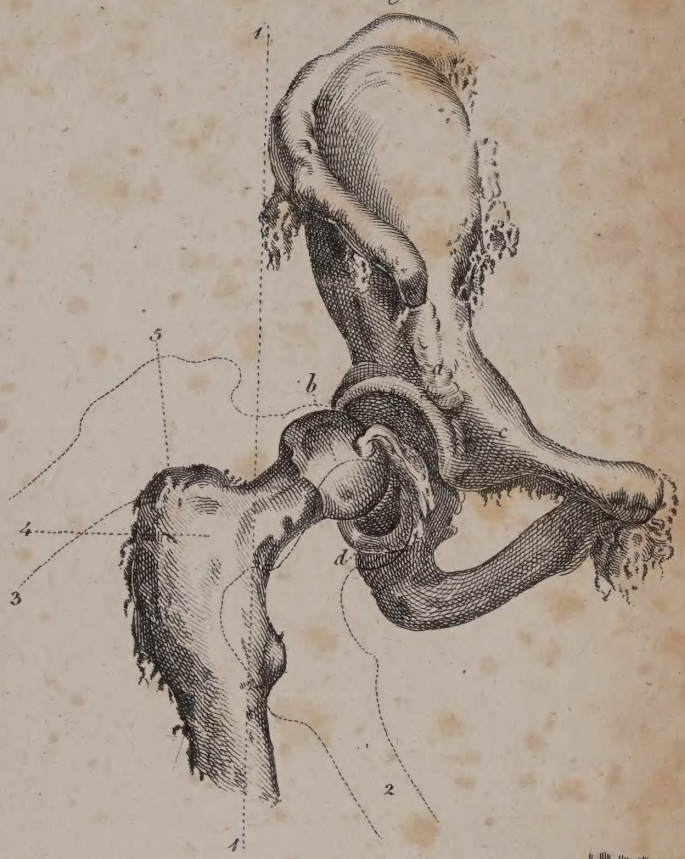

Fig: 2.

Fig: 3.

nach A. Cooper, John Bell u. R. Allan.

Fig. 1.

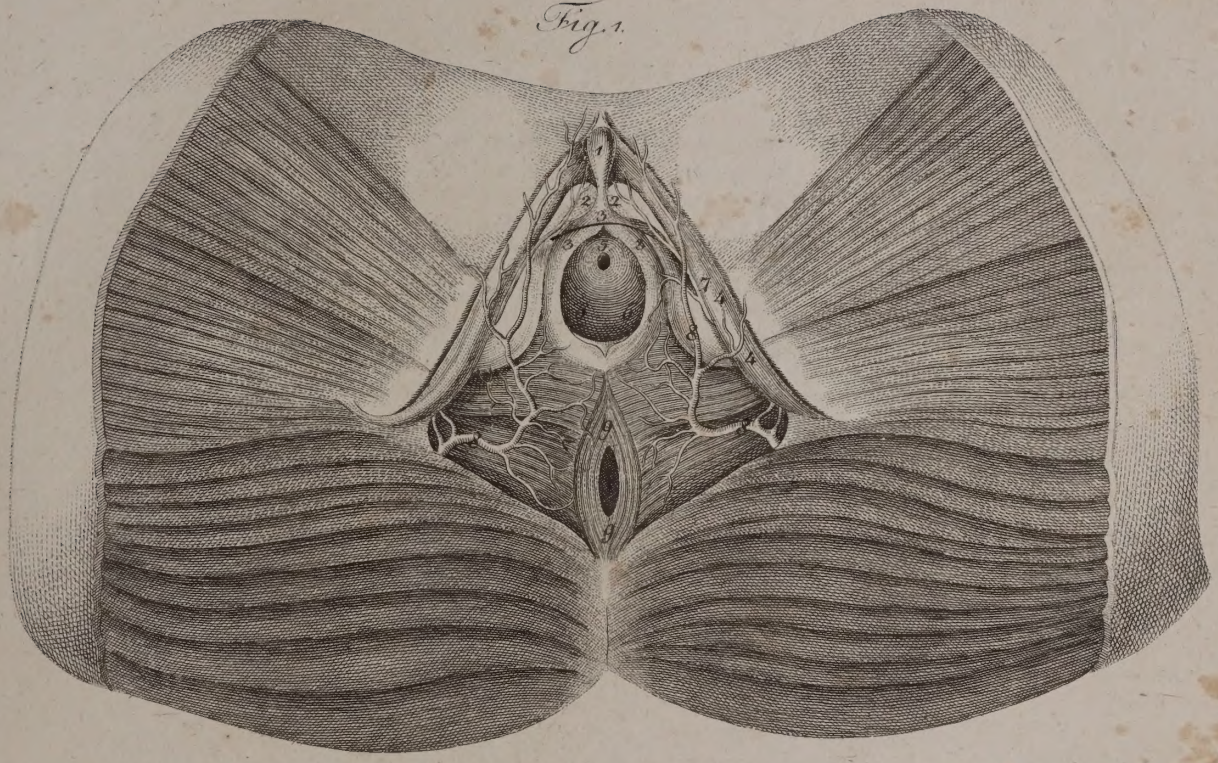

Fig. 2.

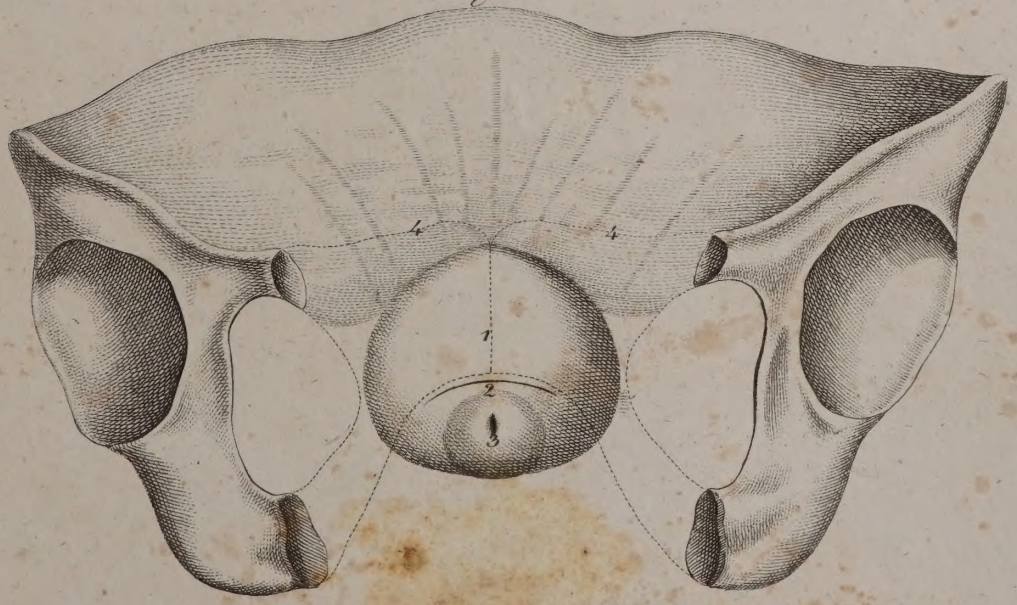

nach Lisfranc.

Scirrhus et Cancer
A.

Fig. 1

Fig. 2

nach Charles Bell

Varus et Valgus

C.

Fig: 2.

Fig: 1.



Fig: 3.



Fig: 4

Fig: 5.



Varus et Valgus

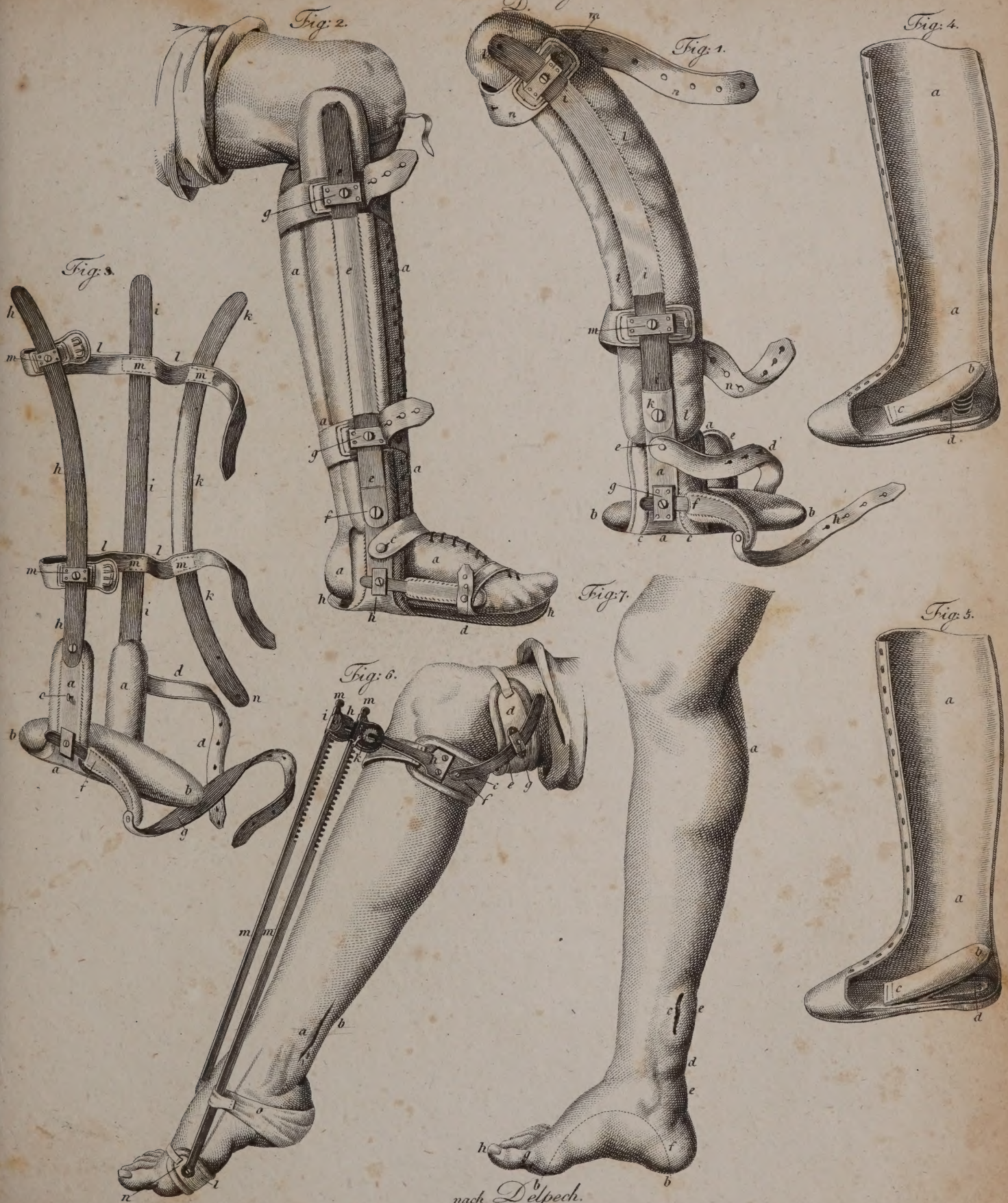

nach Delpech.

Aneurysma.

Fig: 1.

D.

Fig: 2.

Fig: 3.

nach Ch: Bell.

Hydrocele.

C.

Fig. 1.

Fig. 2.

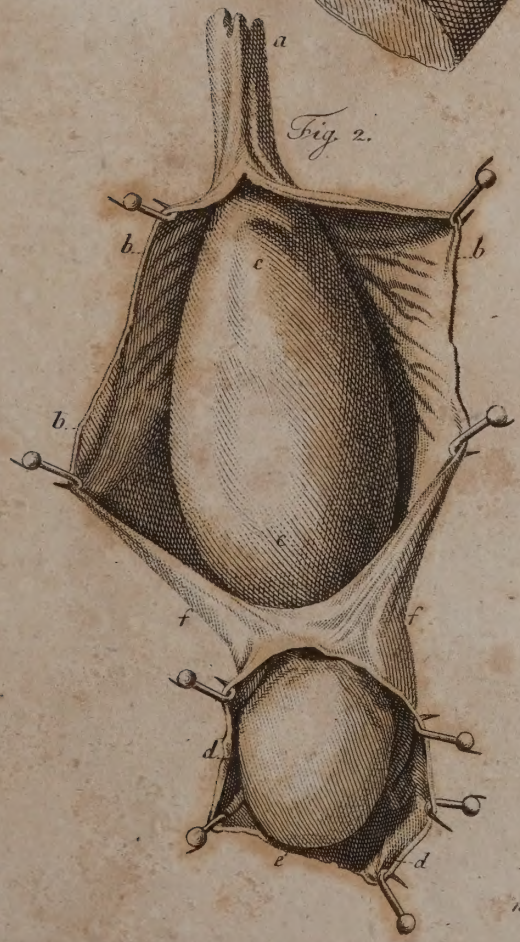

Fig. 3.

nach Scarpa.

Hydrocele
D.

Taf: CIII.

Fig: 1.

Fig: 2.

Fig: 3.

Fig: 4.

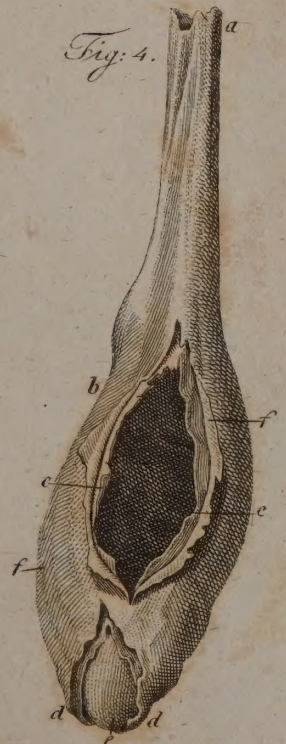

Fig: 5.

Fig: 6.

nach Scarpa.

Lithotomia
G.

Fig. 1.

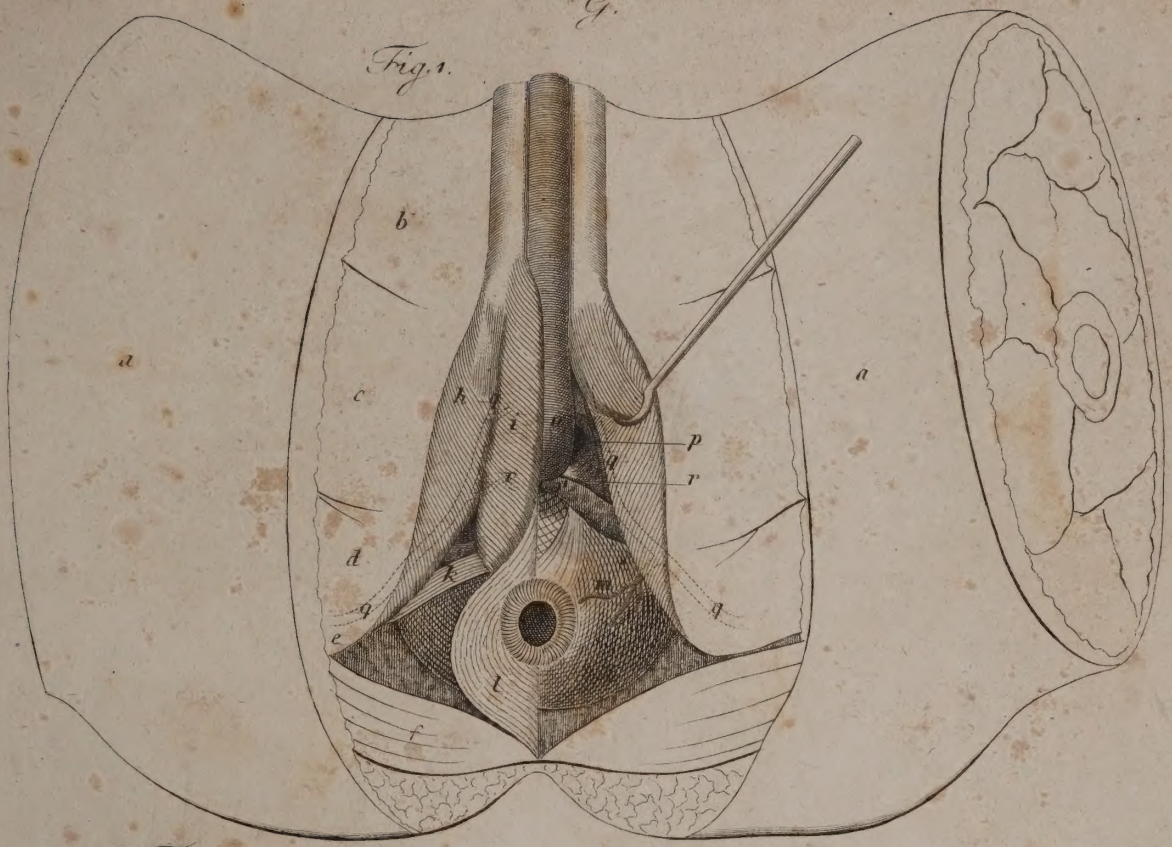

Fig. 2.

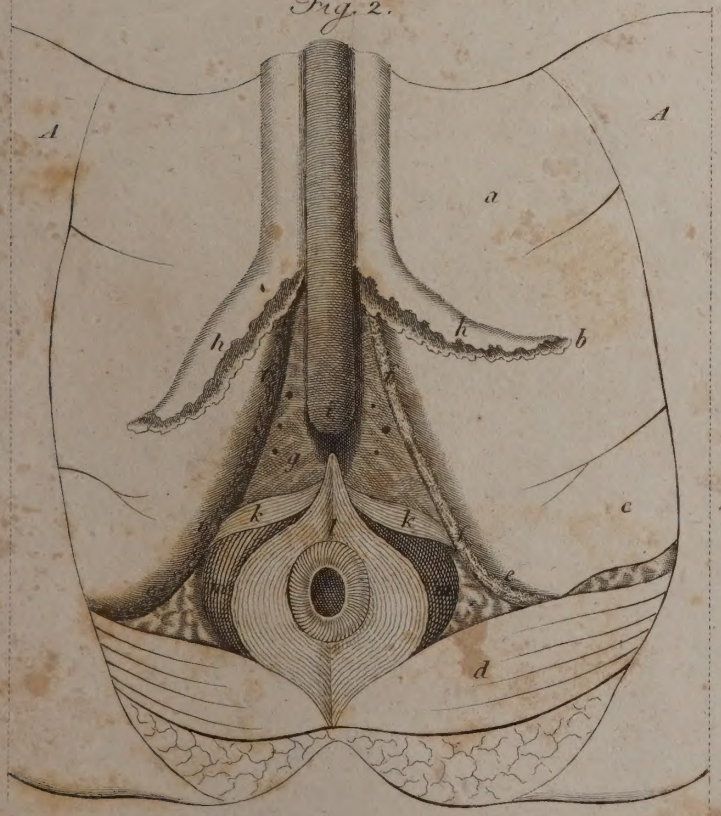

Fig. 3.

nach Carcassonne

Polypus A.

Taf. CV.

Fig. 3.

Fig. 1.

Fig: 4.

Fig. 2.

nach John Bell.

Lithotomia H.

Fig: 3.

Fig: 1.

Fig: 4.

Fig: 2.

nach Green und Scarpa.

Exarticulatio. H.

Fig: 1.

Fig: 2.

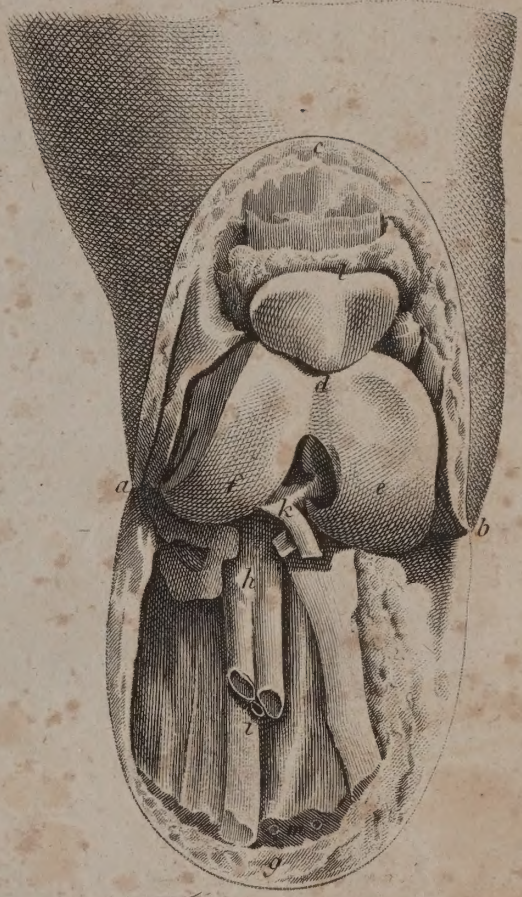

Fig: 3.

Fig: 4.

nach Maingault und Textor

Taf CVIII.

Polypus B.

Fig: 1.

Fig: 2.

nach Alibert.

Fungus medullaris oculi.

Taf: CVIII–XI.

Nro: 1.

Nro: 2.

Nro: 3.

Fig: 6.

Fig: 8.

Fig: 10.

Fig: 7.

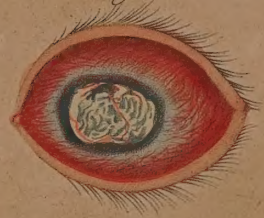

Fig: 9.

Fig: 4.

Fig: 5.

1.2.3. nach Original Zeichnungen. 4–10 nach Travers. H. Hessen. sc. Vimaria.

Ligatura vasorum B.

Fig: 1.

Fig: 2.

Fig: 3.

Fig: 4.

Fig: 5.

Fig: 7.

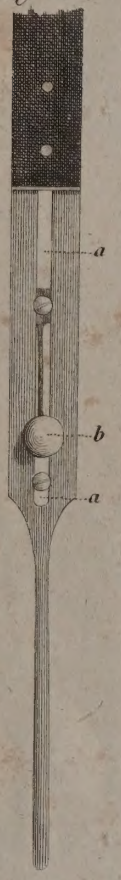

Fig: 8.

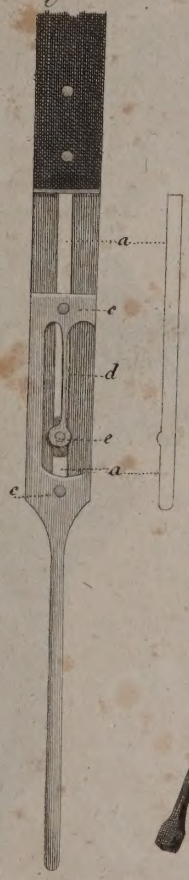

Fig: 6.

Fig: 9.

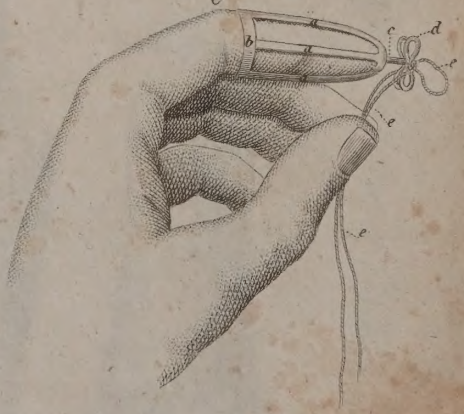

Fig: 1 2 3 4 nach Ch. Bell. Fig: 5–9 nach Originalen.

Amputatio C.

Fig: 1.
d'Alton jun: del:

Fig: 4.

Fig: 5.



Fig: 7.

Fig: 6.

Fig: 8.

Fig: 2.

Fig: 3.

Fig: 1. nach Original Zeichnung Fig: 2–8 nach van Hoorn

Polypus

C

Fig: 1.

Fig: 2.

Fig: 3.

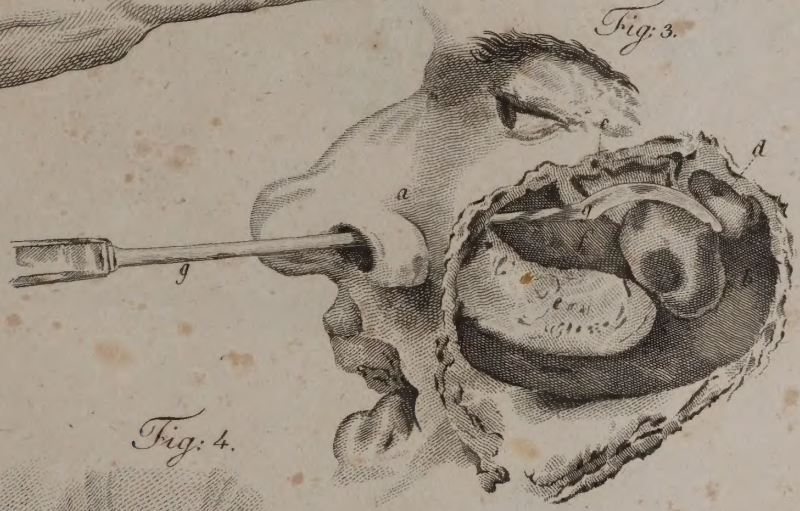

Fig: 4.

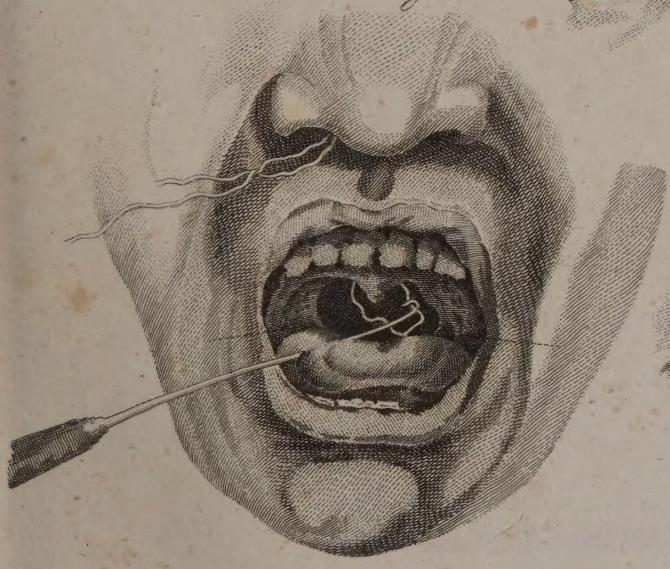

Fig: 5.

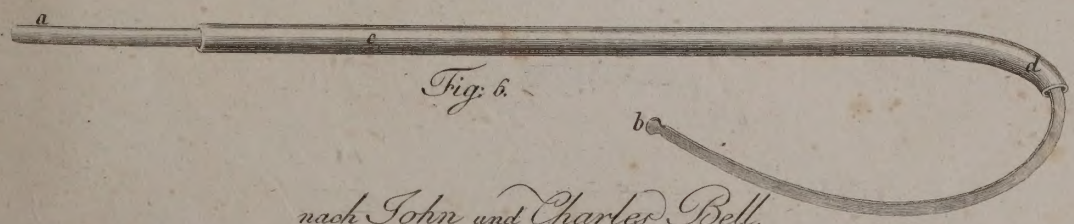

Fig: 6.

nach John und Charles Bell.

Pompholyx.

Fig. 1.

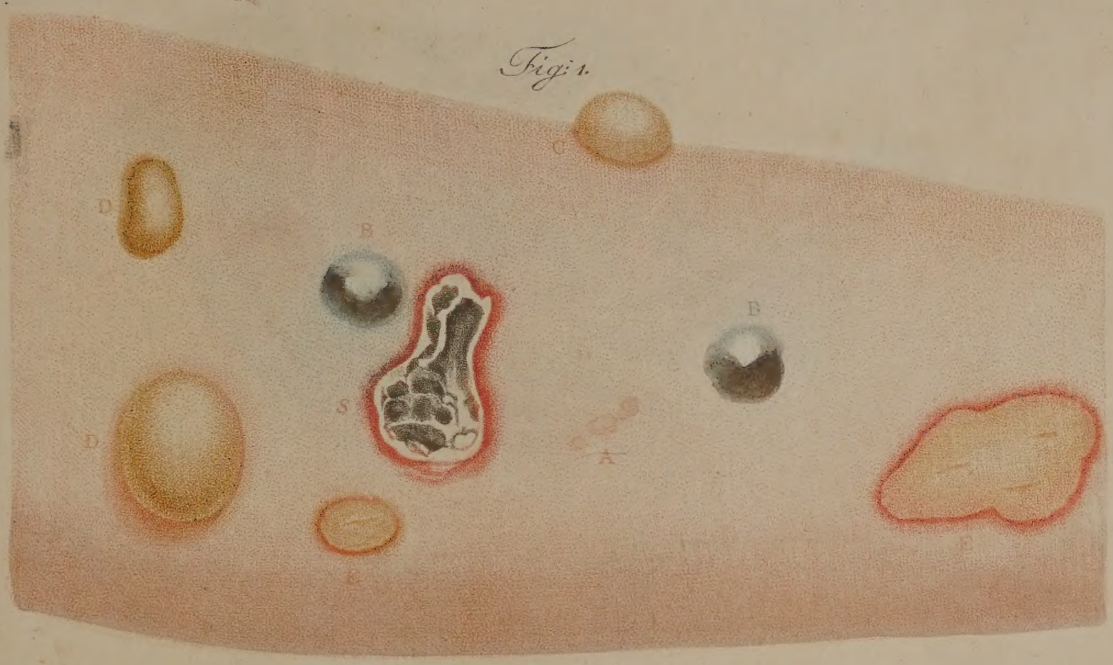

Fig. 2.

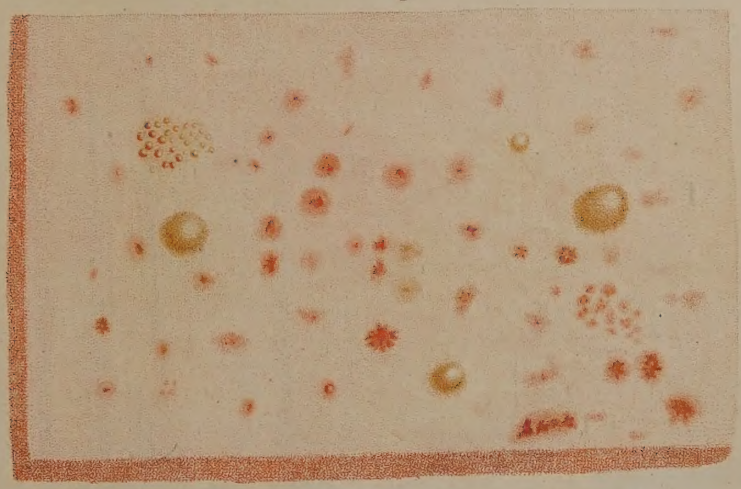

nach Bateman.

Lithotomia
I.

Fig. 1.

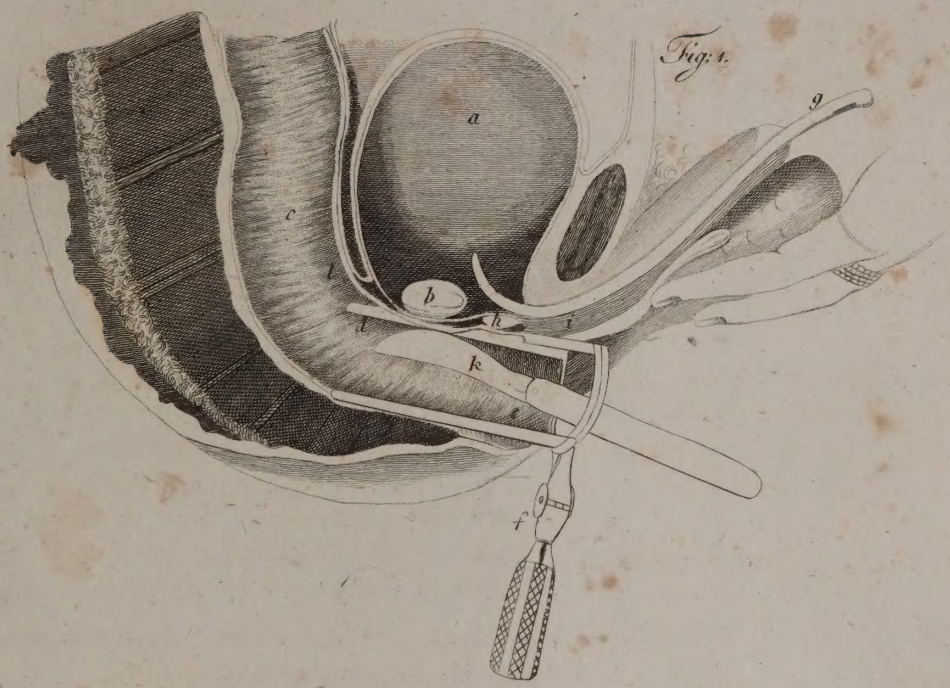

Fig. 2.

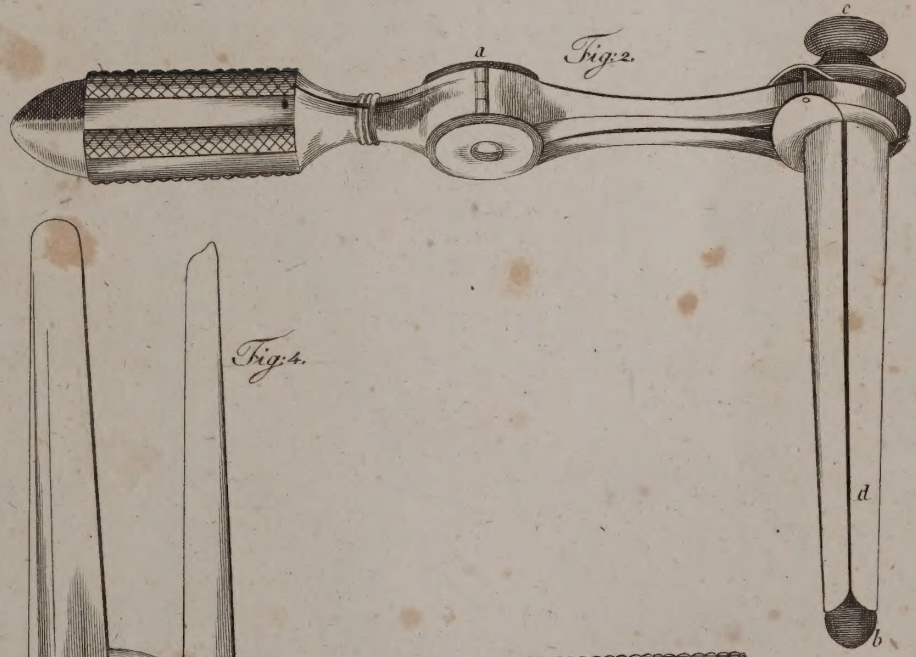

Fig. 3.

Fig. 4.

nach Sleigh.

Fracturen I.

Fig: 1.

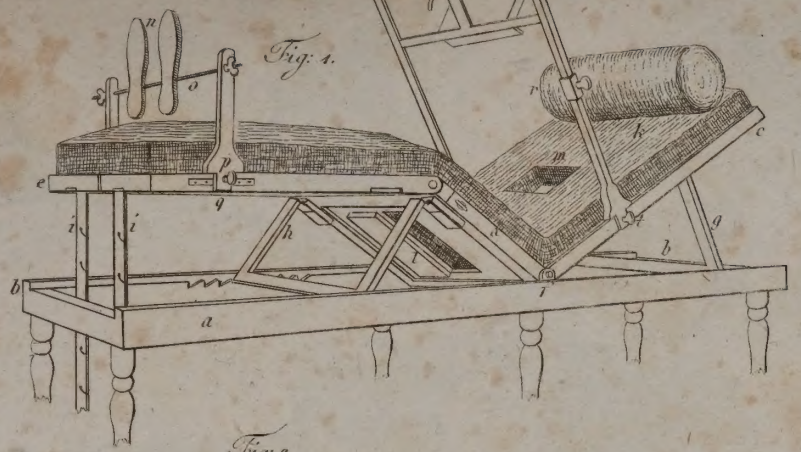

Fig: 2.

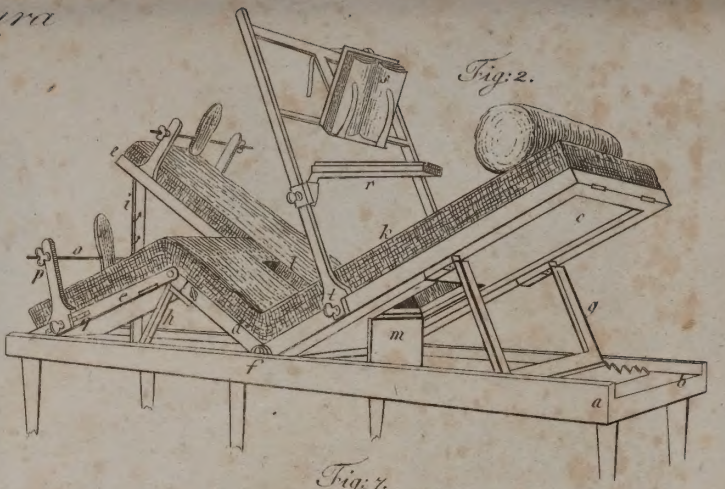

Fig: 3.

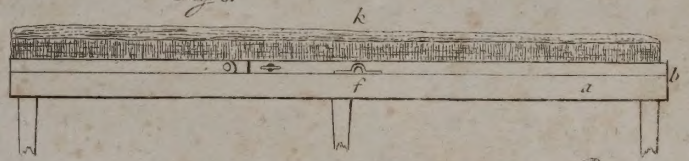

Fig: 8.

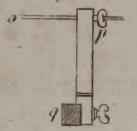

Fig: 7.

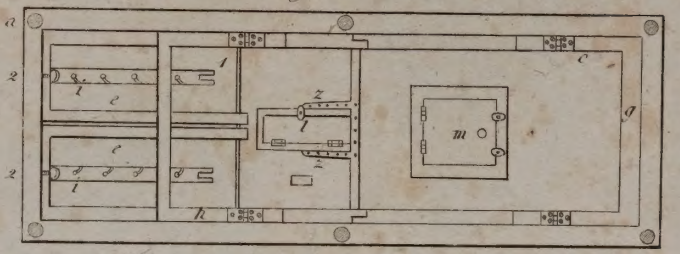

Fig: 5.

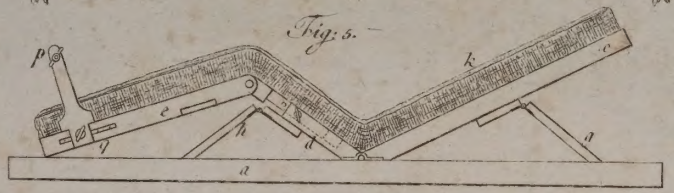

Fig: 9.

Fig: 6.

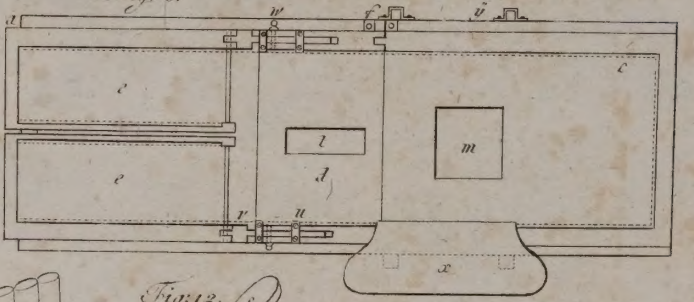

Fig 4.

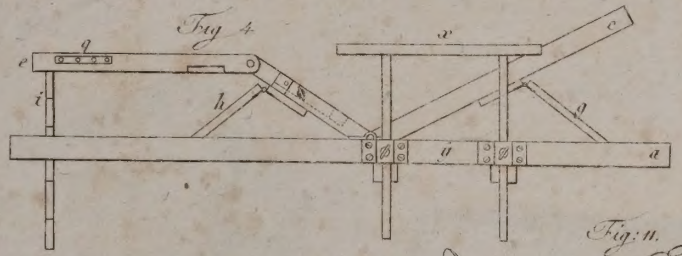

Fig: 10.



Fig: 12.

Fig: 11.

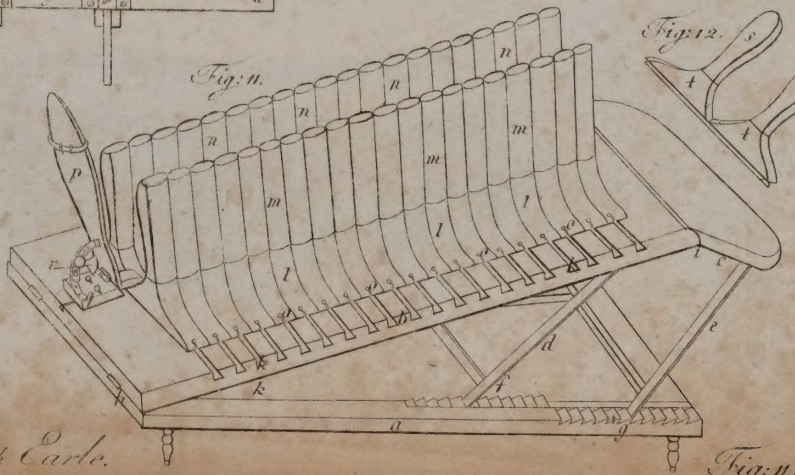

Fig: 1. 10 nach Earle.

Fig: 11 u. 12 nach Elderton.

Fractura K.

Fig: 1.

Fig: 2.

Fig: 3.

Fig: 4.

Fig: 5.

nach A. Cooper, und Charl. Bell.

Ophthalmo-Blennorhoea

Fig: 5.

Fig: 3.

Fig: 1.

Fig: 6.

Fig: 4.

Fig: 2.

nach Graefe und Vetch.

Lithotomia.

K.

Fig. 4.

Fig. 3.

Fig. 5.

Fig. 4.**

Fig. 1.

Fig. 2.



Distorsio Spinae.

Taf. CXXIII.

A.

Fig. 1.

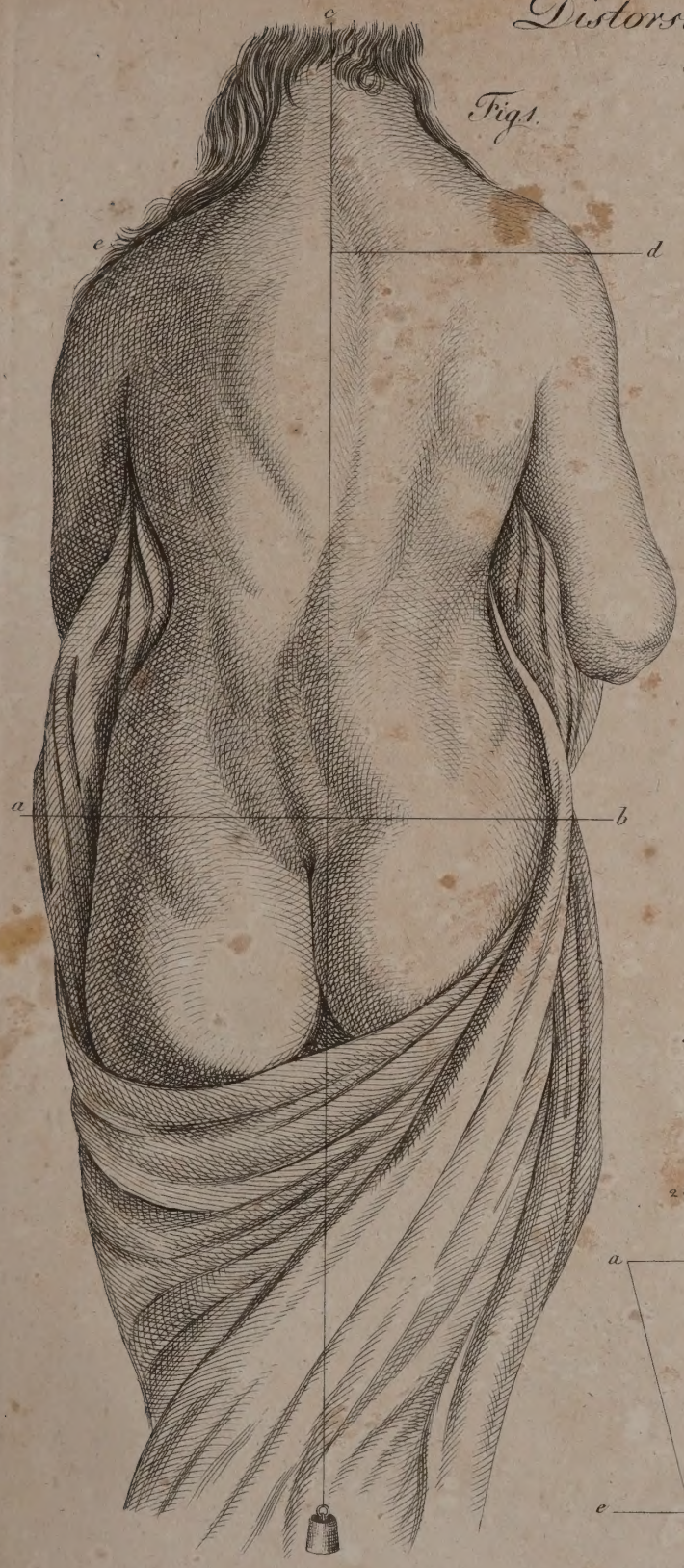

Fig. 2.

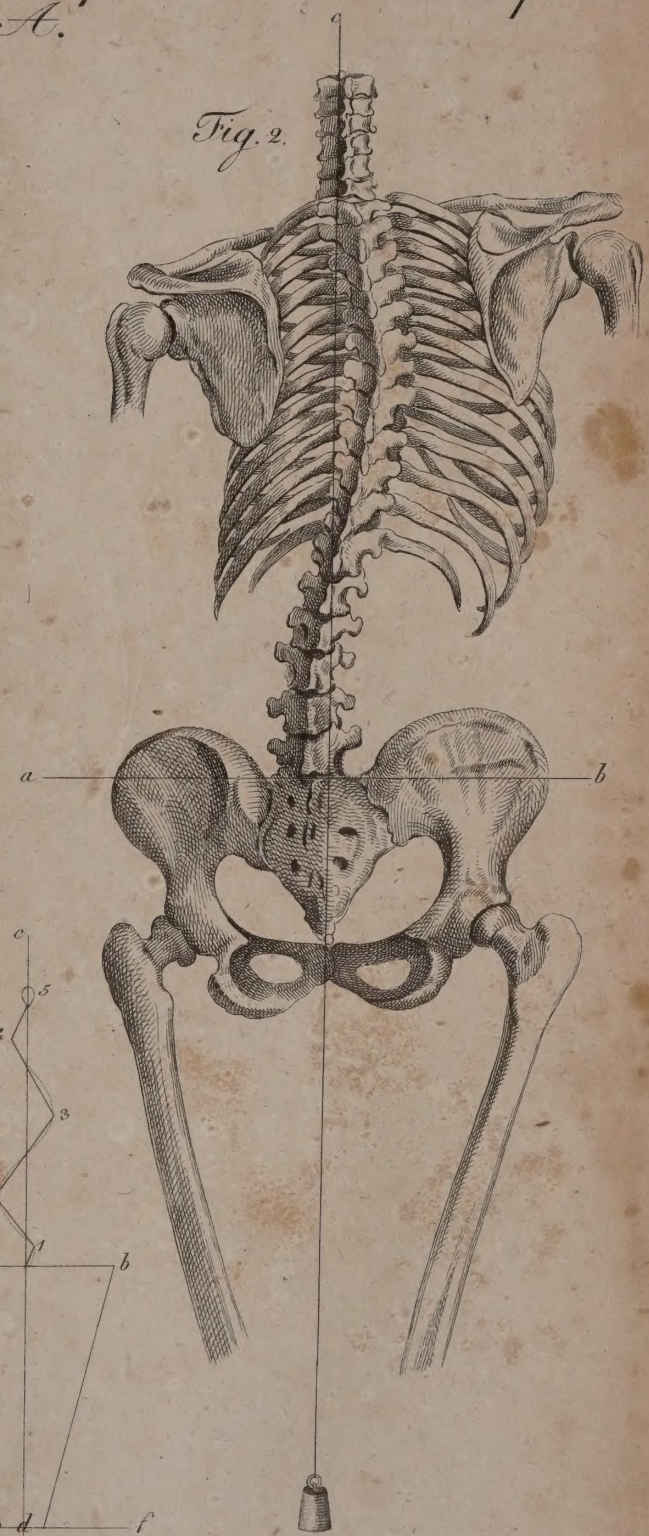

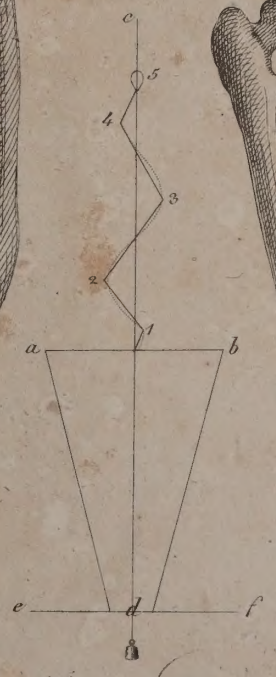

nach John Shaw.

Distorsio Spinae.

Taf. CXXIV.

B.

Fig. 1.

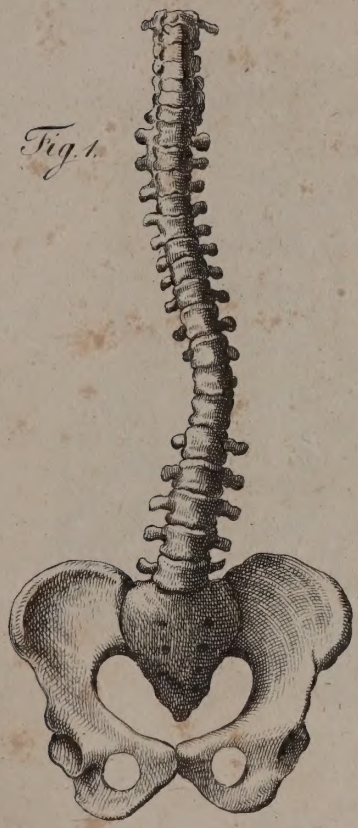

Fig. 2.

Fig. 3.

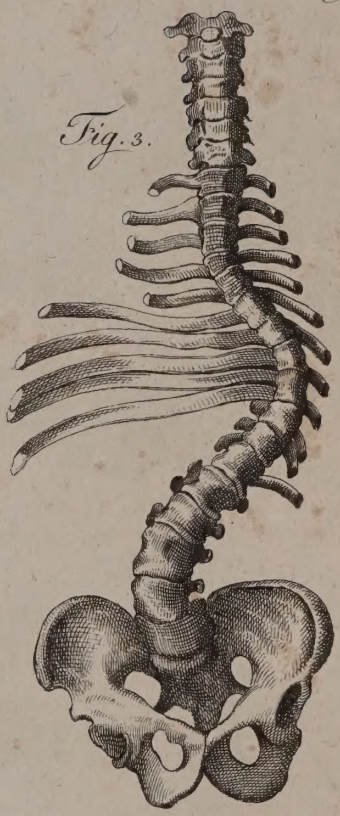

Fig. 5.

Fig. 4.

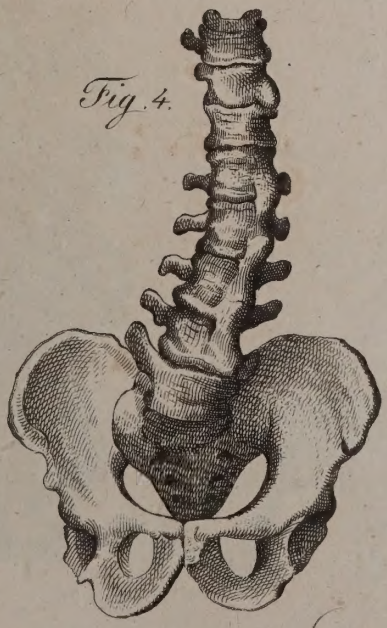

Fig. 6.

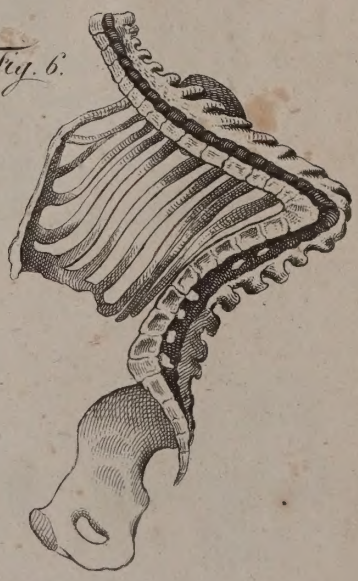

nach John Shaw.

Fractura.

Taf. CXXV.

Fig. 1.

Fig. 2.

Fig. 3.

Fig. 4.

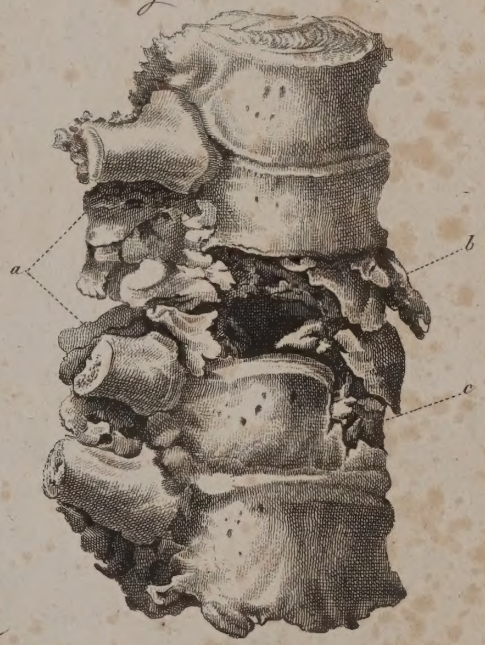

Fig. 5.

Fig. 6.

nach Charles Bell.

Tab. CXXVI.

Sarcocele.

Fig. 1.

Fig. 2.

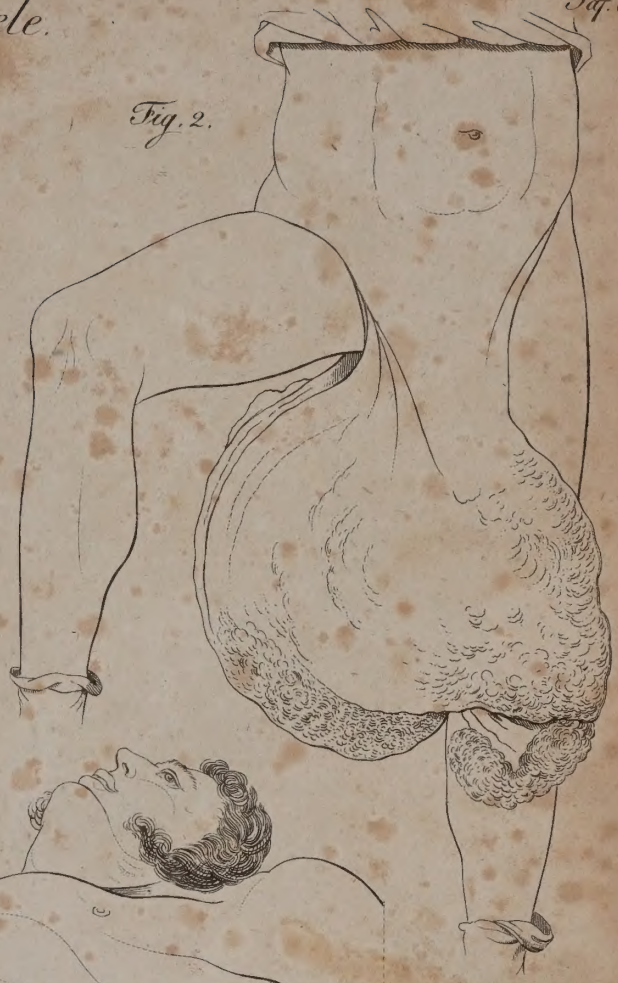

Fig. 3.

Fig. 4.

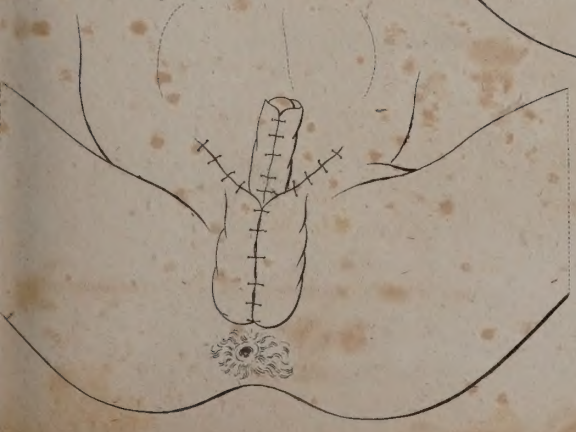

Fig. 5.

Fig. 2.

Fig. 1.

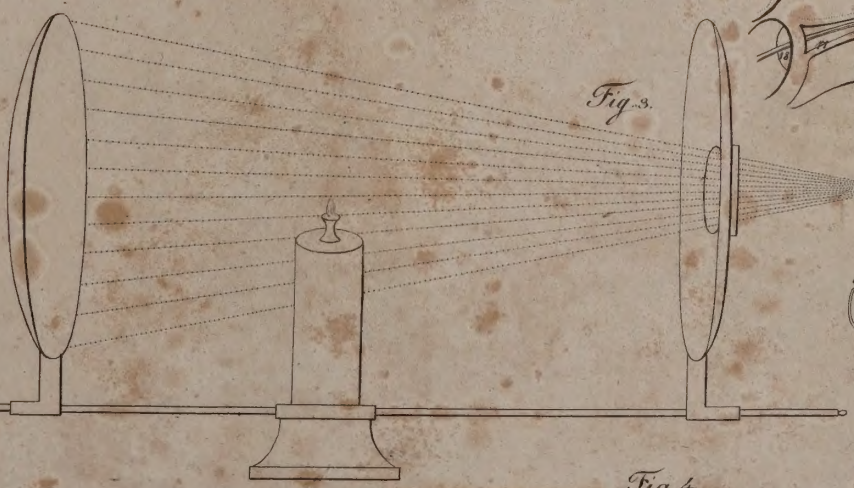

Fig. 3.



Fig. 7.



Fig. 8.

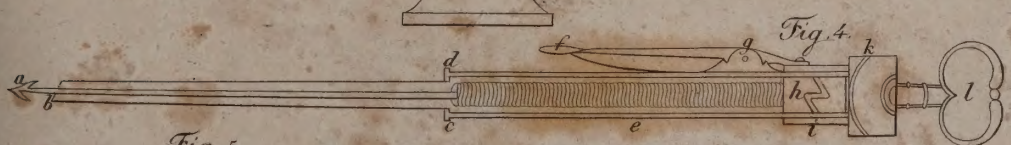

Fig. 4.

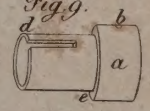

Fig. 9.

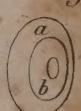

Fig. 11.



Fig. 5.

Fig. 6.



Fig. 10.

Fig. 12.

Fig. 1 nach Buchanan. Fig. 2. 3. nach Deleau.

Distorsio Spinae.

Taf. CXXVIII.

C.

Fig. 1.

Fig. 4.

Fig. 2.

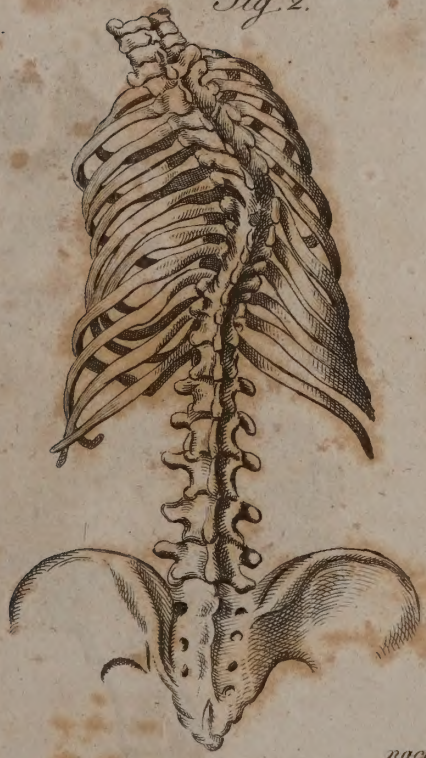

Fig. 3.

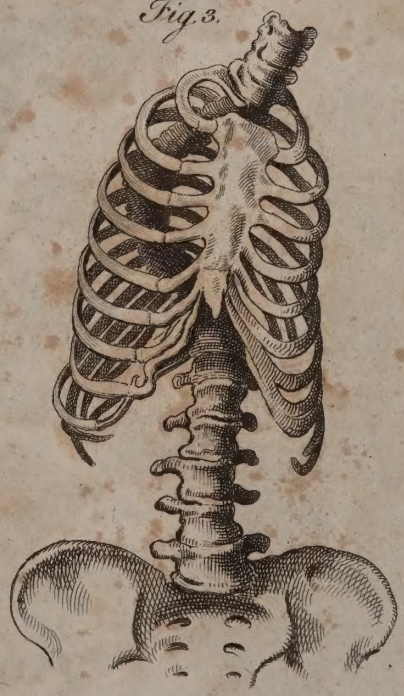

nach John Shaw.

Luxatio.

K.

Fig. 1.

Fig. 2.

Fig. 3

Fig. 4.

Fig. 5.

nach Charles Bell

Fig. 1.

Fig. 2.

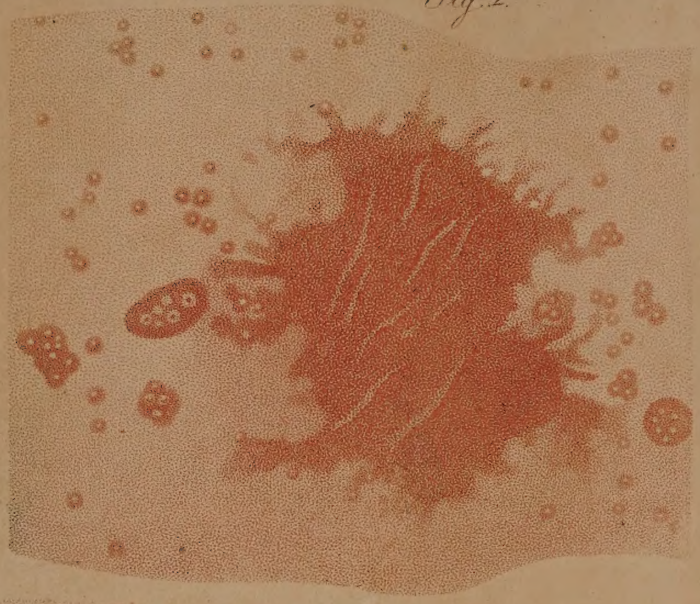

Fig. 3.

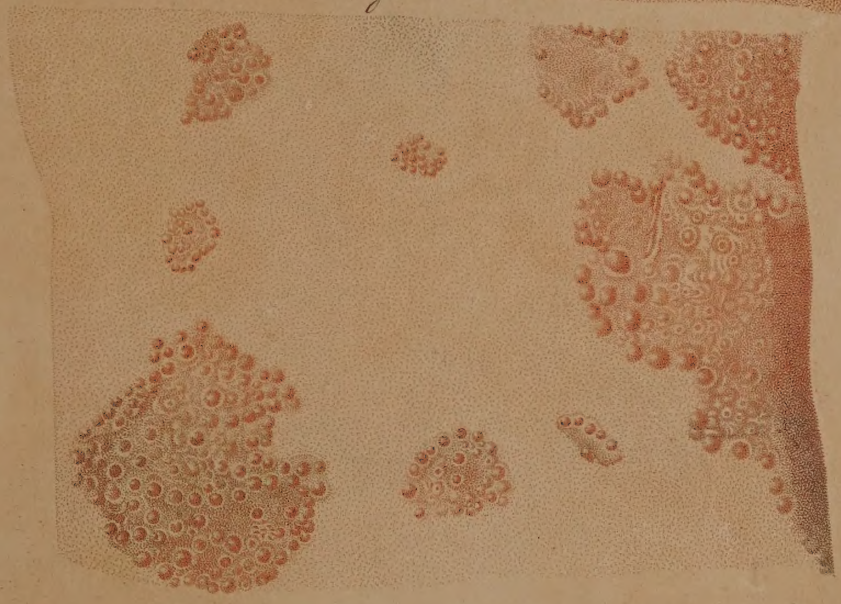

Fig. 4.

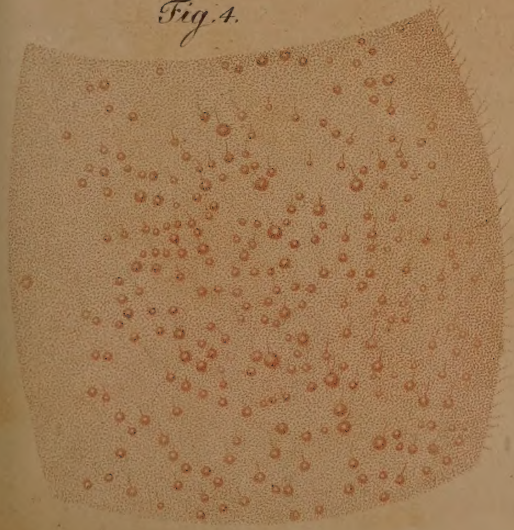

Fig. 5.

Lithotomia.

Taf. CXXXII.

Fig. 1.

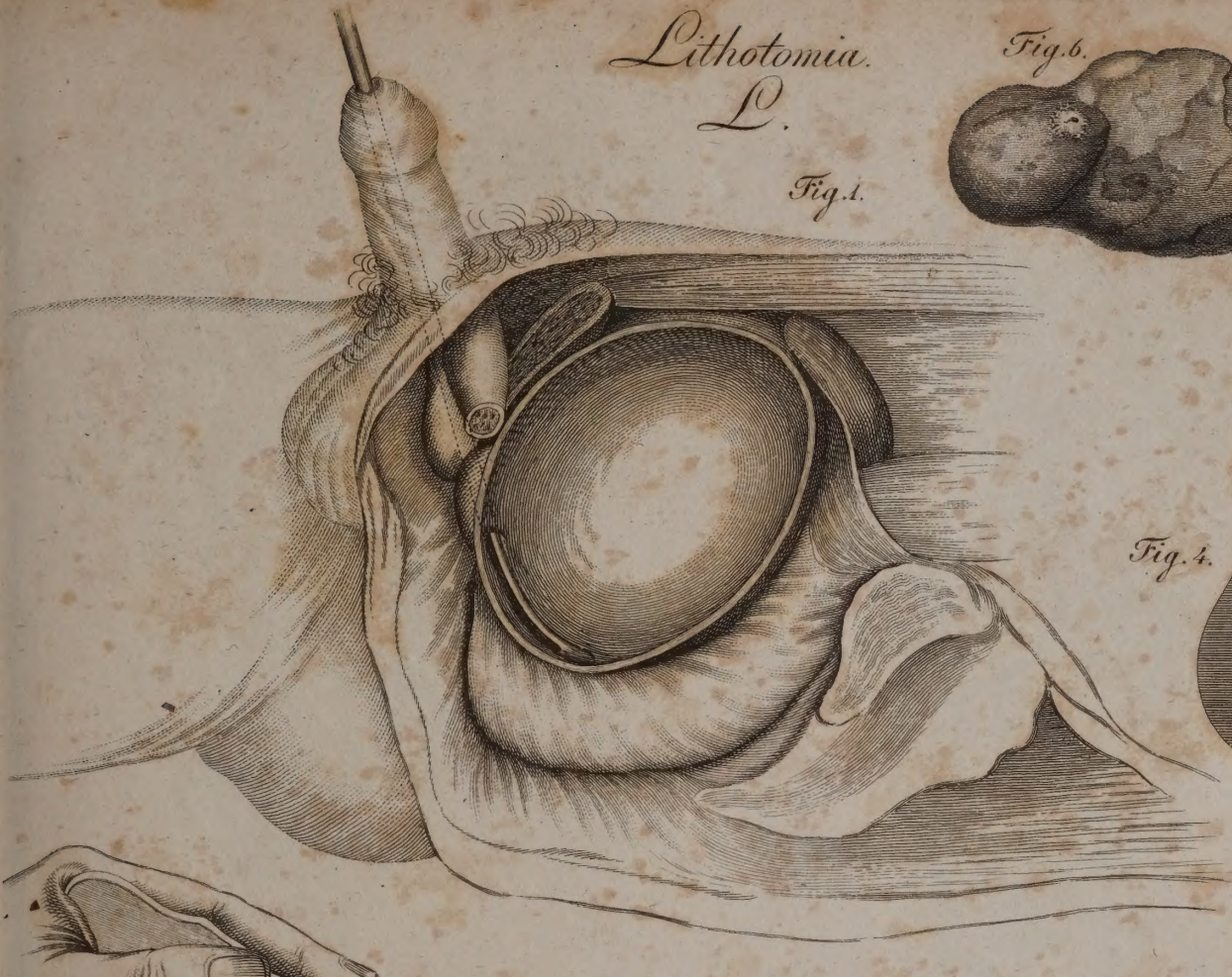

Fig. 6.

Fig. 4.

Fig. 3.

Fig. 2.

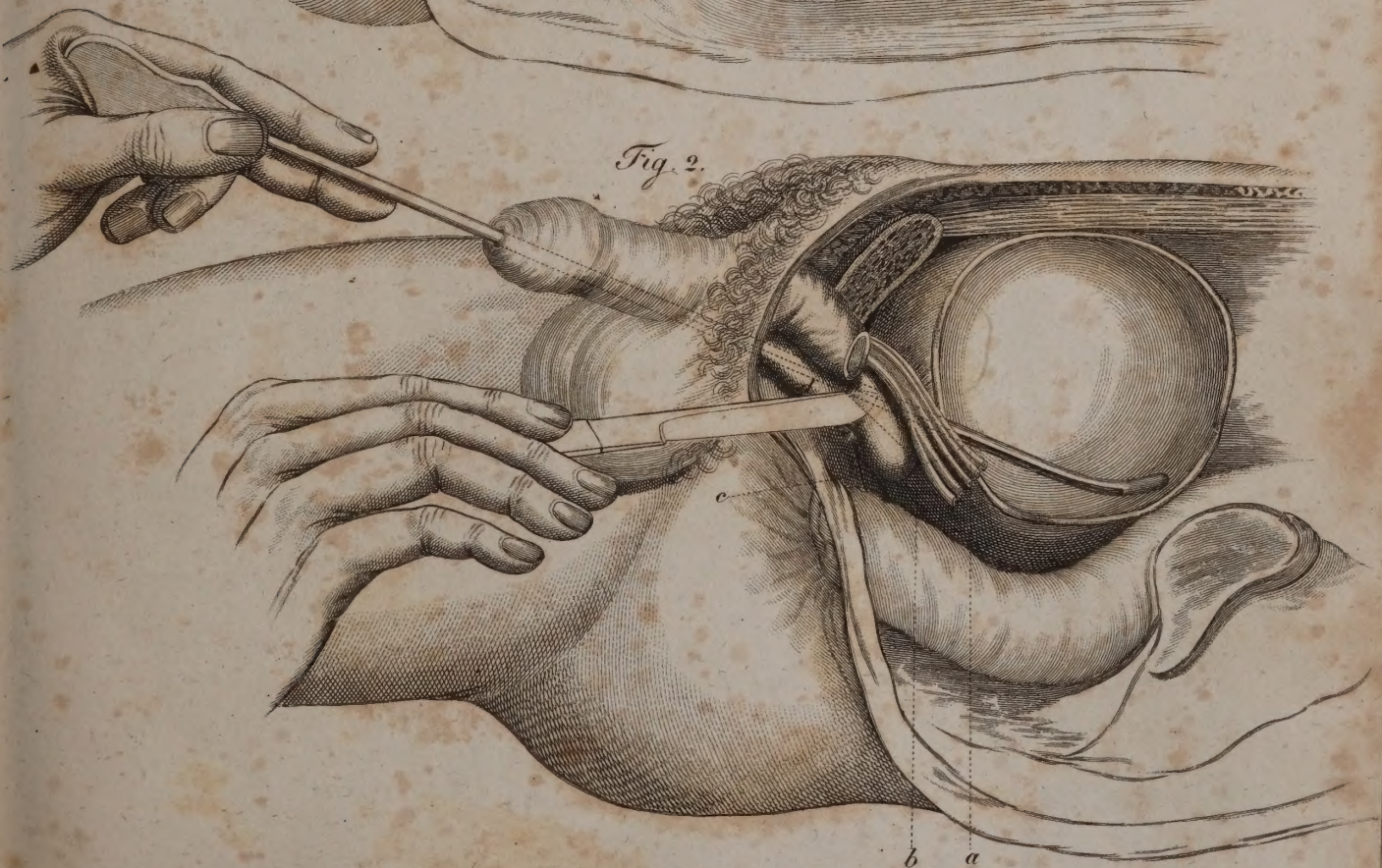

Fig. 5.

Fractura.

Taf. CXXXIII.

Fig. 1.

Fig. 2.

Fig. 4.

Fig. 3.

nach Charles Bell.

Distorsio Spinae.

D.

Taf. CXXXIV.

Fig. 1.

Fig. 3.

Fig. 4.

Fig. 2.

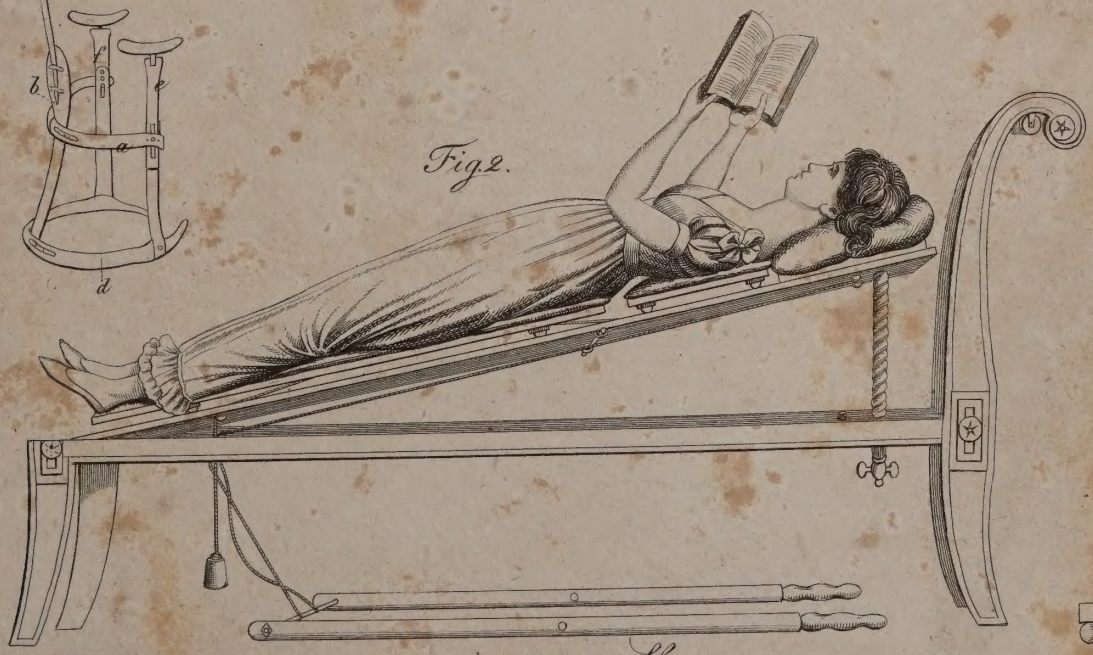

nach Shaw.

Oesophagotomia.

Fig. 1.

Fig. 2.



Fig. 3.

Fig. 4.

nach Eckold und Vacca Berlinghieri.

Hernia.

Taf. CXXXVI.

Fig. 1.

Fig. 2.

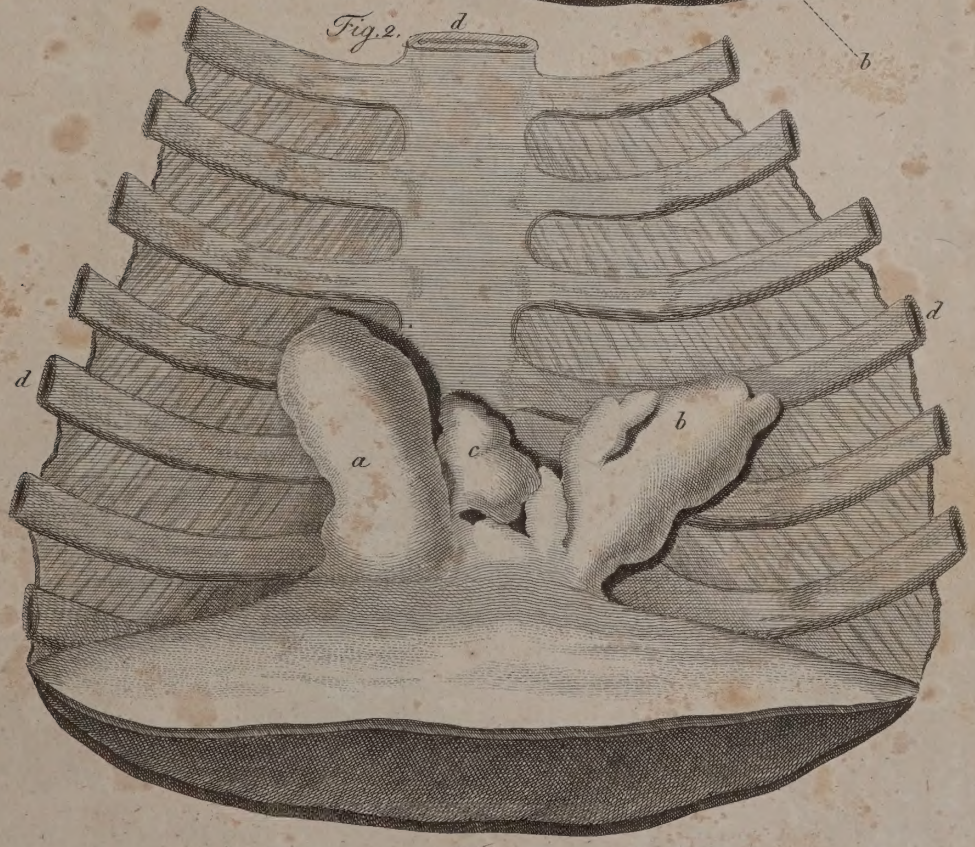

nach Bèclard.

Hyalonyxis.

Taf. CXXXVII.

Fig. 1.

Fig. 3.

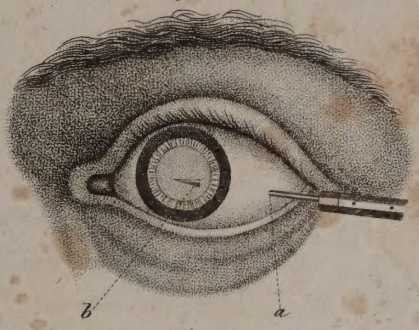

Fig. 2.

Fig. 4.

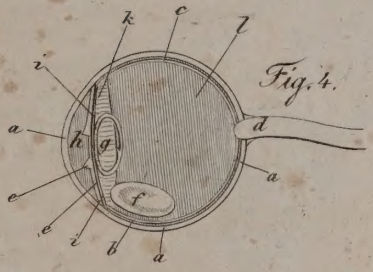

Fig. 9.

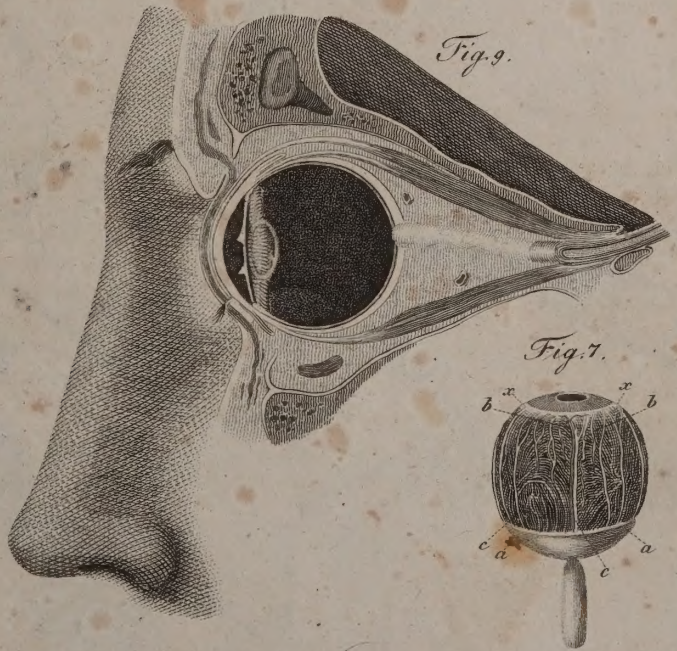

Fig. 5.

Fig. 6.



Fig. 7.

Fig. 8.

nach Bowen und Soemmering.

Lithotomia.

M

Fig. 2.

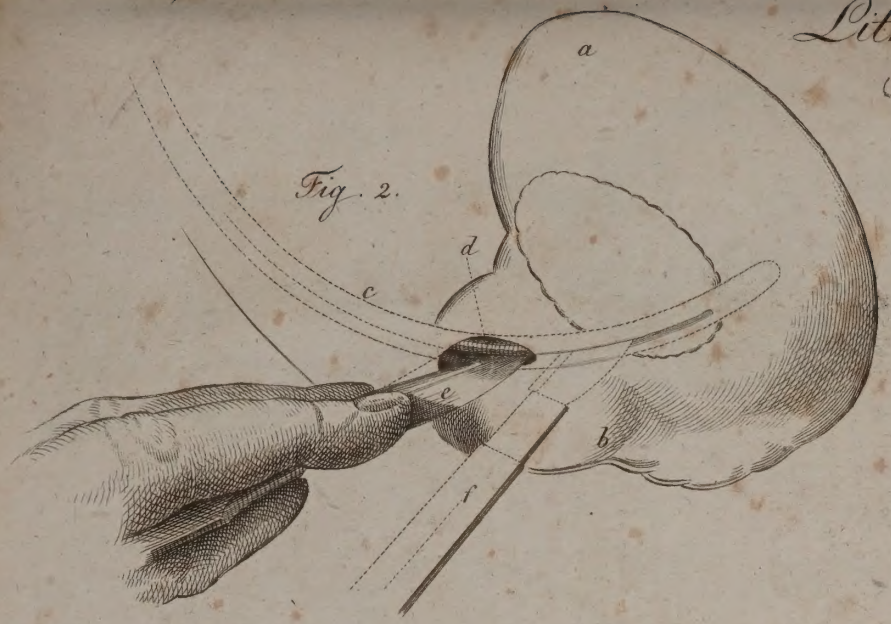

Fig 3

Fig. 1.

Fig. 4.

Fig. 1.b



nach Charles Bell.

Lithotomia.

Taf. CXXXIX.

Fig. 4.

Fig. 3.

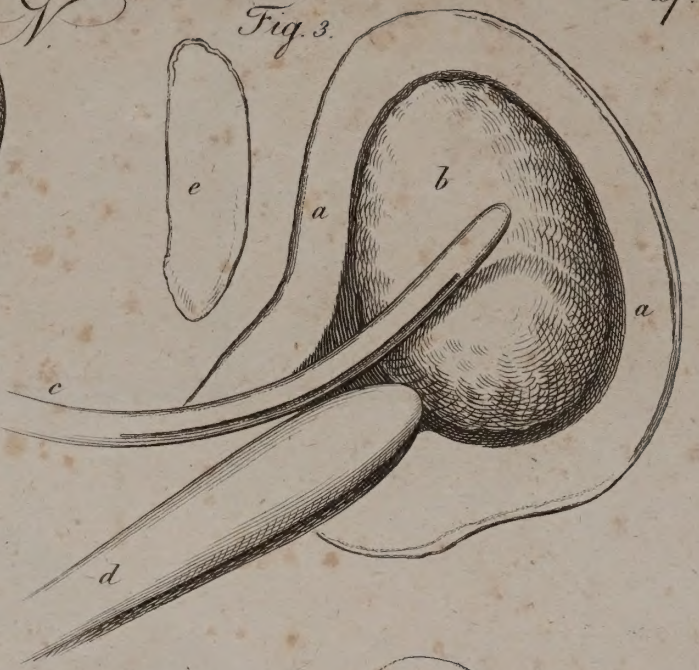

Fig. 1.

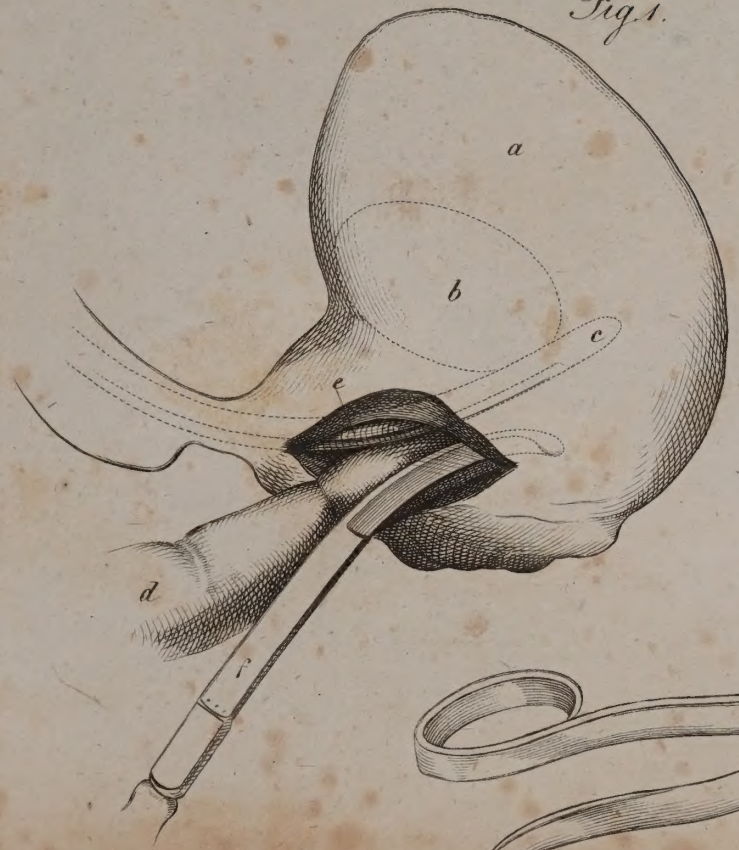

Fig. 2.

nach Charles Bell.

Scarlatina.

Taf. CXL. CXLI.

Fig. 1.

Fig. 2.

Fig. 3.

nach Bateman.

Staphyloraphia.

Taf. CXLII.

Fig. 1.

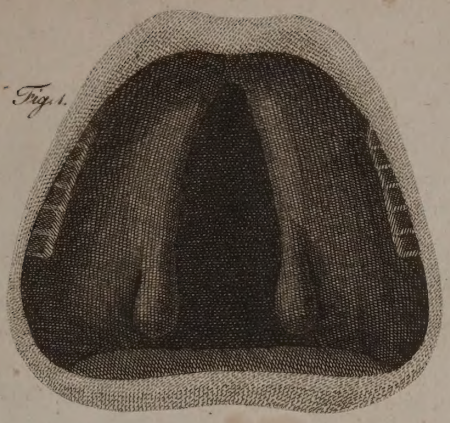

Fig. 2.

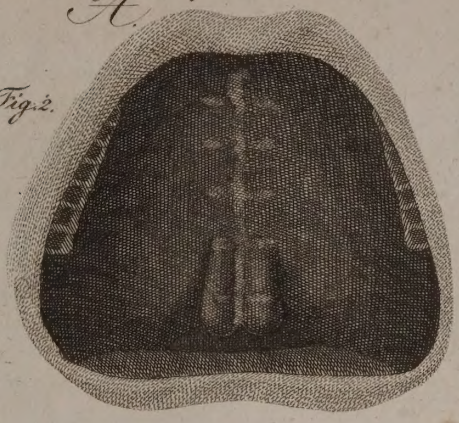

Fig. 15.



Fig. 3.

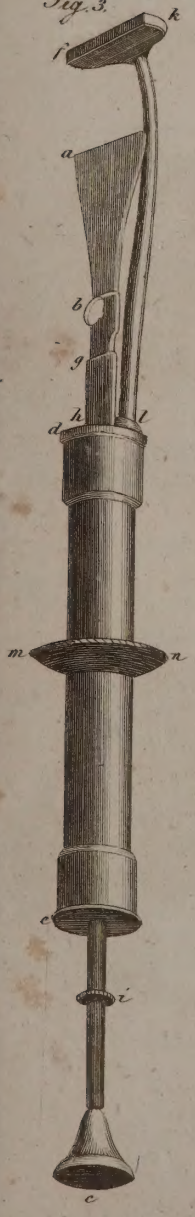

Fig. 4.

Fig. 5.



Fig. 6.



Fig. 7.

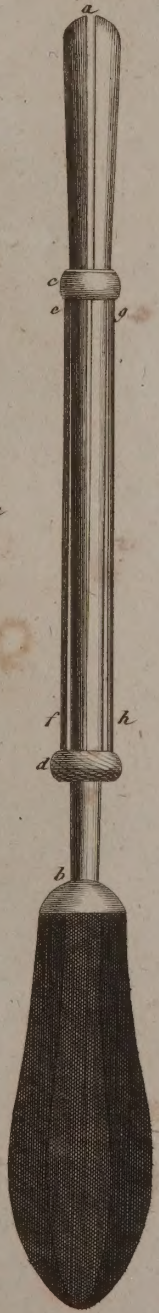

Fig. 8.

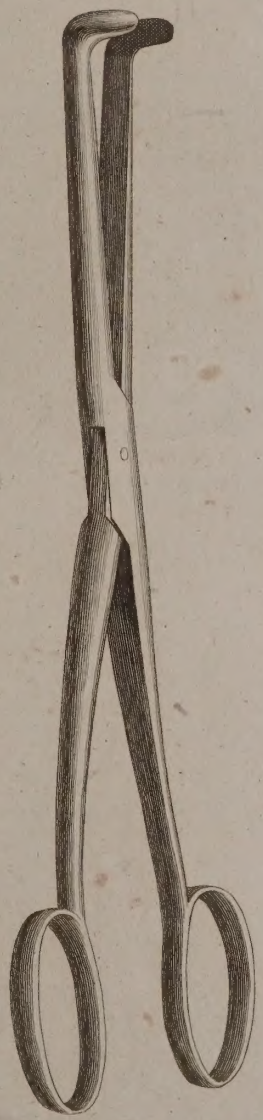

Fig. 9.

Fig. 10.

Fig. 11.

Fig. 12.

Fig. 13.

Fig. 14.

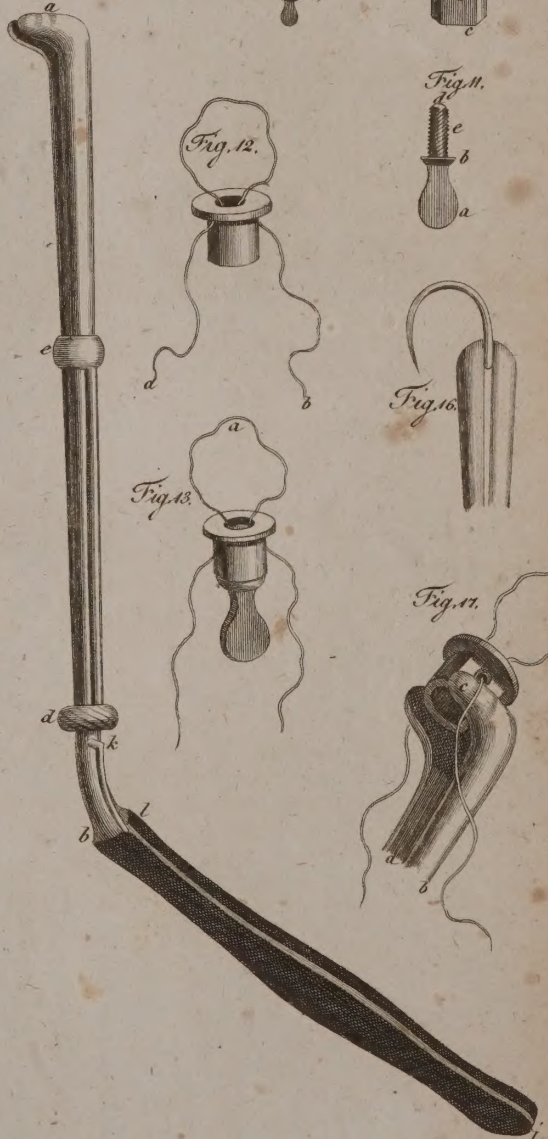

Fig. 16.

Fig. 17.

nach Graefe.

Staphyloraphia.
B.

Fig. 1.

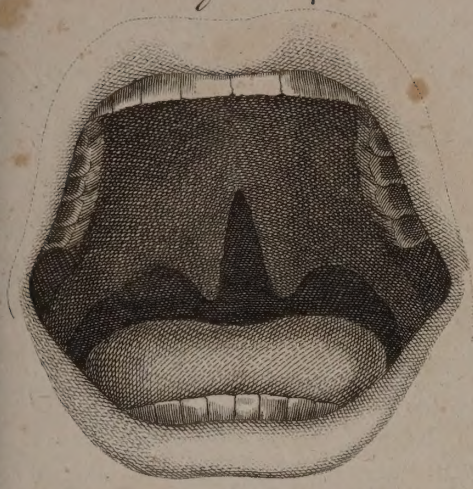

Fig. 2.

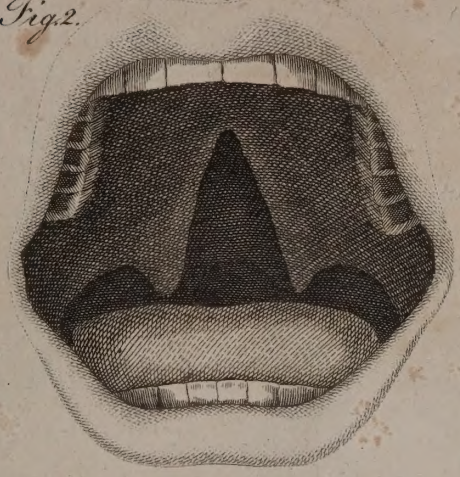

Fig. 3.

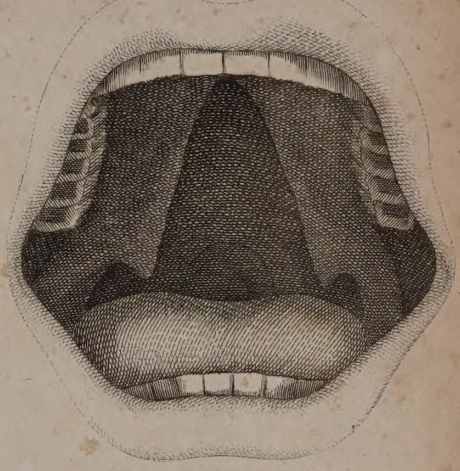

Fig. 4.

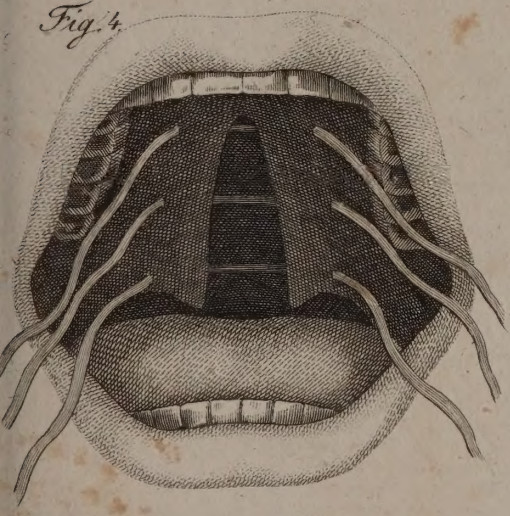

Fig. 5.

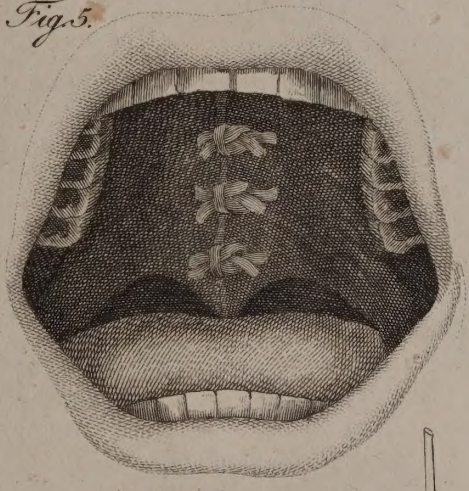

Fig. 6.

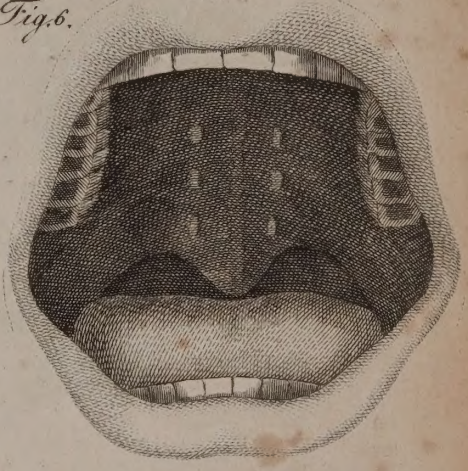

Fig. 7.

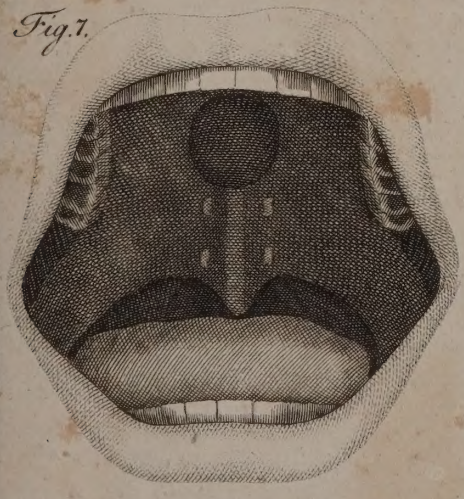

Fig. 8.

Fig. 9.
½.

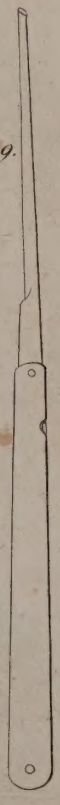

Fig. 12.
⅔.

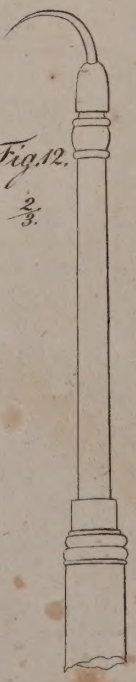

Fig. 11.
⅔.



Fig. 10.
⅔.



Fig. 13.



nach Roux.

Fig. 1. Aneurysma. Taf. CXLIV.

Fig. 2.

Fig. 3.

Aneurysma.

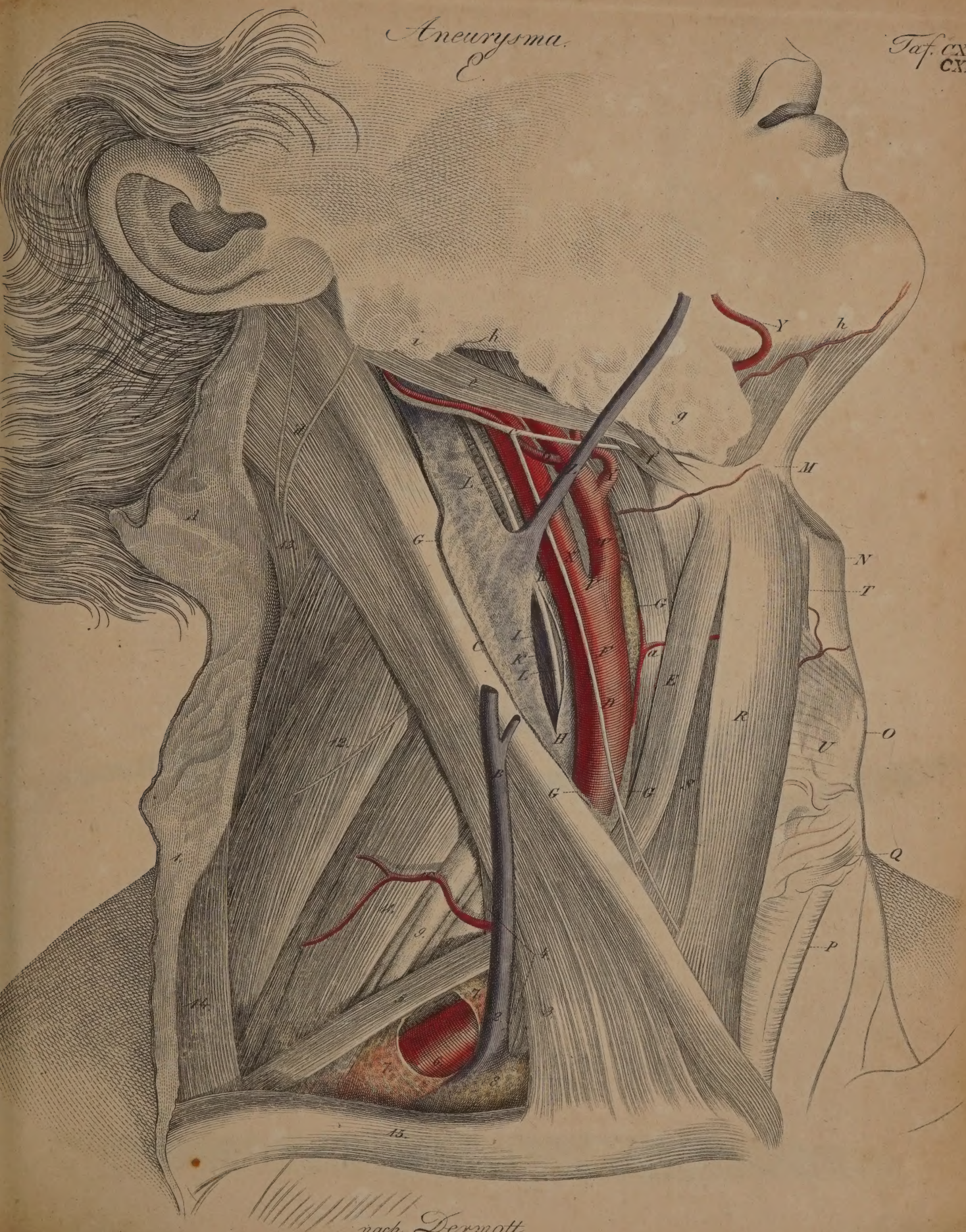

nach Dermott

Fistula lacrymalis

A.

Fig. 2.

Fig. 1.

Taf. CXLVII.

Fig. 3.

Fig. 5.

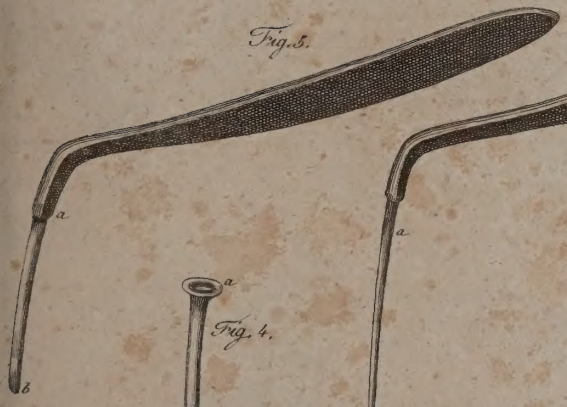

Fig. 7.

Fig. 8.

Fig. M.

Fig. 4.

Fig. 6.

Fig. 9.

Fig. 10.

Fig. 12.

F.
A
B.
E
C
D
L
N
M
K
G
H
I
nach Dermott.

Aneurysma.

G.

Fig. 1.

Fig. 3.

Fig. 2.

Fig. 4.

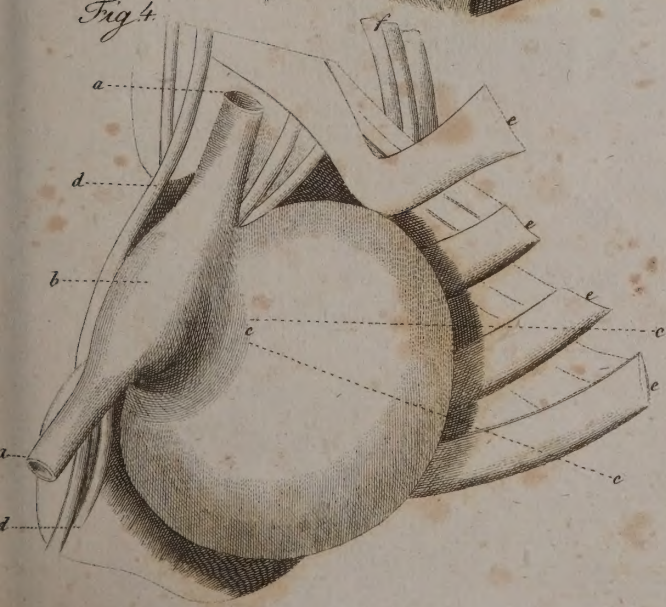

Fig. 5.

nach Pelletan, und Langenbeck.

Acne.

Fig. 1.

Fig. 2.

Fig. 3.

nach Batemann.

Fractura Olecrani.

Taf. CLII.

Fig. 1.

Fig. 2.

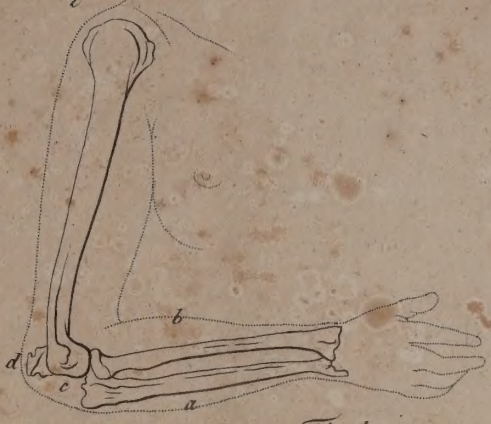

Fig. 3.

Fig. 5.

Fig. 6.

Fig. 4.

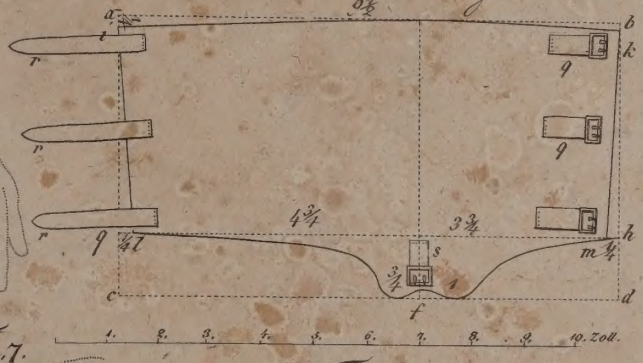

Fig. 7.

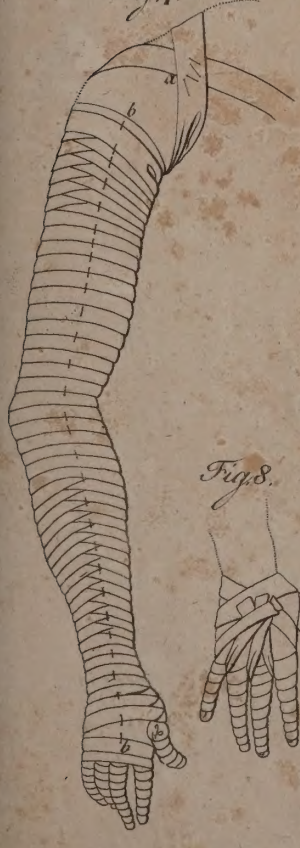

Fig. 8.

Fig. 9.

Fig. 10.

Fig. 11.

Fig. 12.

Fig. 13.

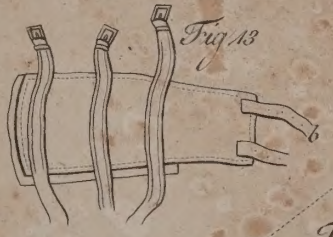

Fig. 14.

Fig. 15.

Fig. 16.

nach Teiler und Amesbury.

Fistula vesico vaginalis

Taf. CLIII.

A

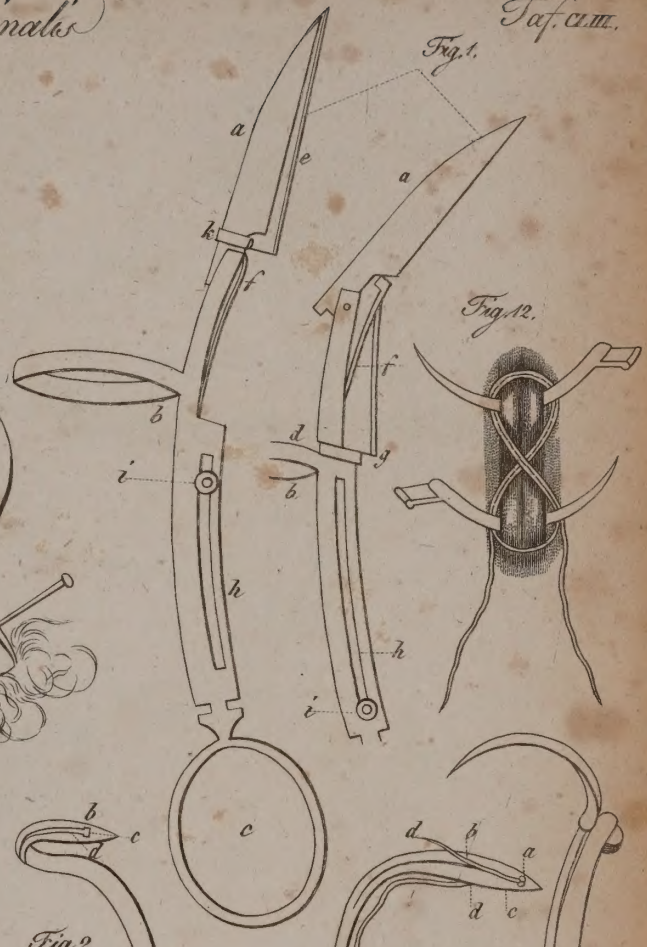









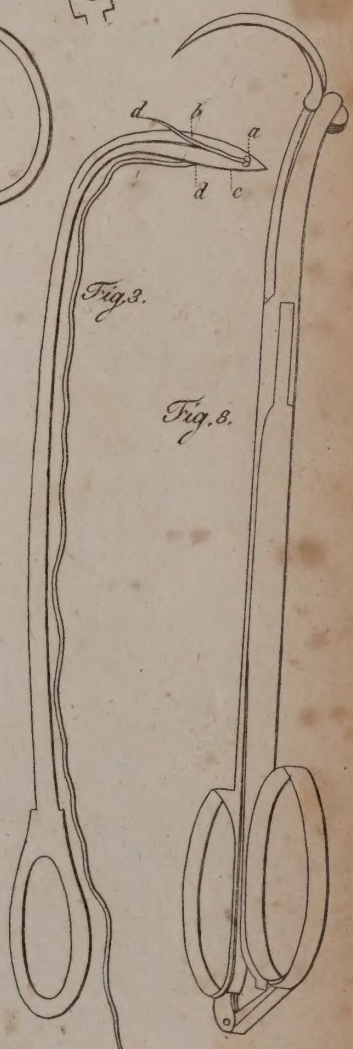

nach Naegele.

Fistula vesico vaginalis.

B.

Fig. 7.

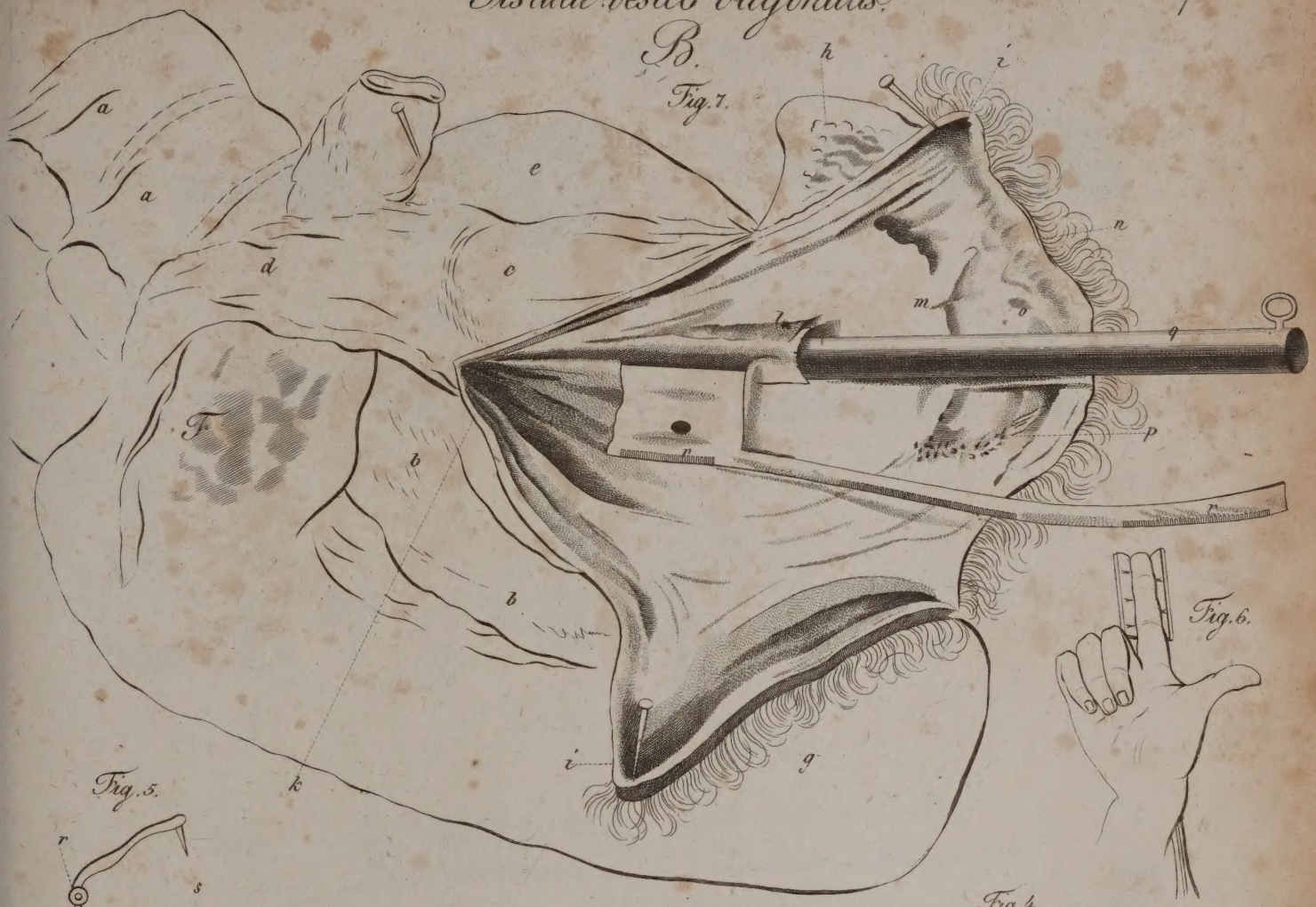

Fig. 6.

Fig. 5.

Fig. 4.



K K K

Fig. 2.

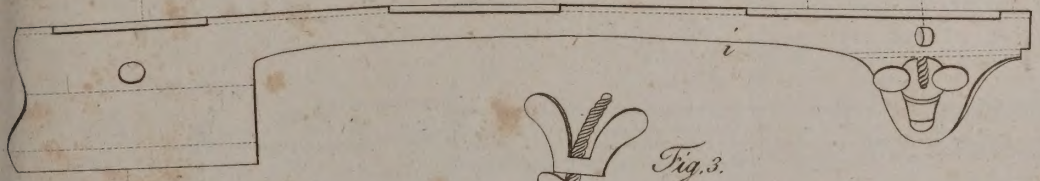

Fig. 3.

A

Fig. 1.

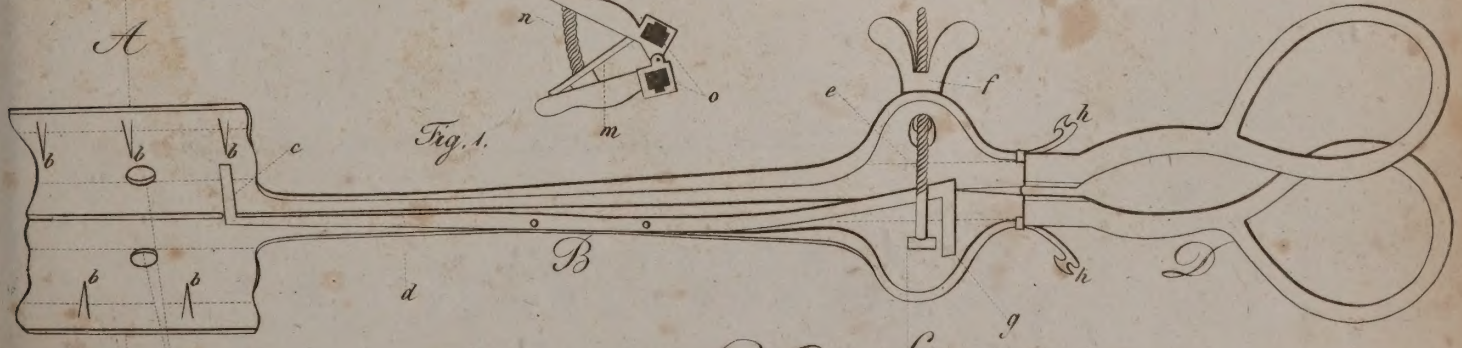

A a

nach Naegele.

Fistula vesico-vaginalis.

Taf. CLV.

Fig. 1.

Fig. 11

Fig. 2

Fig. 12

Fig. 3.

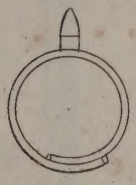

Fig. 4.



Fig. 5.



Fig. 6

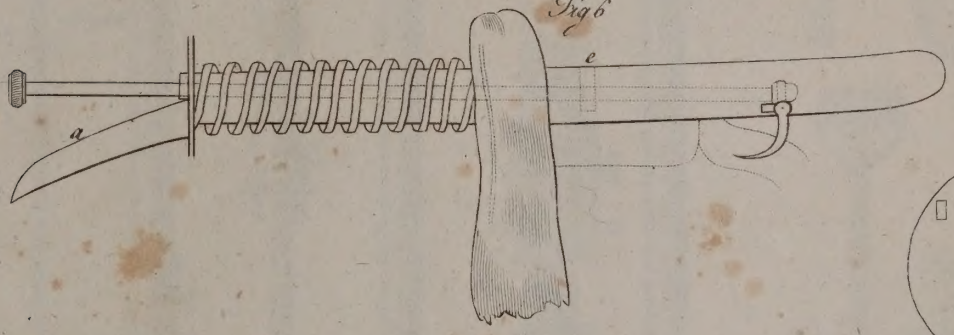

Fig. 10.

Fig. 7.



Fig. 7.b.

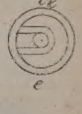

Fig. 8.



Fig. 9.



nach Lallemand

Apparatus lithontripticus.



Fungus medullaris oculi.

Tab. CLVII.

Fig. 3.

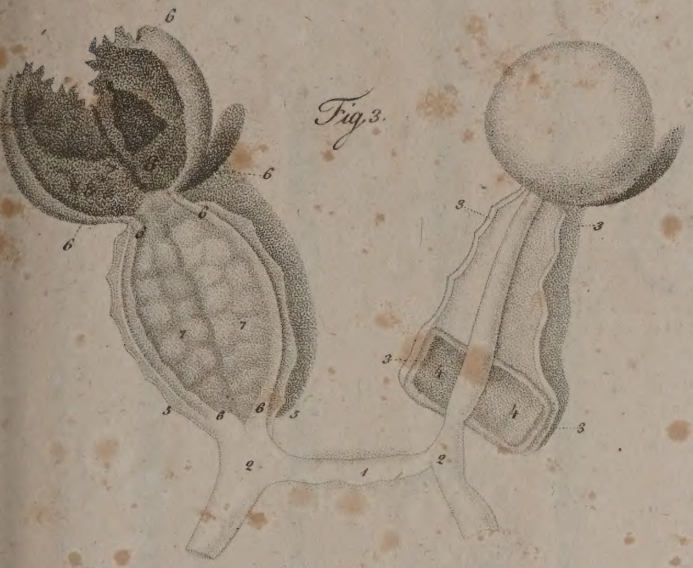

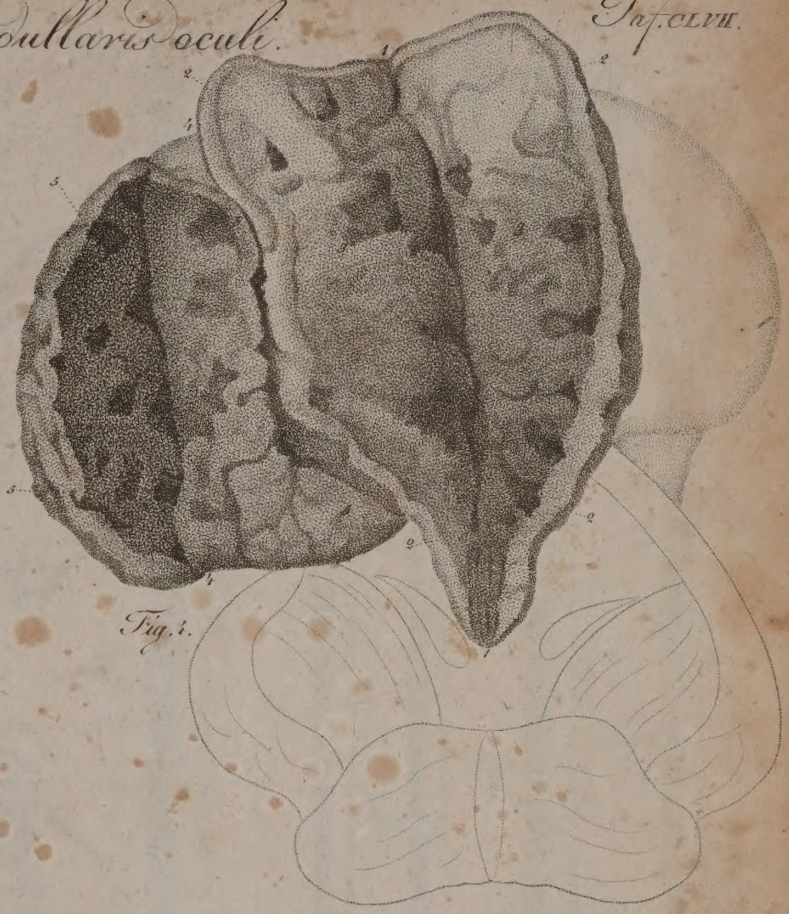

Fig. 1.

Fig. 2.

Fig. 1.

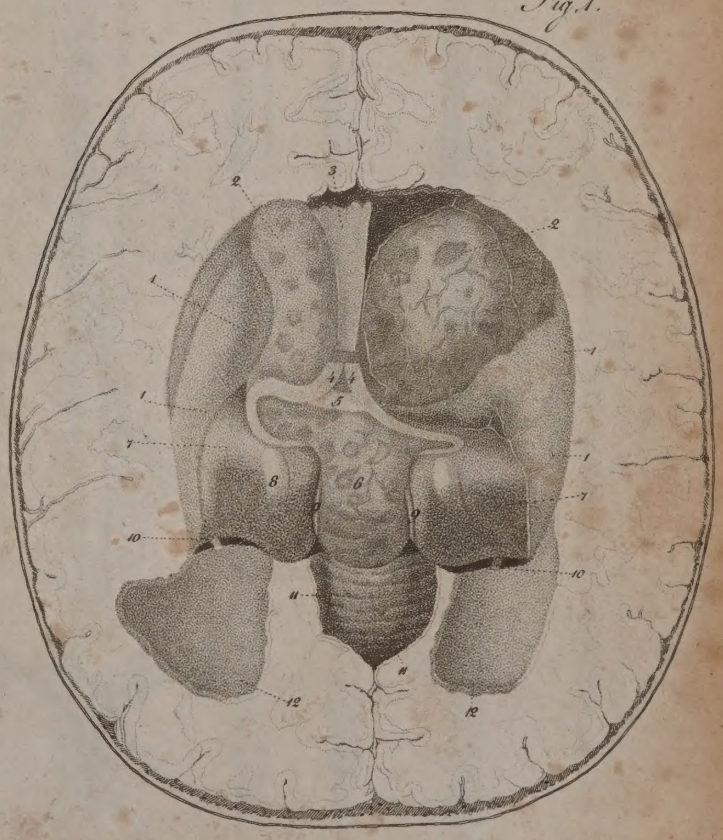

nach Panizza

Apparatus lithontripticus.

B.



nach Leroy.

Spinae Distorsio.

E.

Fig. 1.

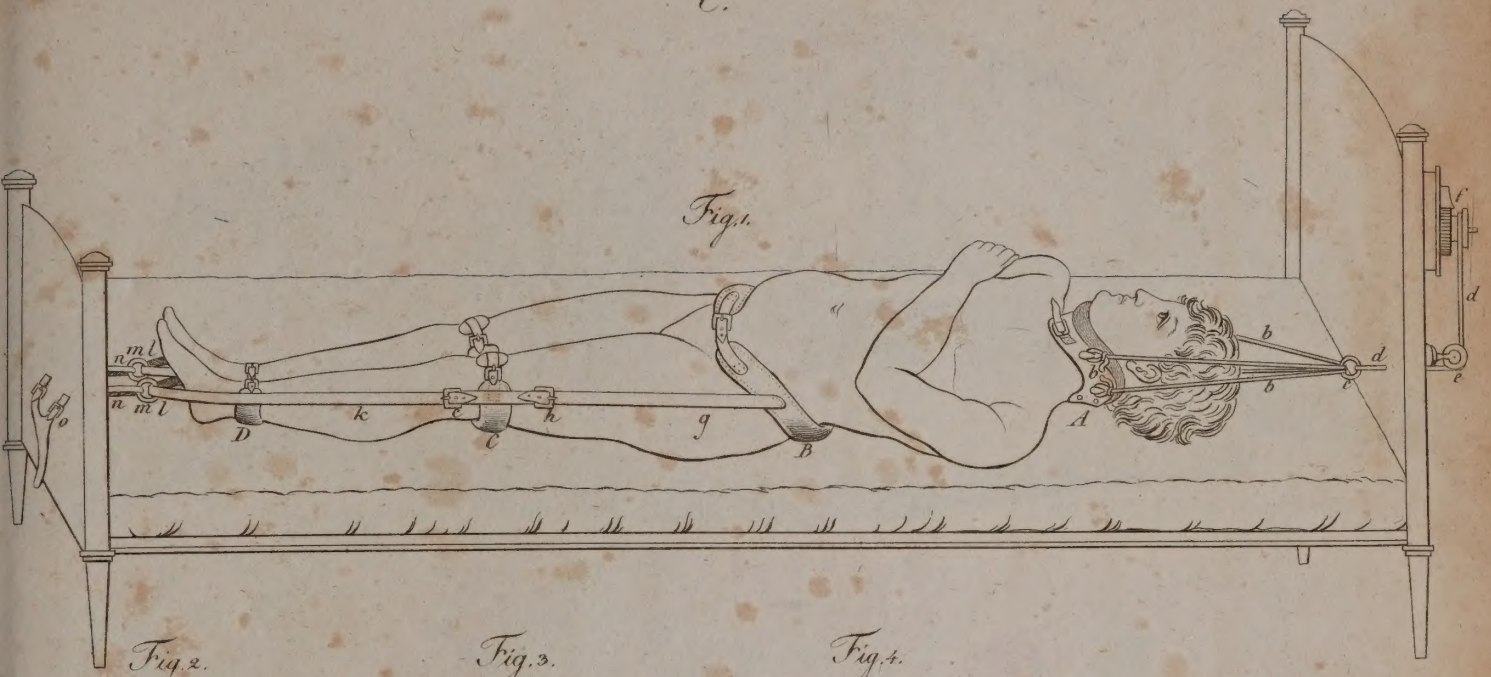

Fig. 2.



Fig. 3.

Fig. 4.

Fig. 5.

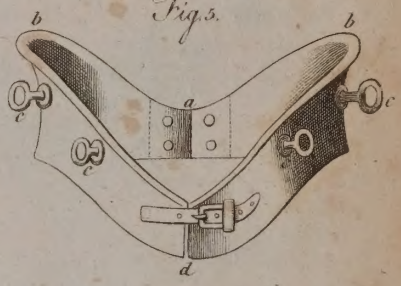

Fig. 6.

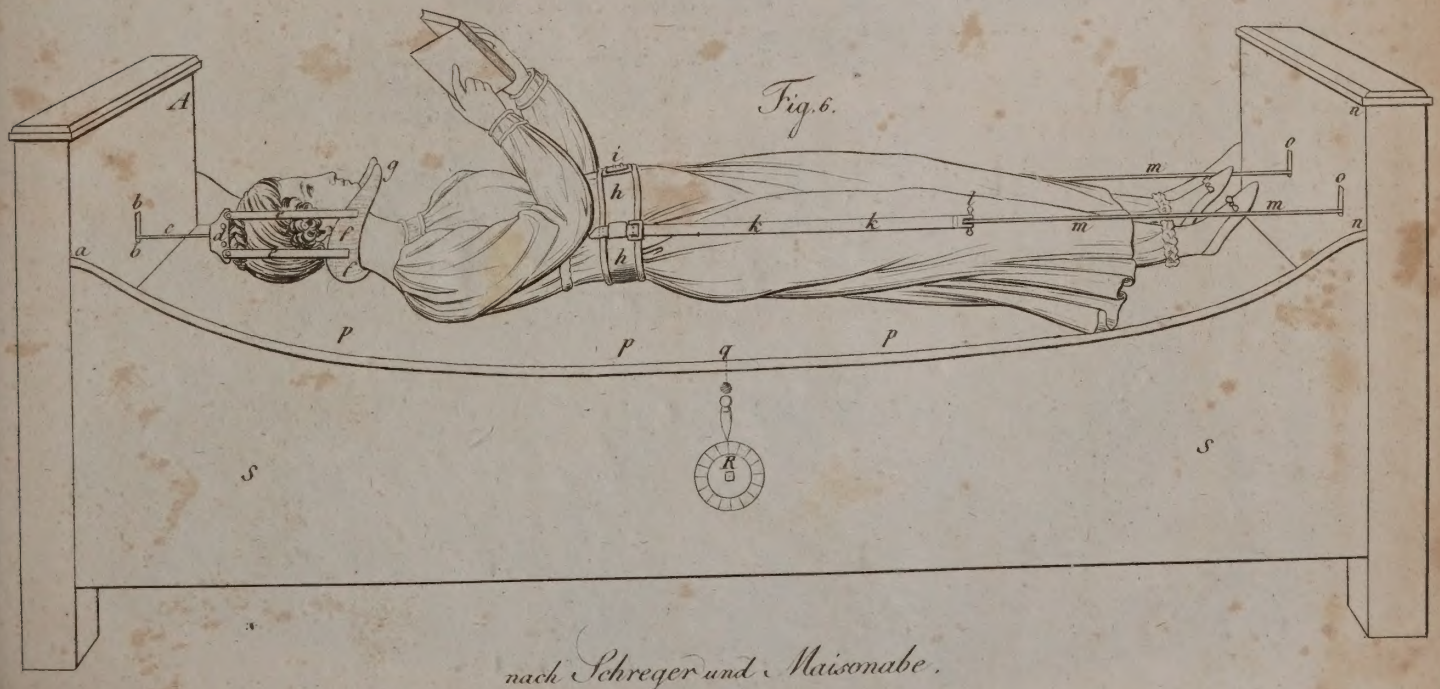

nach Schreger und Maisonabe.

Impetigo.

Fig. 1.

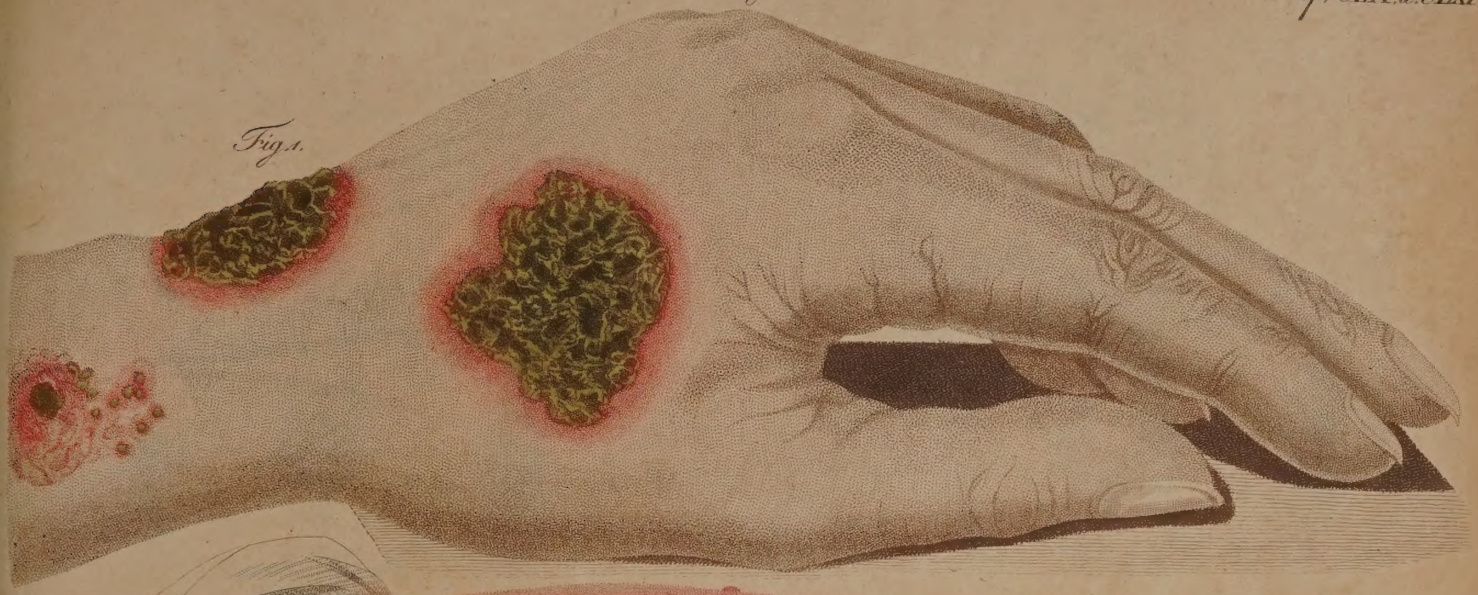

Fig. 2.

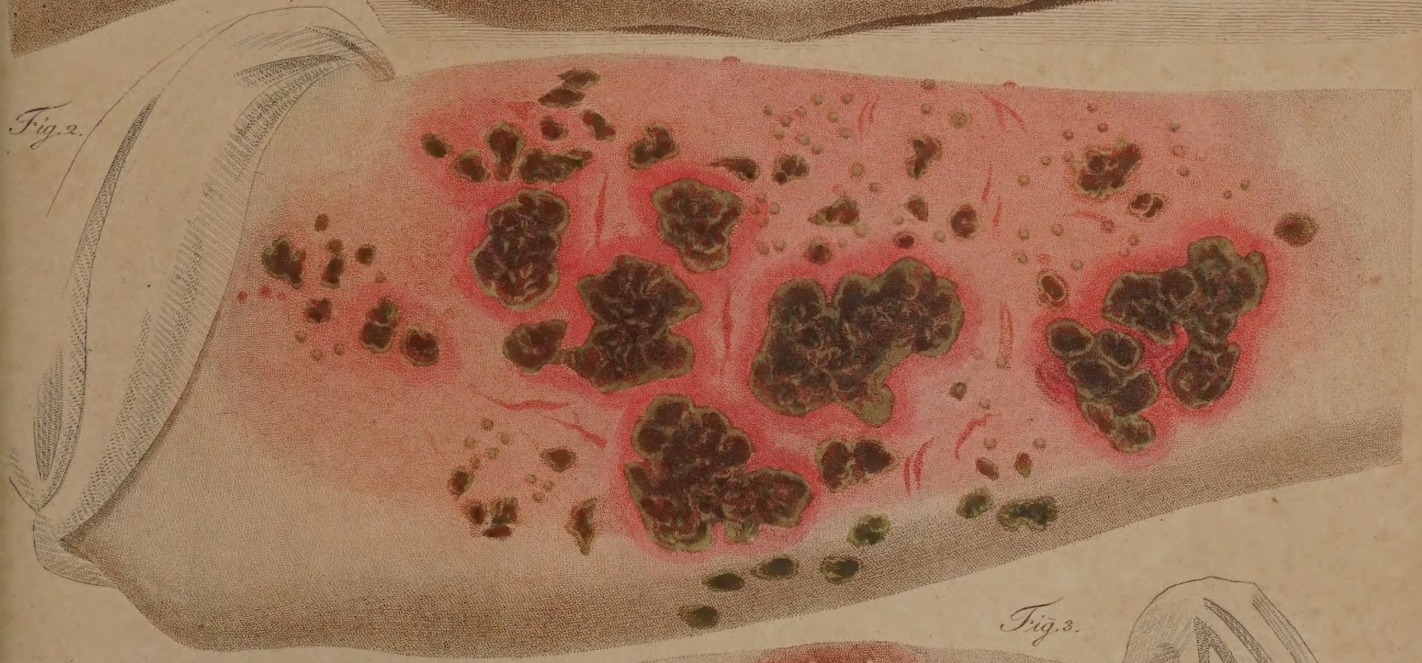

Fig. 3.

nach Bateman.

Rhinoplastice.

A.

Fig. 1.

Fig. 2.

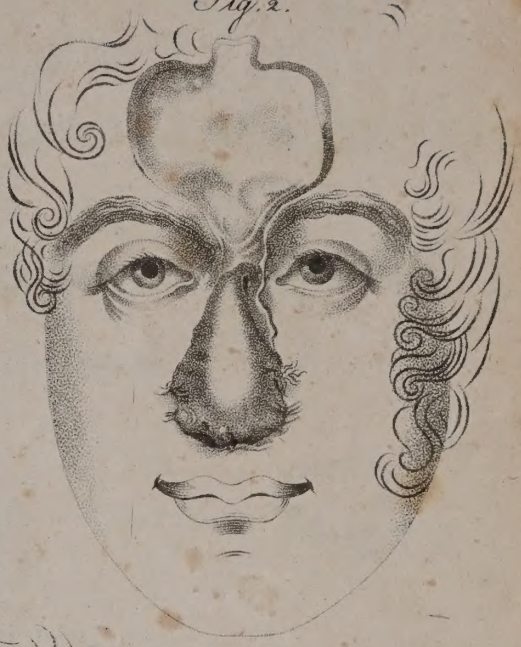

Fig. 3.

Fig. 4.

Fig. 5.

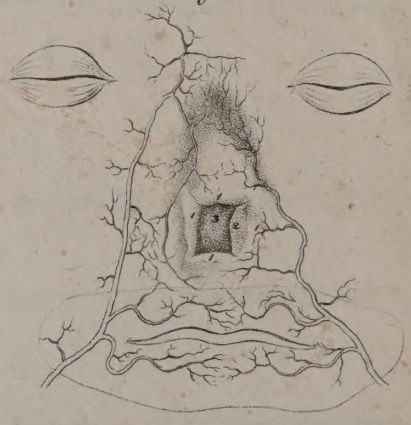

nach Carpue u. v. Walther.

Apparatus lithontripticus.

C.

Fig. 1.



Fig. 2.

Fig. 3

Fig. 4

Fig. 5.

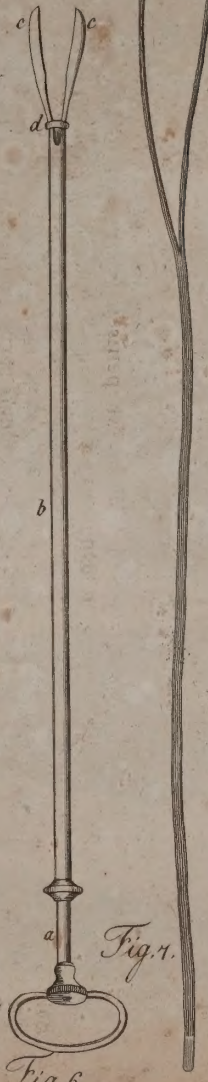

Fig. 6.

Fig. 7.

Fig. 8.

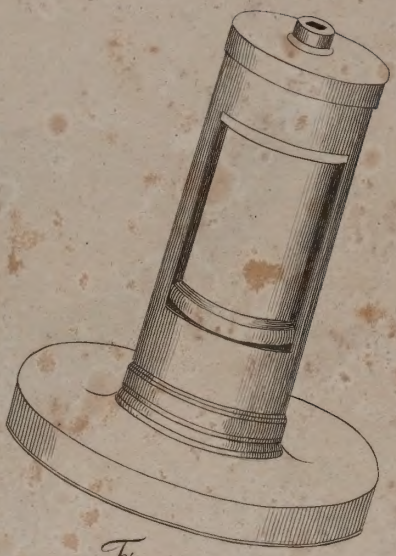

Fig. 9.



Fig. 10.

Fig. 11.

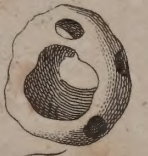

Fig. 12.

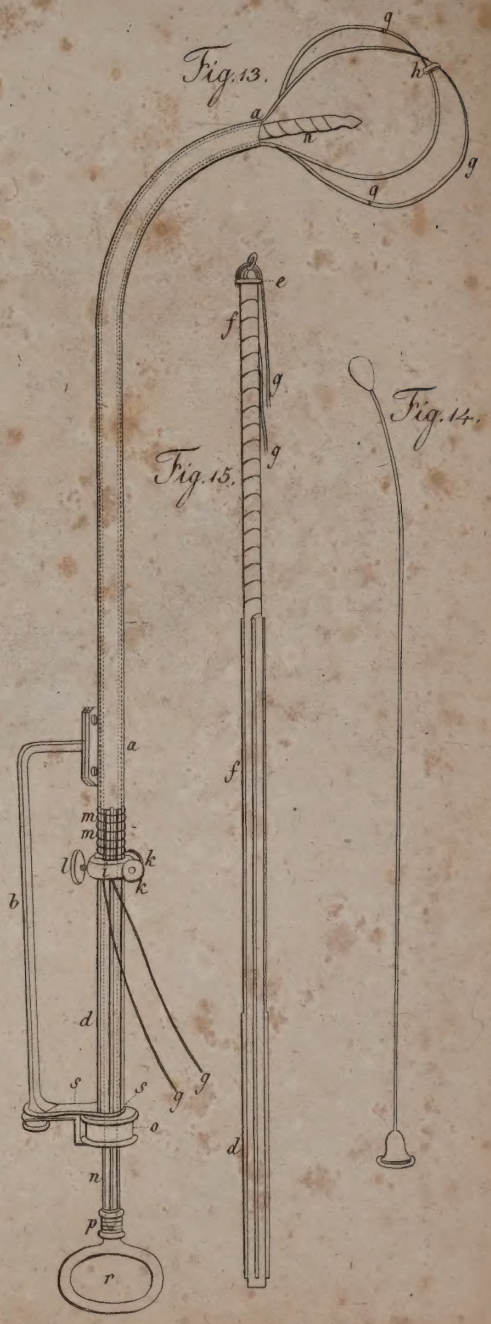

Fig. 13.

Fig. 14.

Fig. 15.

Fig. 15.*

nach Luken und Griffiths.

t
o
g
s
u
m
p
n
b
r
l
a
c
d
e
f
i
k
x
d
c
e
b
3
5
7
9
11
13
15
f
a



Calculi urinarii.

Fig. 1.

Fig. 7.

Fig. 12.

Fig. 8.

Fig. 2.

Fig. 3.

Fig. 13.

Fig. 9.

Fig. 10.



Fig. 14.

Fig. 5.

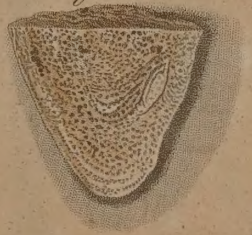

Fig. 4.

Fig. 11.

Fig. 15.

Fig. 16.

Fig. 6.

Fig. 17.

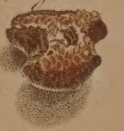

nach Prout.

Aurium Morbi.

Fig. 10.



Fig. 2.

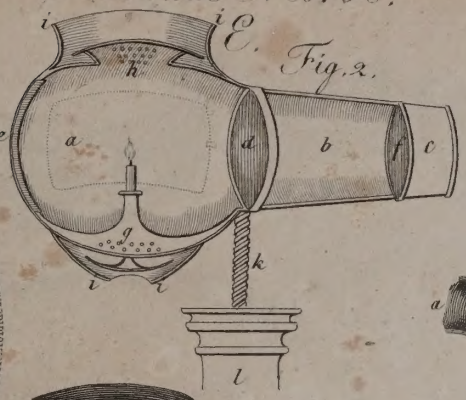

Fig. 5.

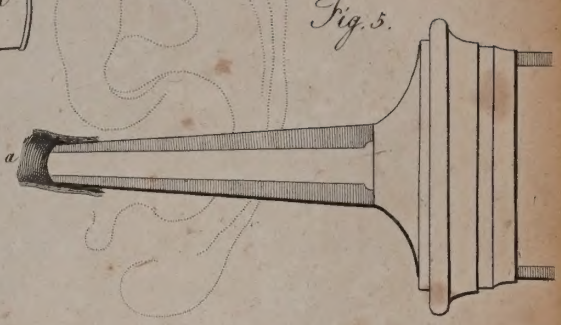

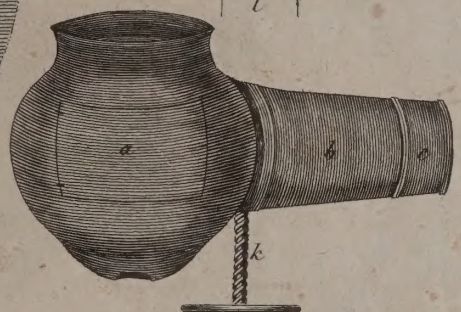

Fig. 6.

Fig. 11.

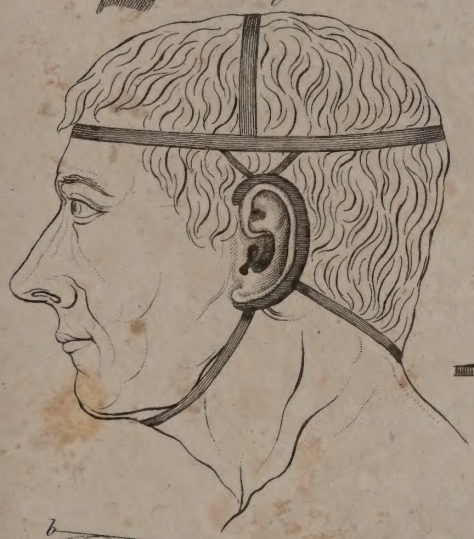

Fig. 1.

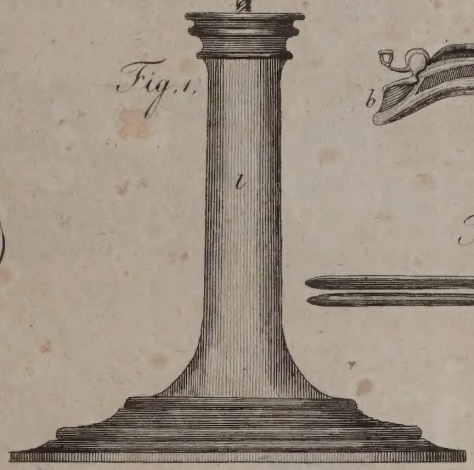

Fig. 7.

Fig. 8.



7. 8.*

Fig. 3.

Fig. 4.

Fig. 9.

nach Buchanan.

Lithotomia.

N.

Fig. 1.

Fig. 2.

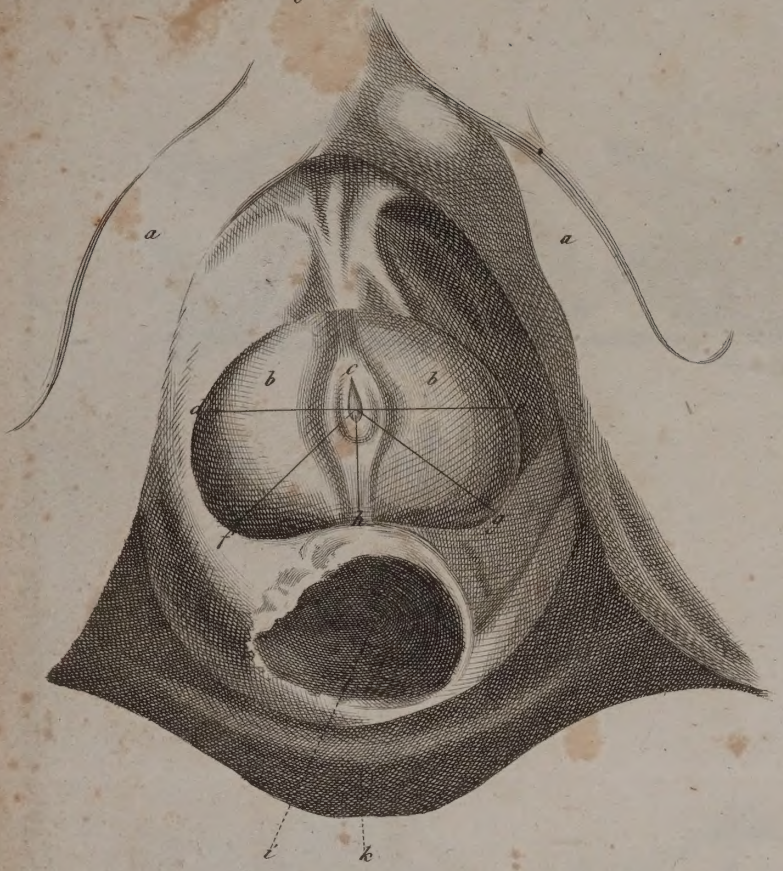

Fig. 3.



nach Froriep, Senn, u. Ollivier.

Spinae Distorsio.

Taf. CLXLV.

D

Fig. III.

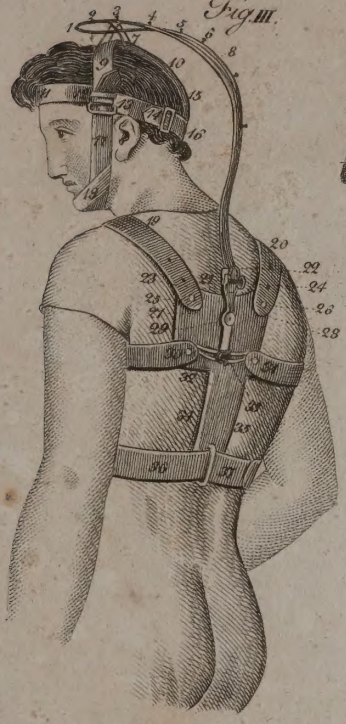

Fig. VI.



Fig. V.



Fig. VII.

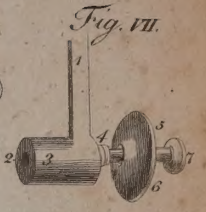

Fig. IV.

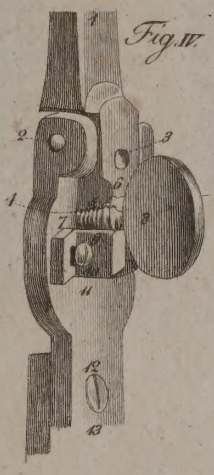

Fig. I.

Fig. II.

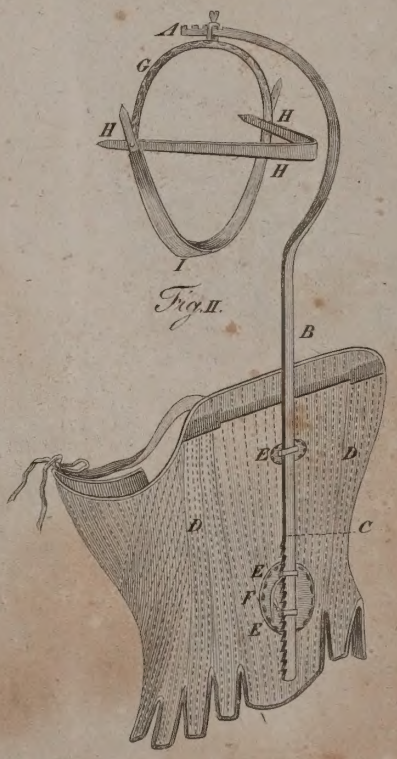

nach Le Vacher und Delacroix

Fig. 1. Ichthyosis Fig. 2. Taf. CLXX. CLXXI.

Fig. 3.

nach Batemann.

Strictura et Ulcus Oesophagi.

A.

Fig. 1.

Fig. 2.

nach Baillie.

Forfices.

C.

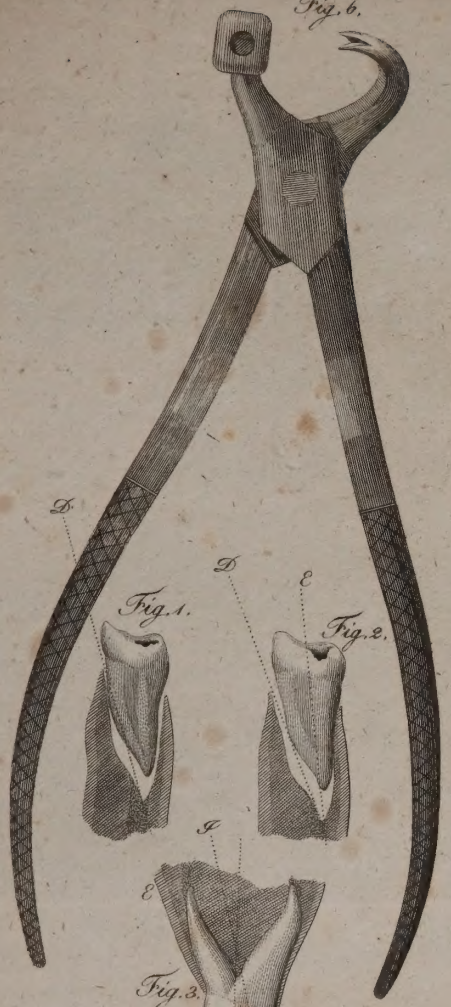

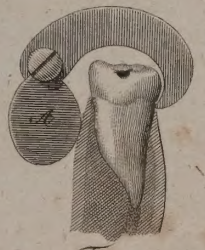

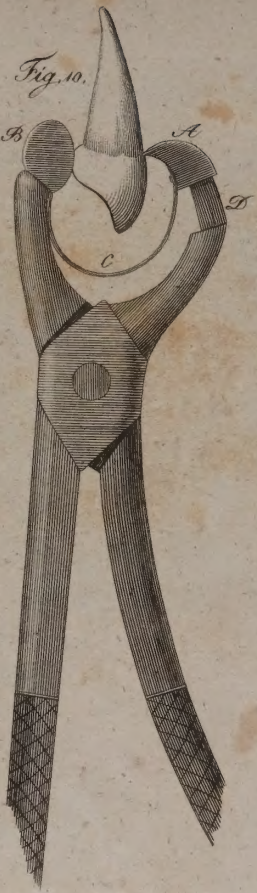

nach de la Fons.

Strictura Oesophagi.

C.

Fig. 1.

Fig. 2.

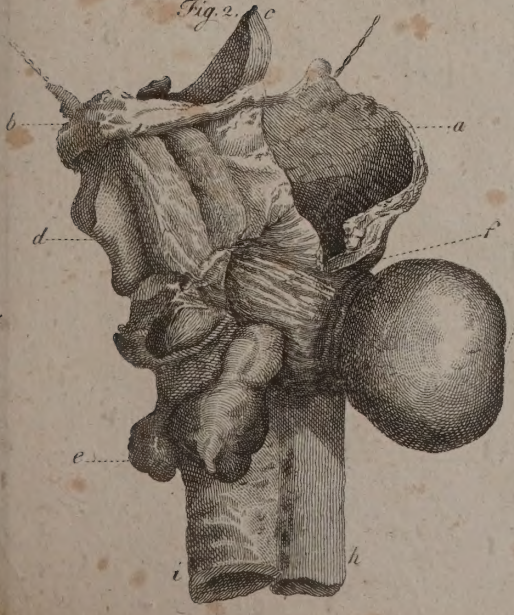

Fig. 4.

Fig. 5.

Fig. 3.

nach Charles Bell.

Siphones.

Fig. 4.

Fig. 5.

Fig. 4.b.

Fig. 9.

Fig. 10.

Fig. 7.b

Fig. 7.

Fig. 1.

Fig. 8.

Fig. 7.a

Fig. 2.

Fig. 6.

Fig. 3.

Fig. A.

Fig. B.

Fig. C.

Tracheitis.

nach Baillie, Albers u. Bretonneau.

Tracheotomia.

Taf. CLXXIII.

nach Bretonneau, Richter, Beinl, Bell, Goodeve, u. Monro.

Strictura et Ulcus Oesophagi.

B.

Fig. 1.

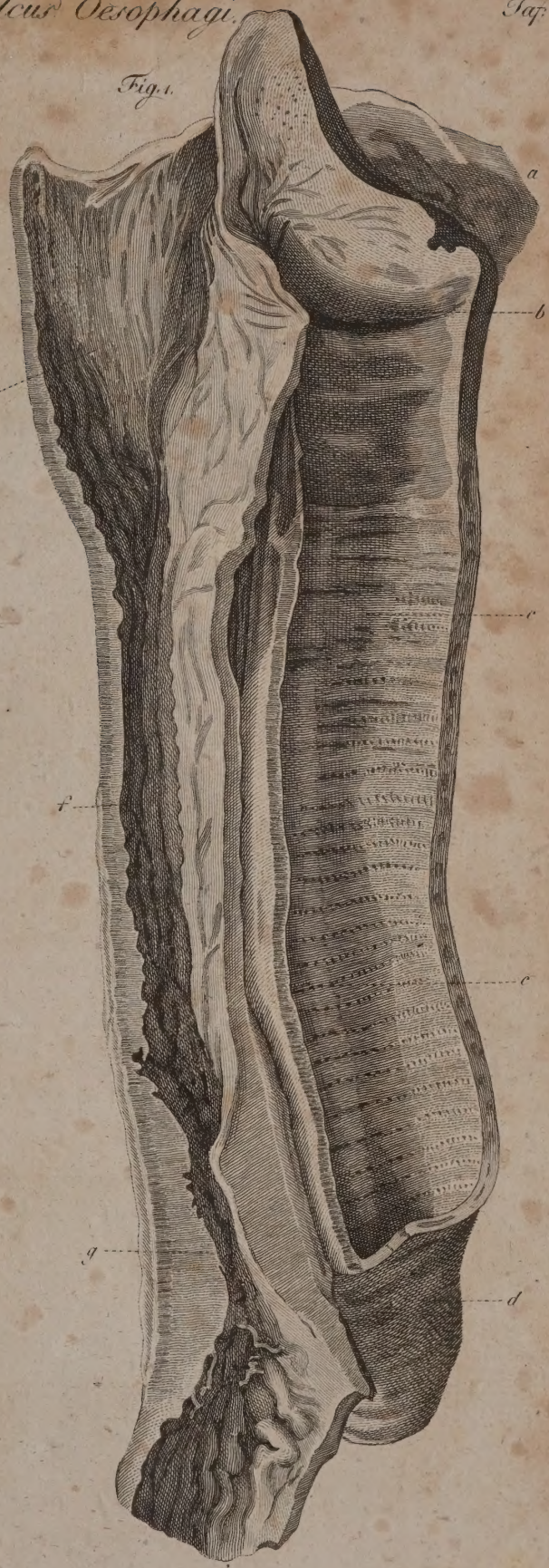

Fig. 2.

nach Baillie.

Luxatio (femorum) congenita.

Taf. CLXXX.

Fig. 2.

Fig. 1.

Fig. 3.

nach Dupuytren.

Enteroraphia.

Taf. CLXXXI.

Fig. 1.

Fig. 2.

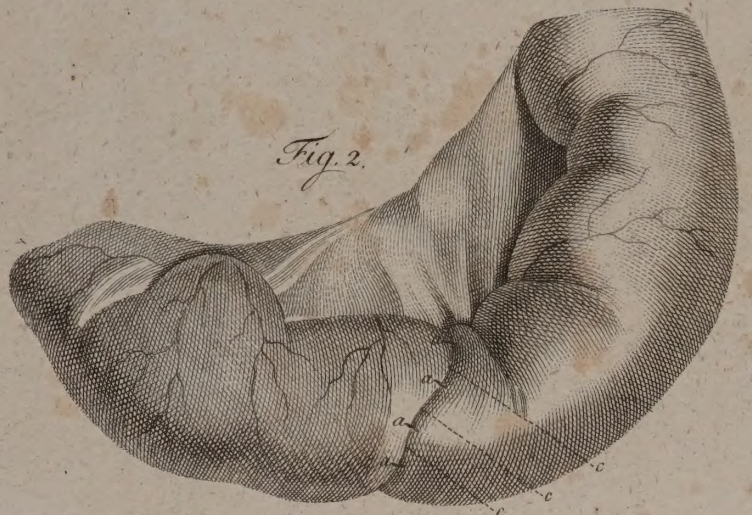

Fig. 4.

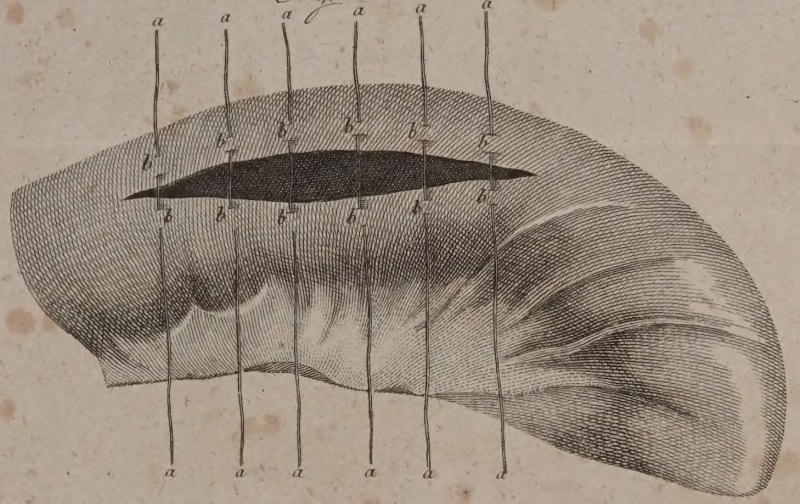

Fig. 3.

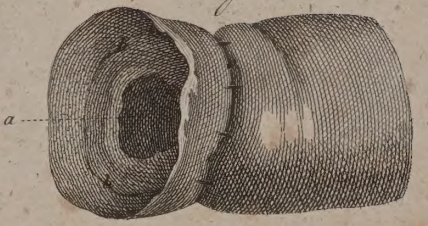

nach Lembert.

Fig. 1. *Distortio Spinae.* Taf. CLXXXII.

Fig. 2.

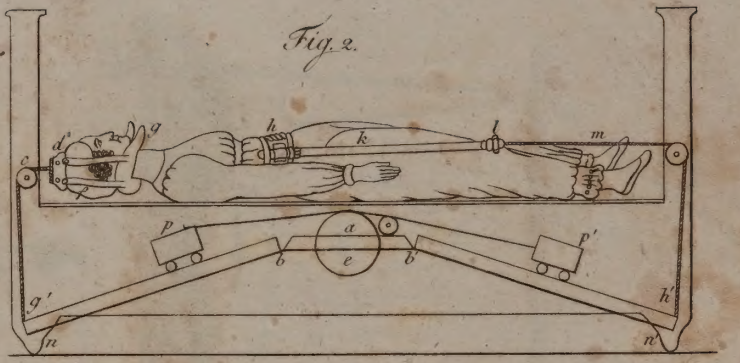

Fig. 3.

Fractura. M

Fig. 1.

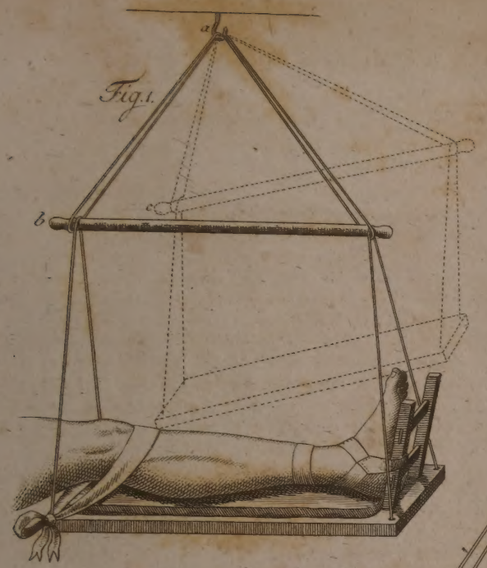

Fig. 2.

Fig. 3.

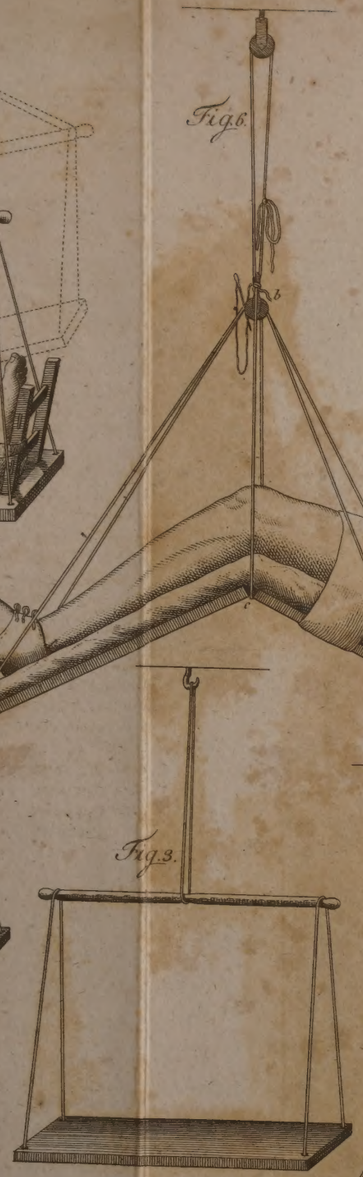

Fig. 4.

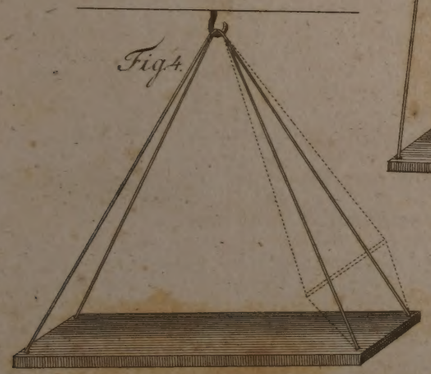

Fig. 5.

Fig. 6.

Fig. 7.

Fig. 8.

Fig. 9.

Fig. 10.

Fig. 11.

Fig. 12.

Fig. 13.

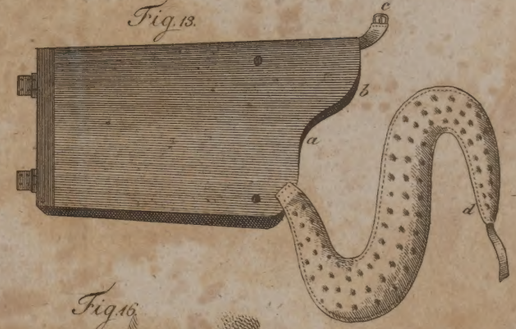

Fig. 14.

Fig. 15.

Fig. 16.



Fig. 14.a

nach Sauter u. Mayor.

Fig. 1.

Fig. 3.

Fig. 4.

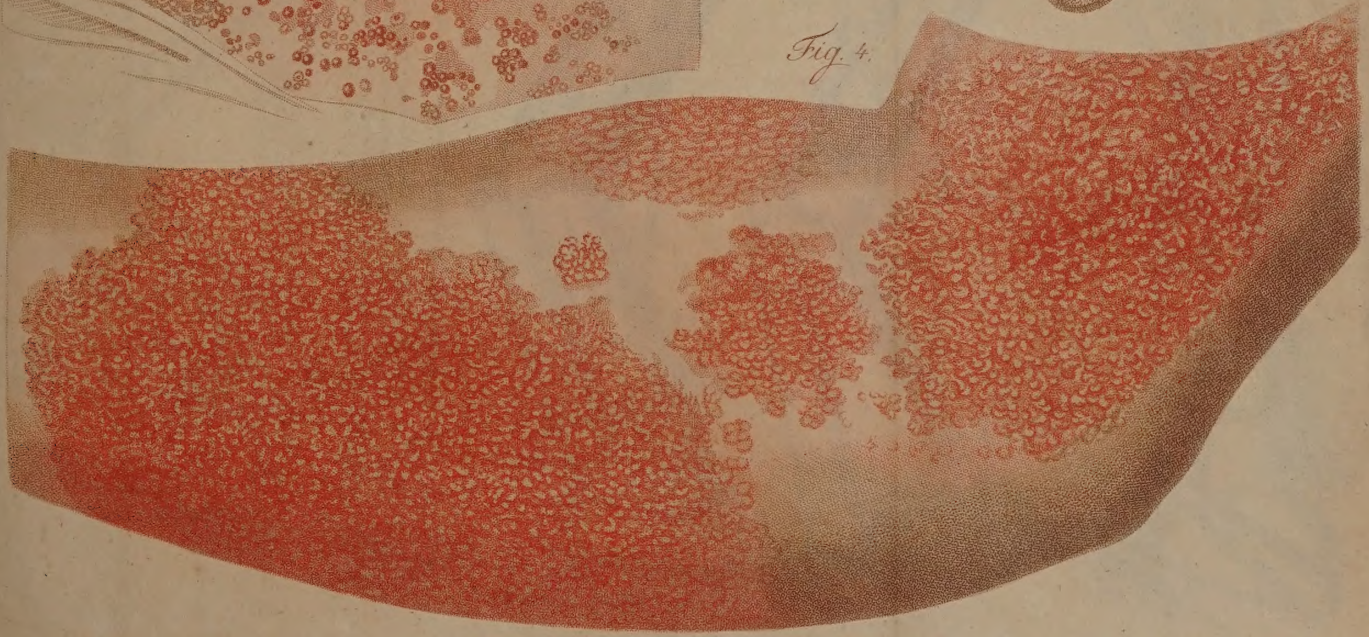

nach Batemann.

Fractura.

Taf. CLXXXVII

Fig. 1.

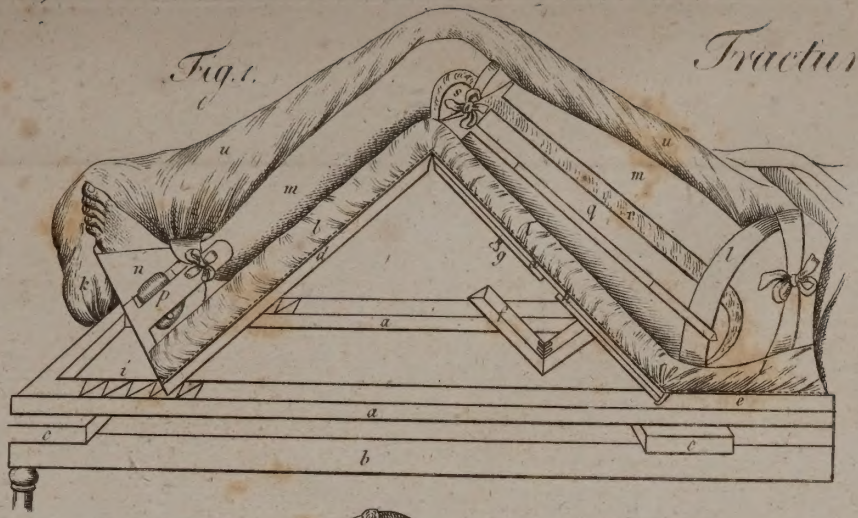

Fig. 2.

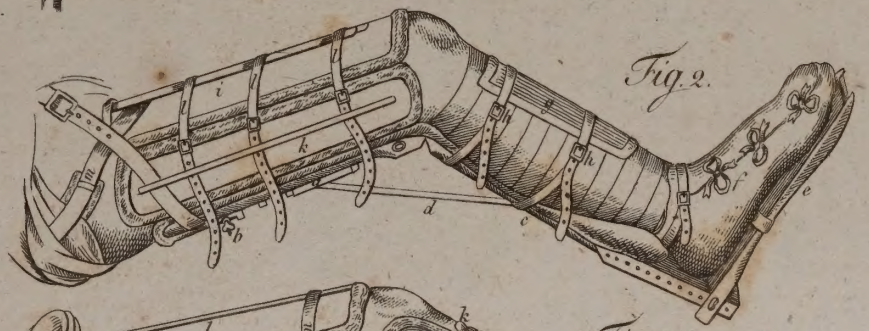

Fig. 3.

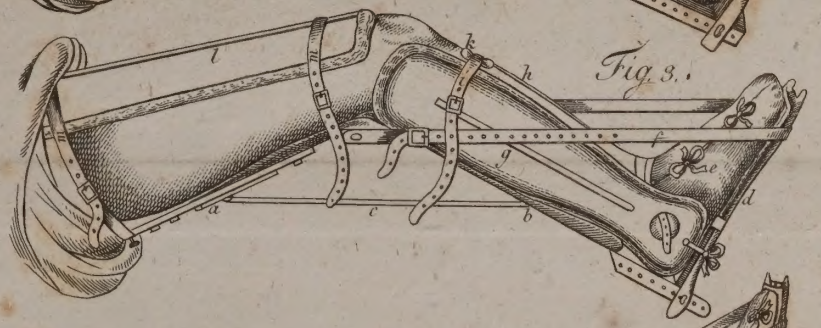

Fig. 5.

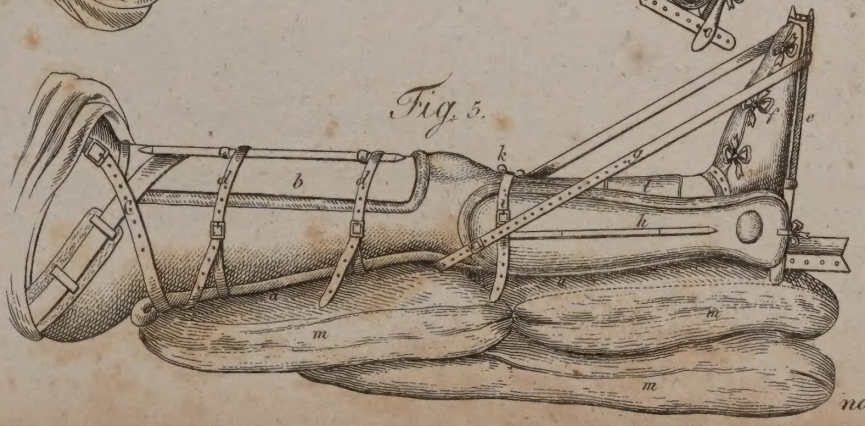

Fig. 4.

Fig. 6.

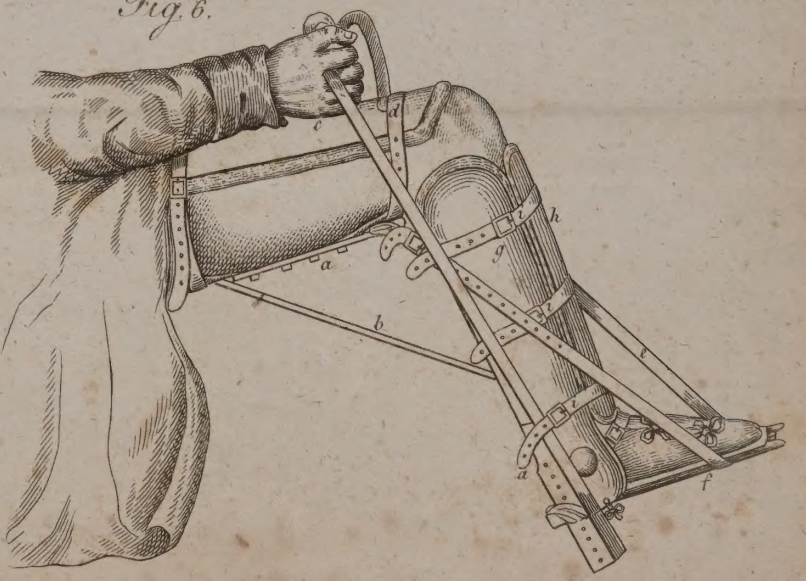

nach Amesbury.

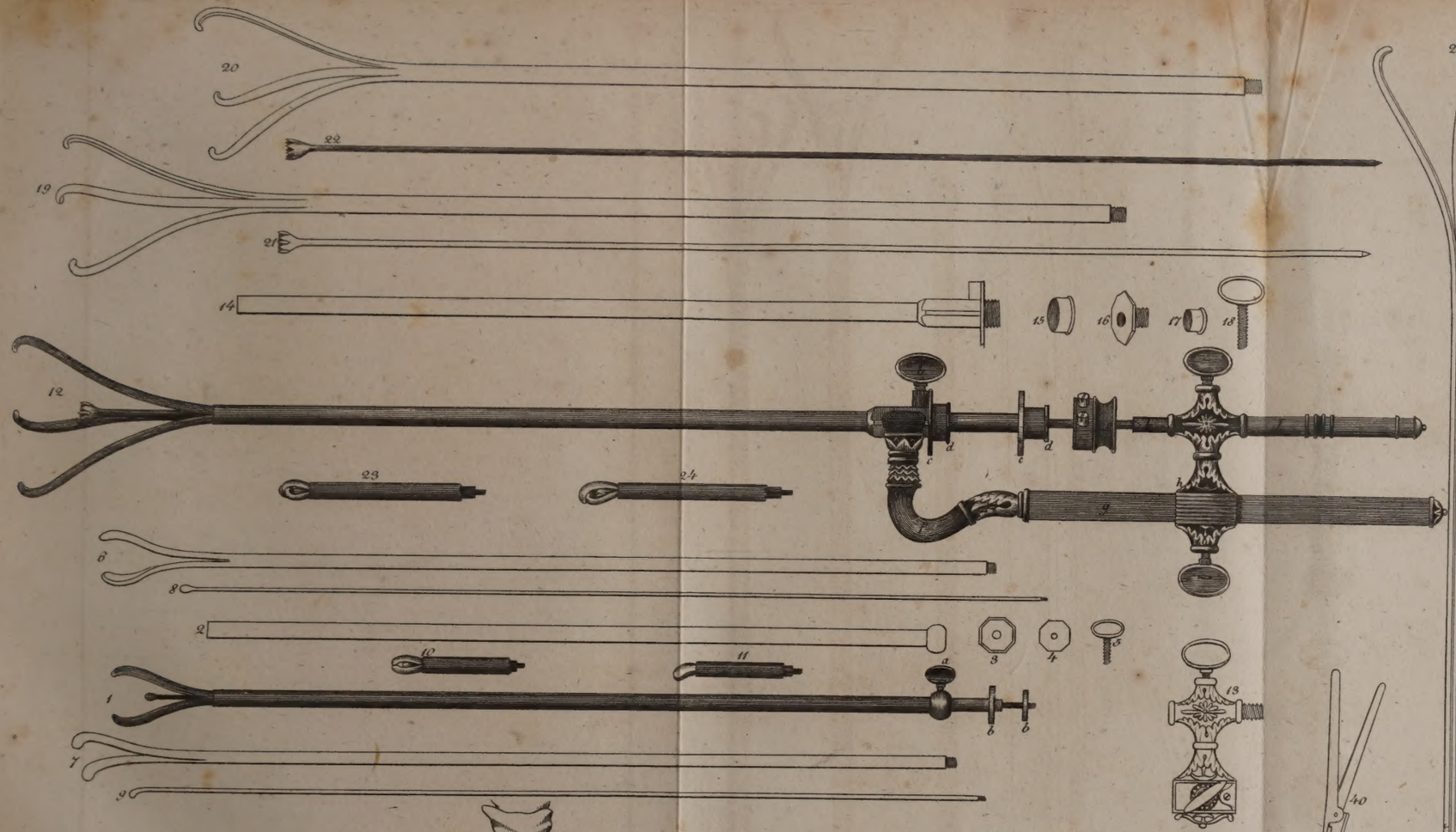
20
22
19
21
14
15
16
17
18
12
c
d
c
d
23
24
h
g
6
8
2
10
11
3
4
5
a
1
b
b
13
7
9

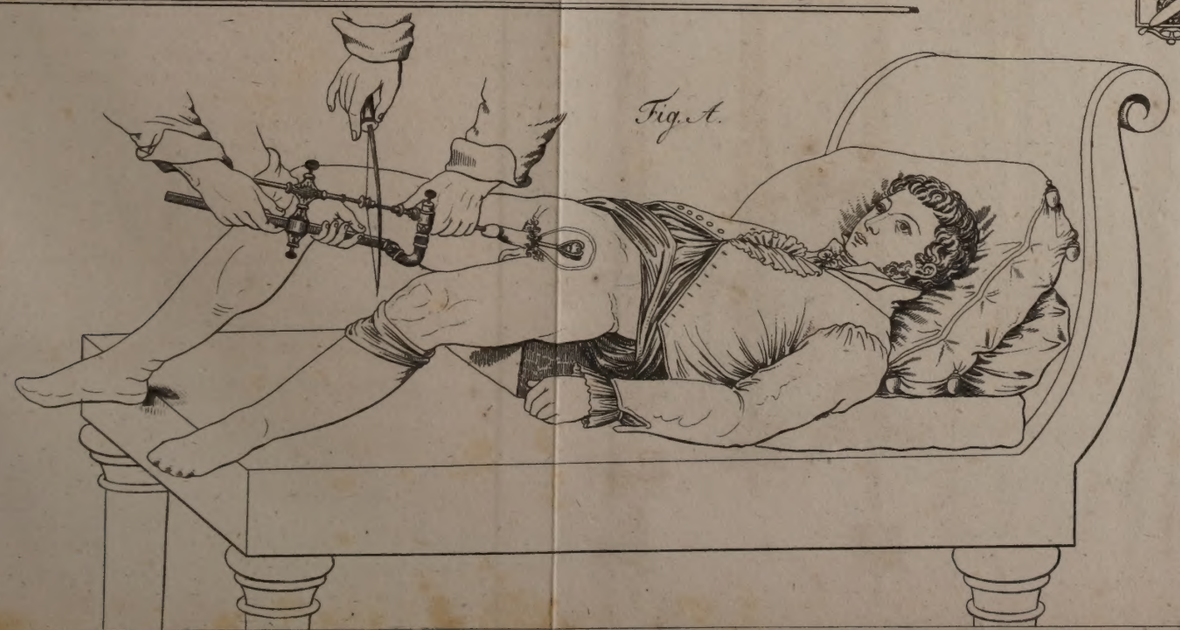
Fig. A.


26
27
28
25
29
30
31
32
35
37
38
36
34
40
39
33

Catàracta.

Taf CXC. CXCI. CXCII.

Fig. 1.

Fig. 2.

Fig. 3.

Fig. 4.

Fig. 5.

Fig. 6.

Fig. 7.

Fig. 8.

Fig. 9.

Fig. 10.

Fig. 11.

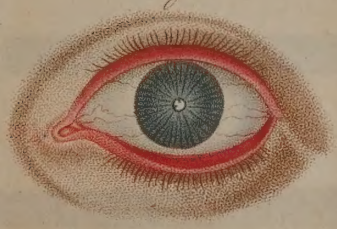

Fig. 12.

Fig. 13.

Fig. 14.

Fig. 16.

Fig. 15.

nach Guthrie, Travers, Beer u. Demours.

Pupilla artificialis.


Fig. 1.

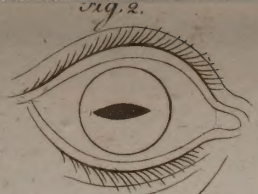
Fig. 2.

Fig. 3.

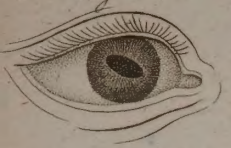
Fig. 4.

Fig. 5.

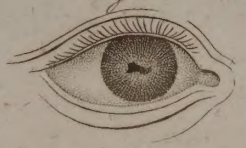
Fig. 6.

A.

Fig. 13.


Fig. 14.

Fig. 15.

Fig. 16.

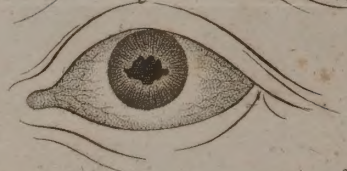
Fig. 17.

Fig. 7.

Fig. 8.

Fig. 9.

Fig. 10.

Fig. 12.

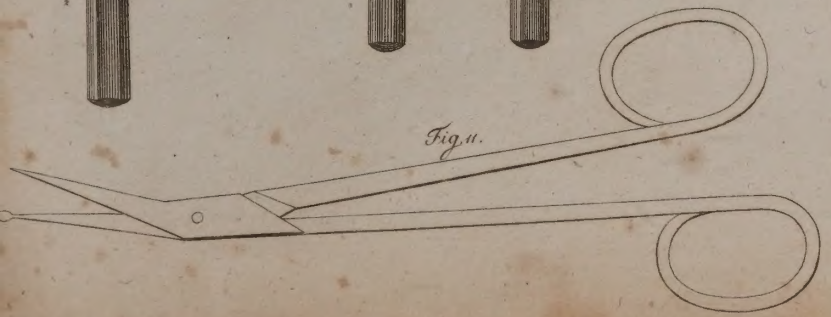
Fig. 11.

Fig. 19.


Fig. 21.


Fig. 18.

Fig. 22.

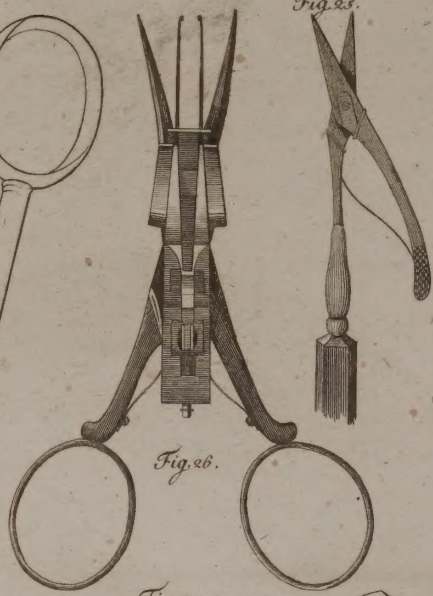
Fig. 26.

Fig. 25.


Fig. 23.

Fig. 24.

Fig. 27.


Fig. 20.

Fungus medullaris oculi.

Fig. 1.

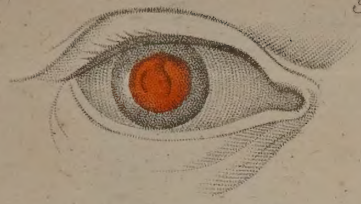

Fig. 4.

Fig. 5.

Fig. 6.

Fig. 7.

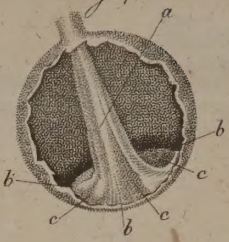

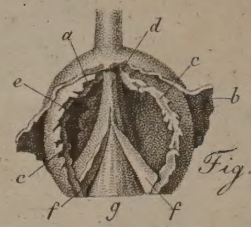

Fig. 8.

Fig. 2.

Fig. 3.

nach Panizza.

Fig. 1. *Maxillae exstirpatio.* Fig. 2. Taf. CXCV.

Fig. 3.

Fig. 4.

nach Cusack und Crampton.

Unguis Deformatio ejusque penetratio in carnem. Taf. CXCVI. CXCVII. CXCVIII.

Fig. 3.

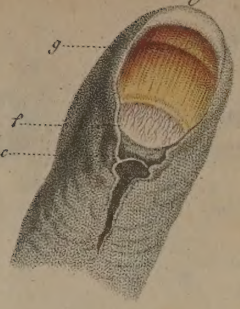

Fig. 2.

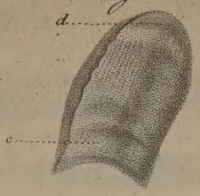

Fig. 1.

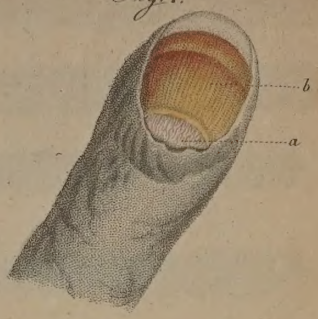

Fig. 6.

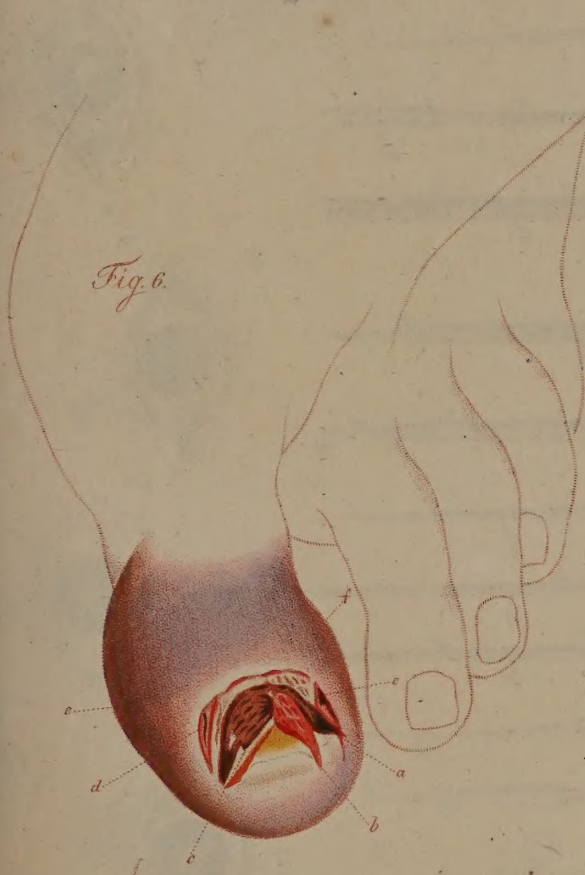

Fig. 4.

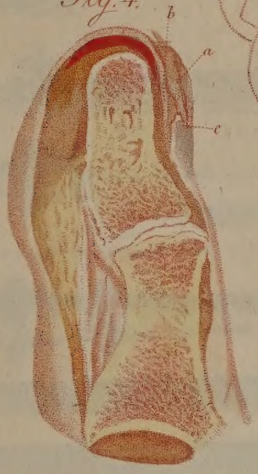

Fig. 5.

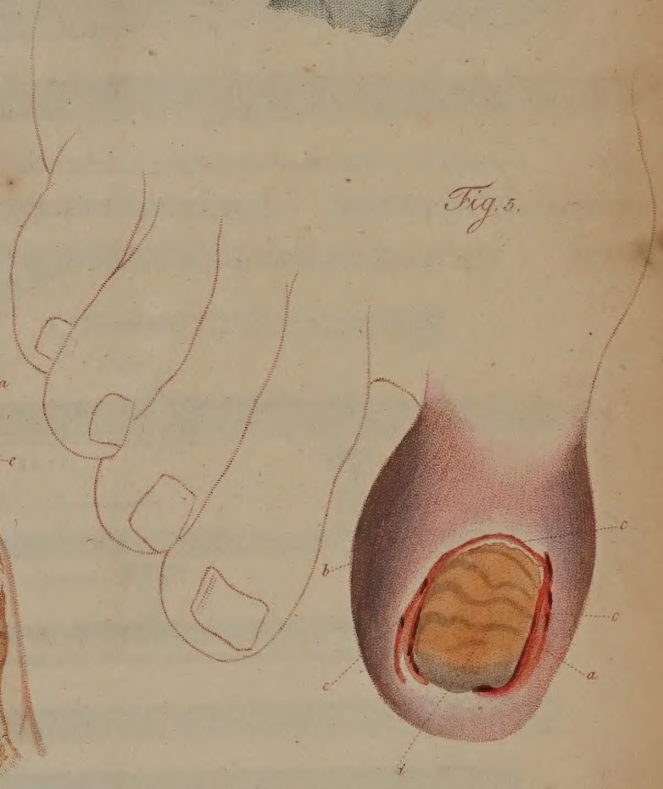

Fig. 7.

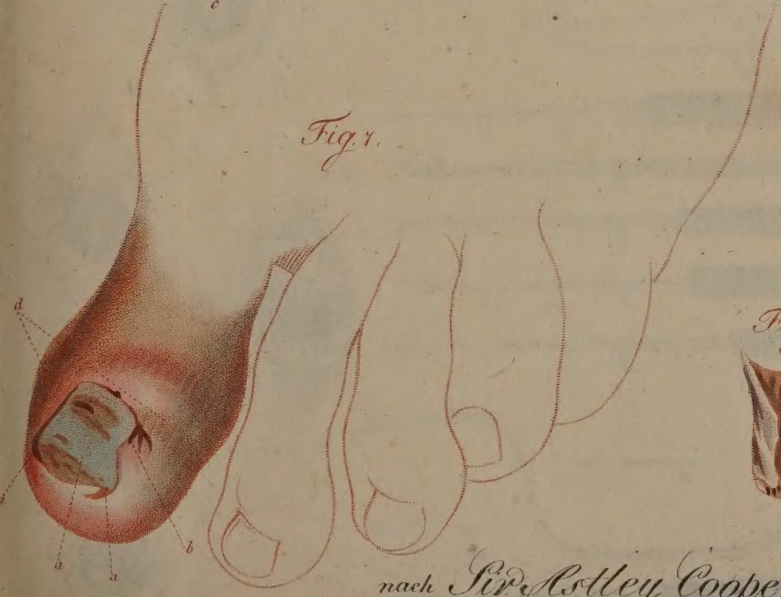

Fig. 9.

Fig. 8.

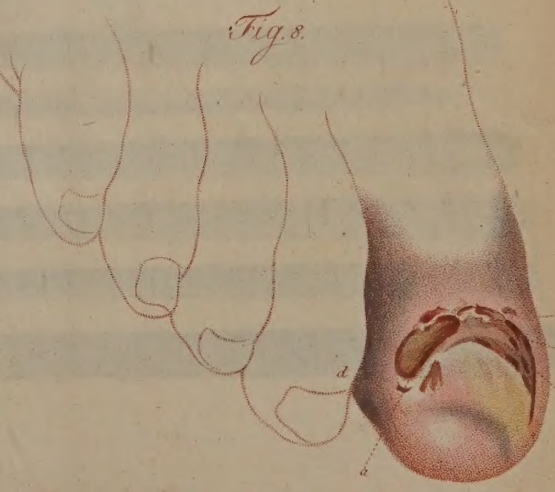

nach Sir Astley Cooper u. Royer-Collard.

Pupilla artificialis. B.



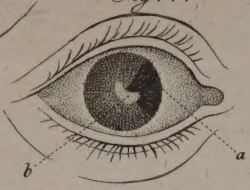



Tab. CXCIX.

Anus praeternaturalis.

C.

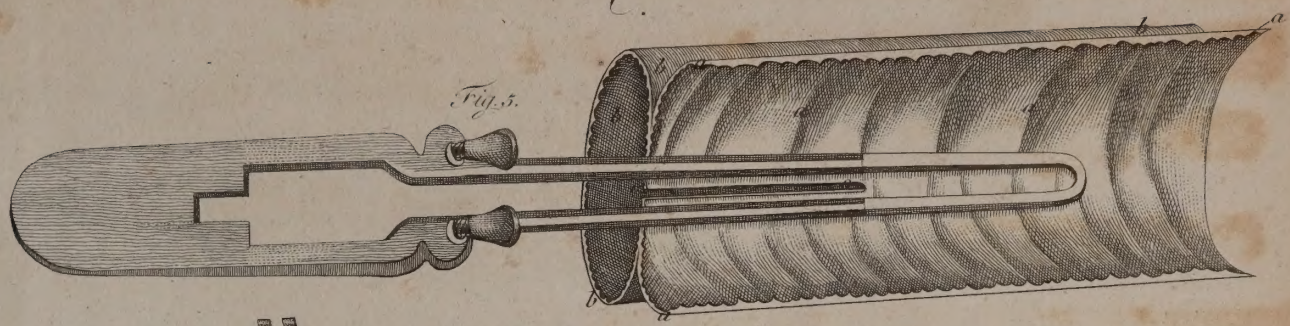

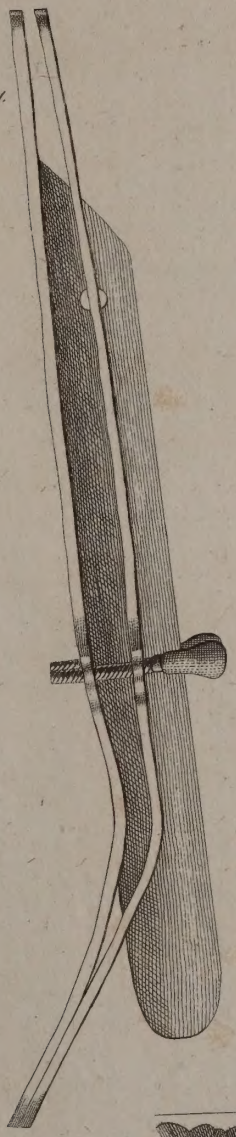



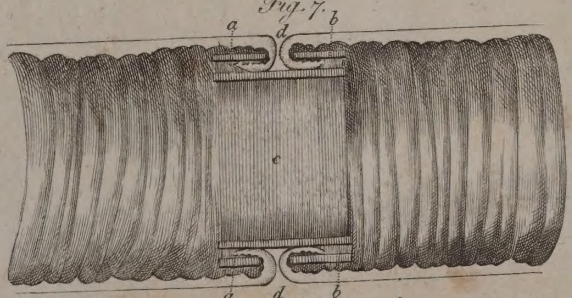

nach Reybard.

Colli uteri exstirpatio.



nach Canella und Hatin.

Taf. CXI.

Iridis affectiones.

A.

Tafeln CCII. CCIII. CCIV.

Fig. 1.

Fig. 2.

Fig. 3.

Fig. 4.

Fig. 5.

Fig. 6.

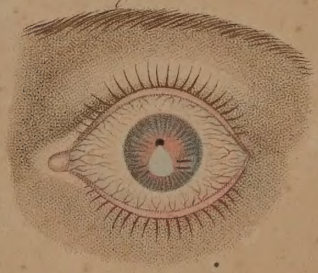

Fig. 7.

Fig. 8.

Fig. 9.

Fig. 10.

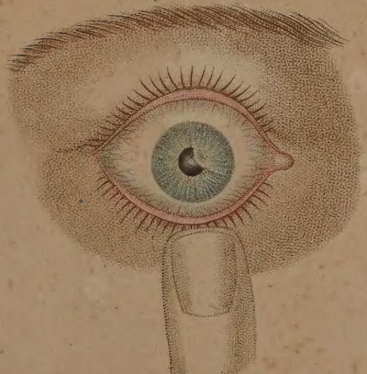

Fig. 11.

Fig. 12.

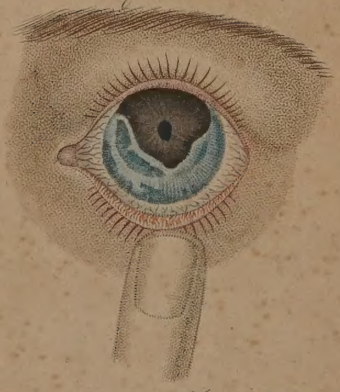

Unter Leitung des D.r Ammon gezeichnet von Hellenhausen in Dresden.

Fig. 1.

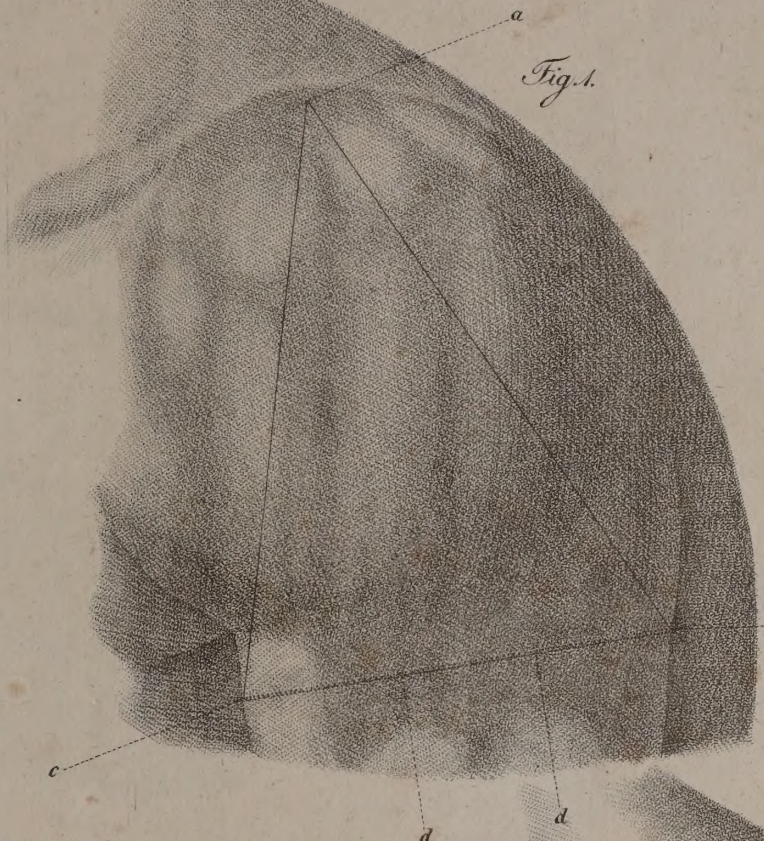

Fig. 2.

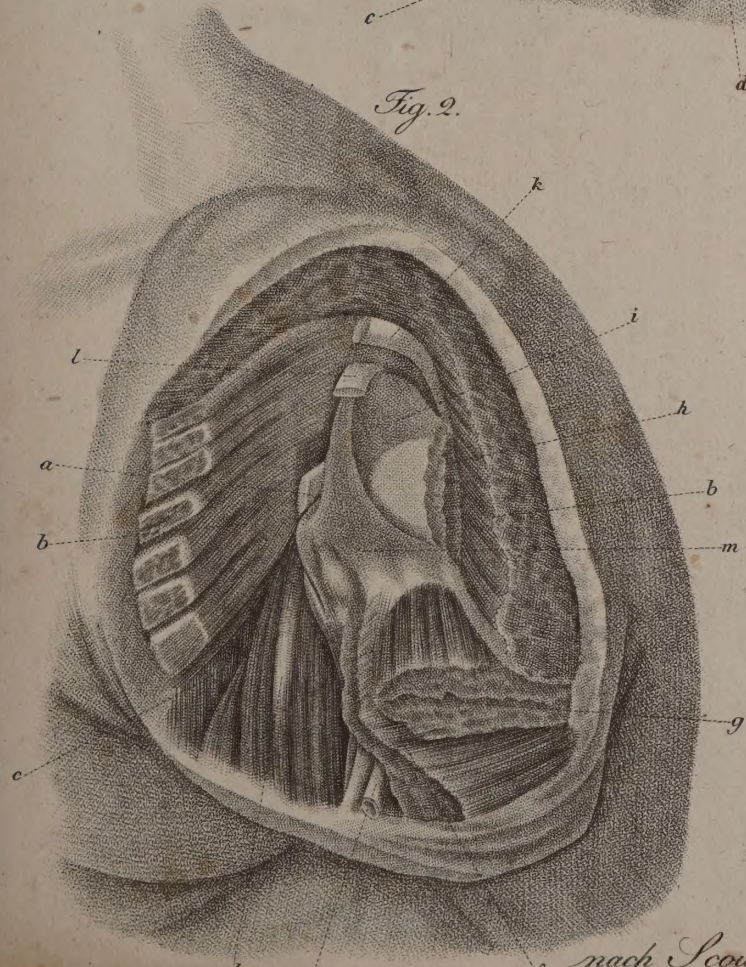

Fig. 3.

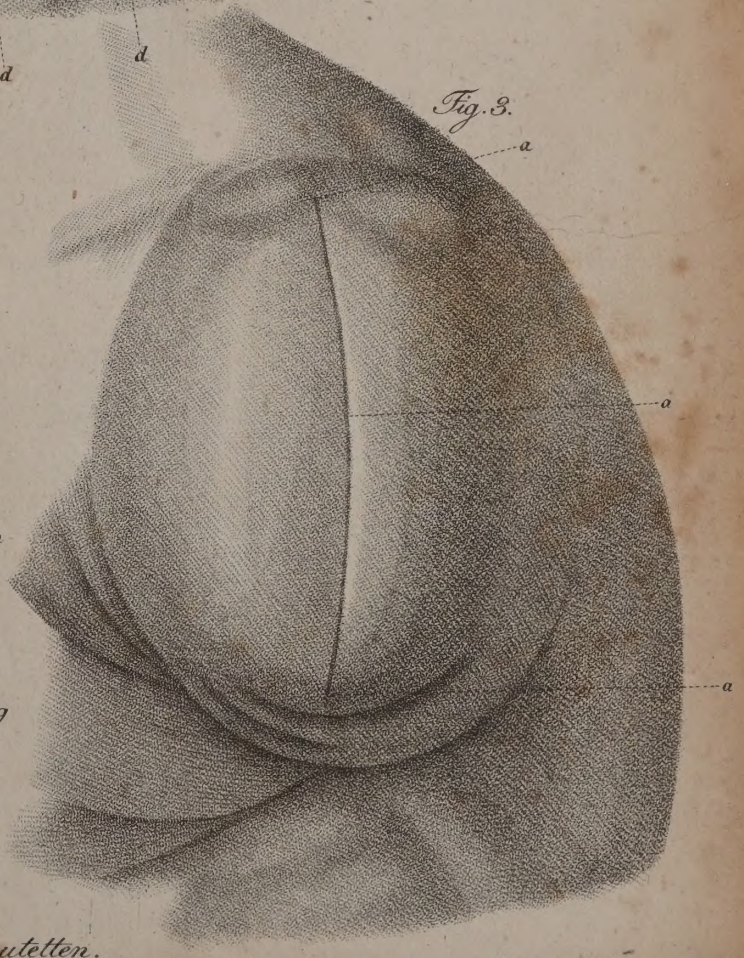

nach Scoutetten.

Fig. 9.

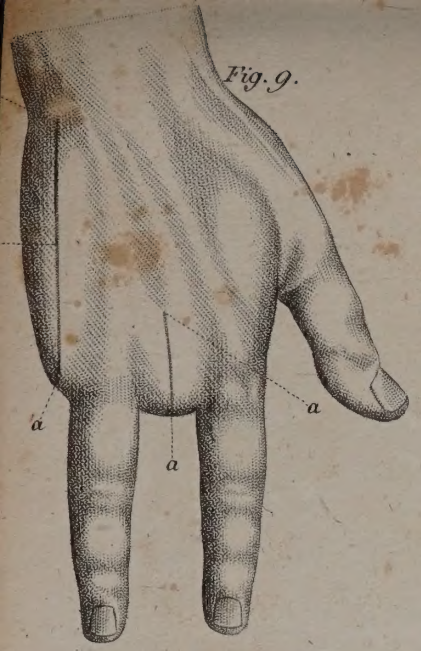

Fig. 8.

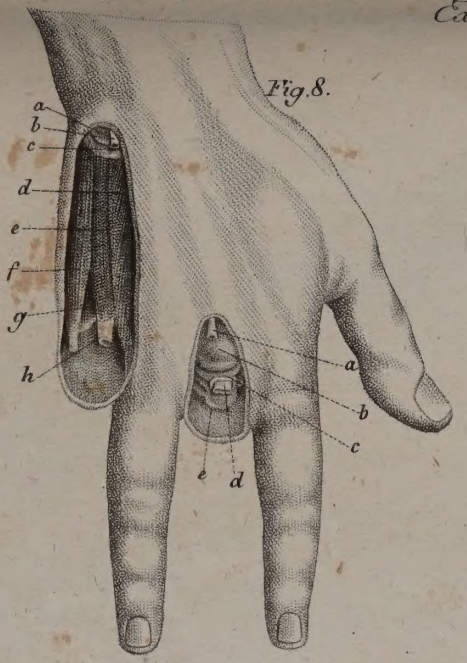

Fig. 7.

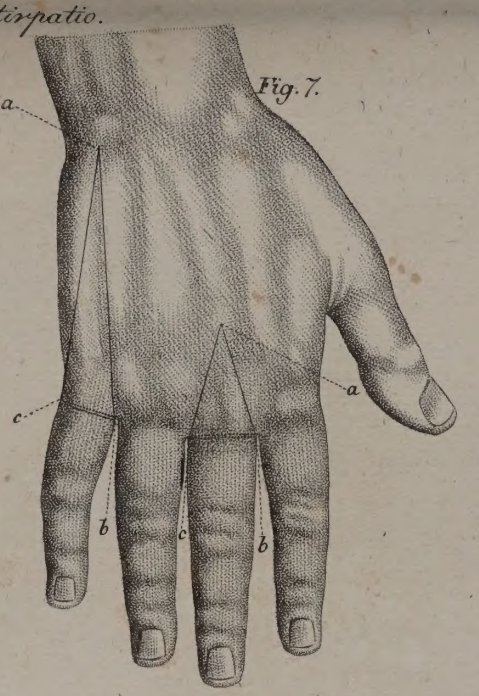

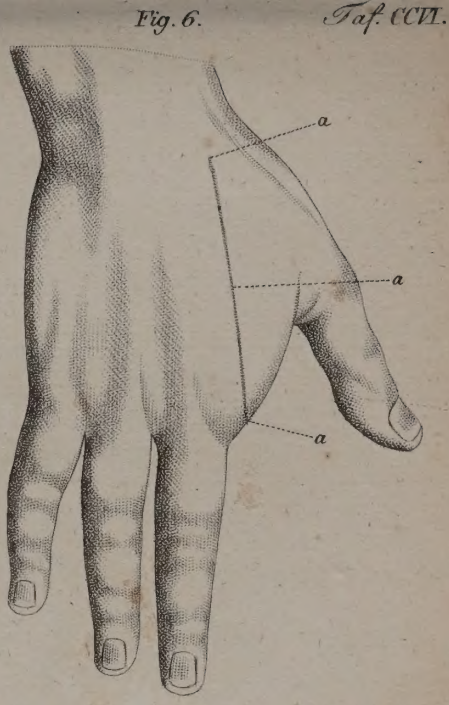

Fig. 5.

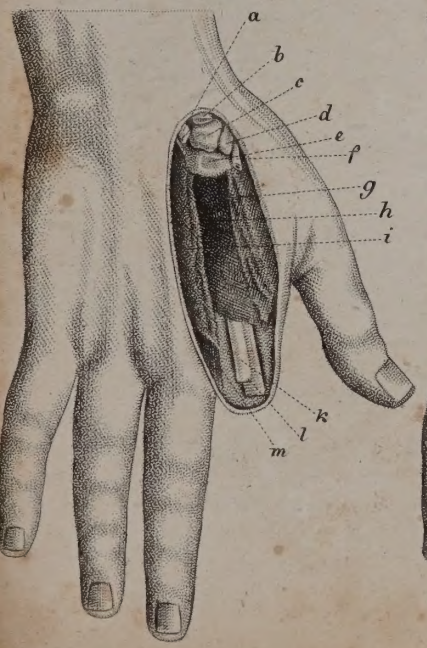

Fig. 4.

Fig. 3.

Fig. 2.

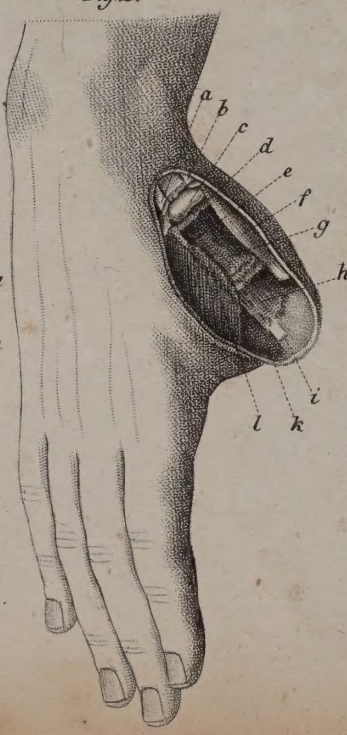

Fig. 1.

nach Scoutetten.

nach Sir Astley Cooper.

Fistula lacrymalis. Taf. CCVIII. CCIX. CCX.

Fig. 1.

Fig. 2.

Fig. 3.

Fig. 4.

Fig. 5.

Fig. 6.

Fig. 7.

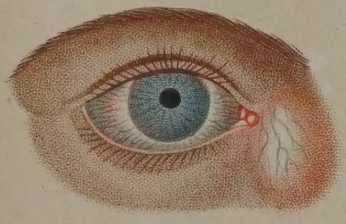

Fig. 8.

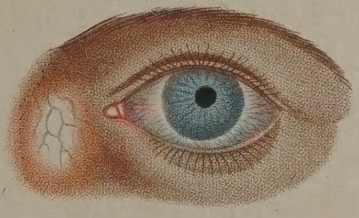

Fig. 9.

Unter Leitung des Dr. v. Ammon gezeichnet von Hettenhausen.

Fig. 1.

Fig. 2.

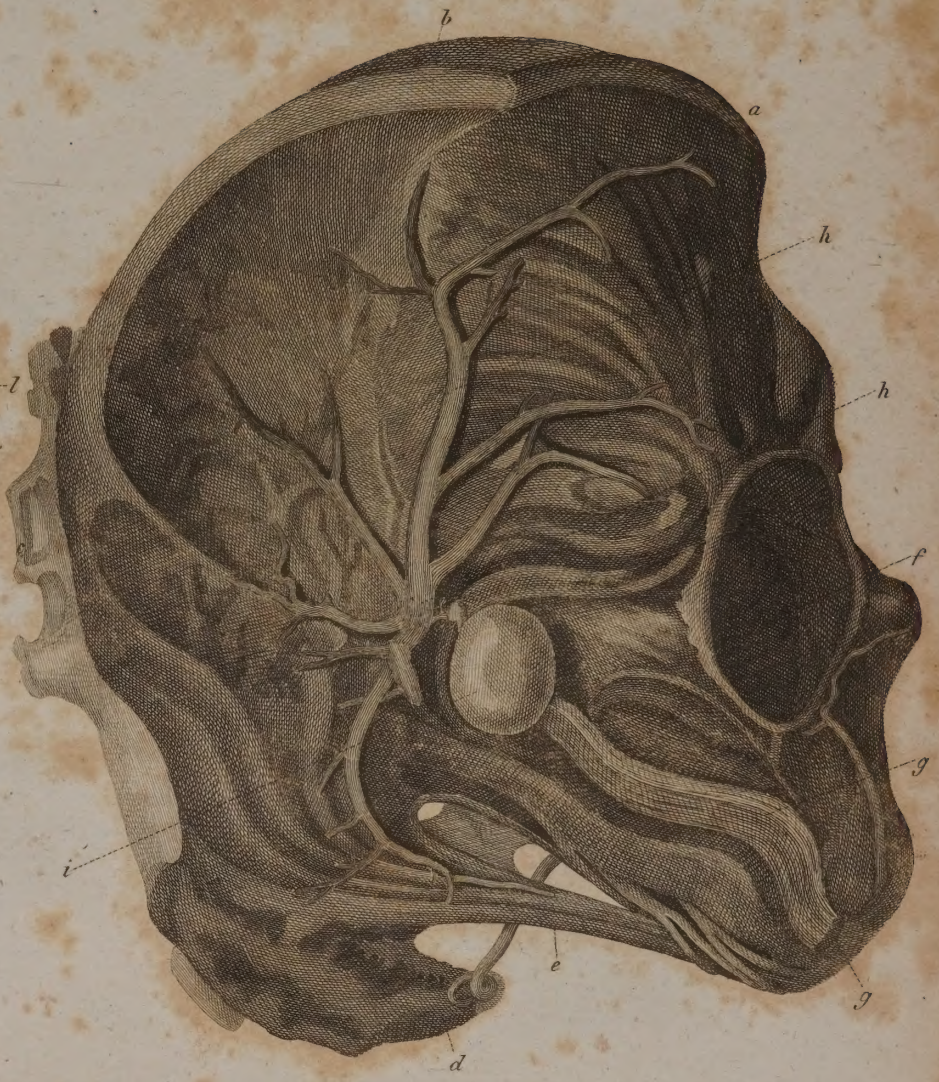

nach Sir Astley Cooper.

Fig. 1.

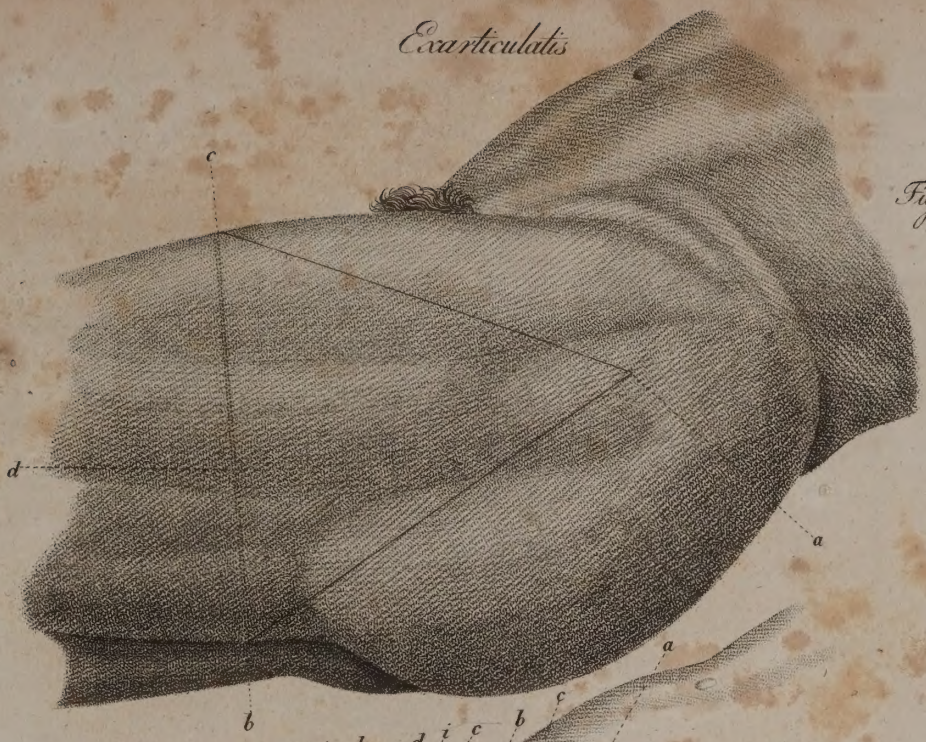

Fig. 2.

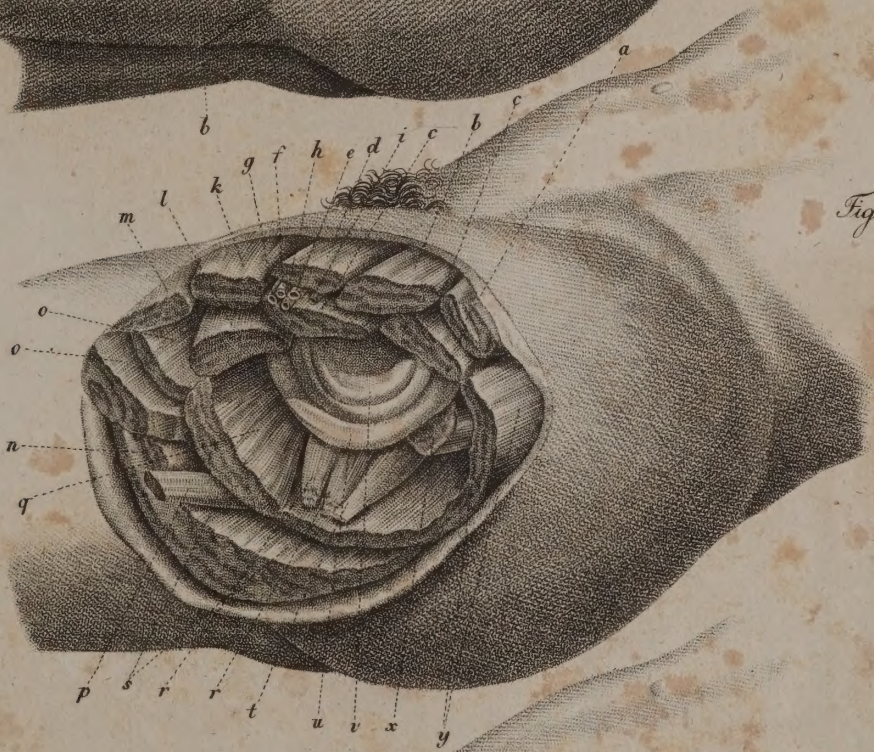

Fig. 3.

nach Scoutetten.

Fig. 1.

Fig. 2.

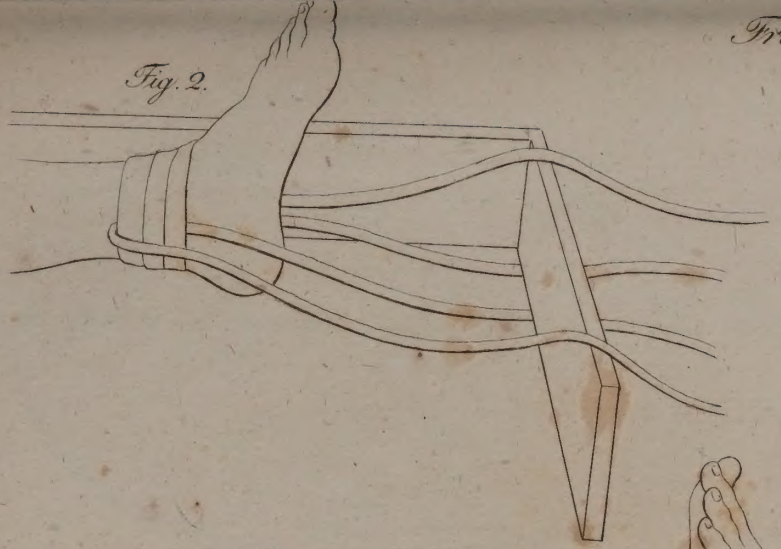

Fig. 3.

Fig. 4.

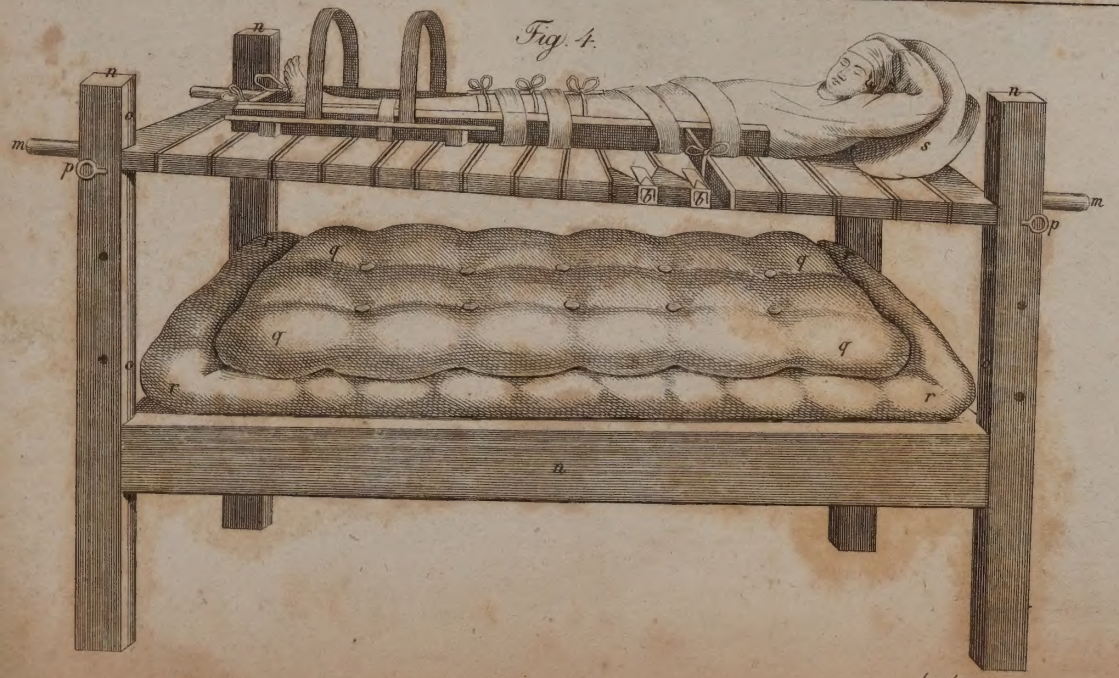

nach Josse.

Fig. 1.

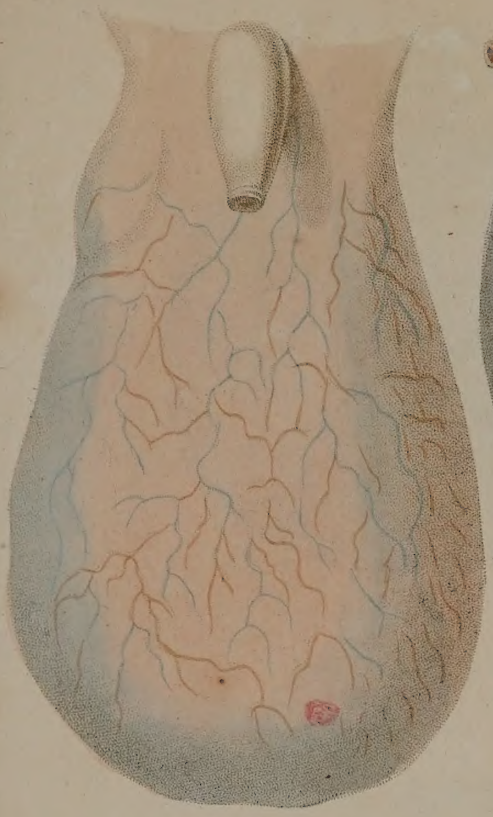

Fig. 3.

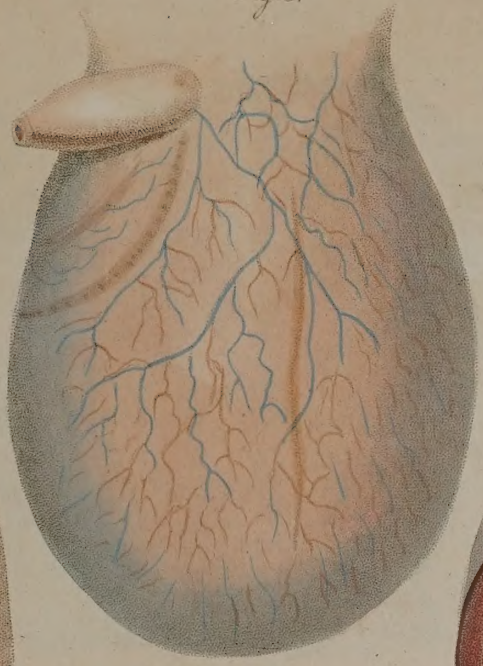

Fig. 5.

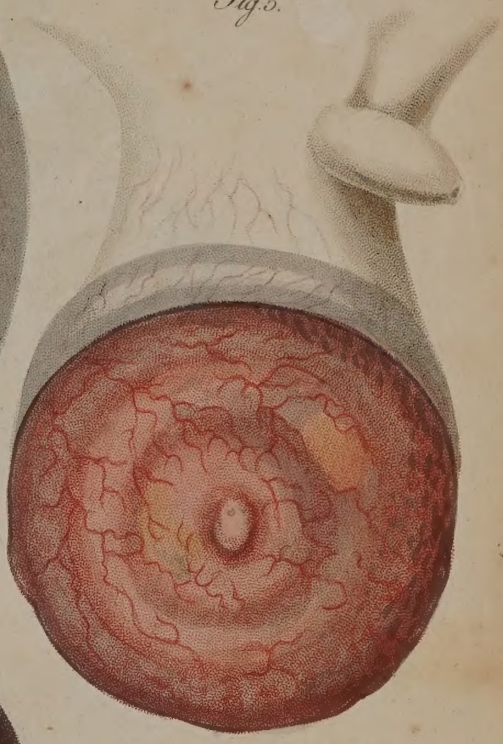

Fig. 4.



Fig. 2.

Fig. 6.

Unter Leitung des Dr v. Ammon gezeichnet von Hettenhausen.

Fig. 1.

Fig. 2.

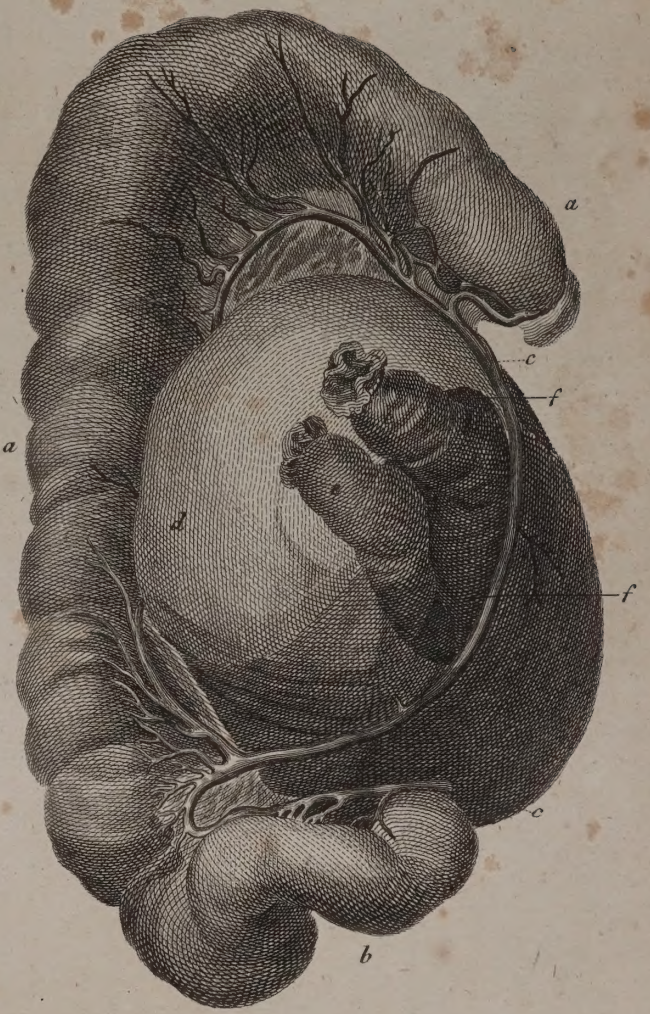

Bilgehold sc. 1819.

Rhinoplastice.

Fig. 4.

Fig. 5.



Fig. 6.

Fig. 1.



Fig. 2.

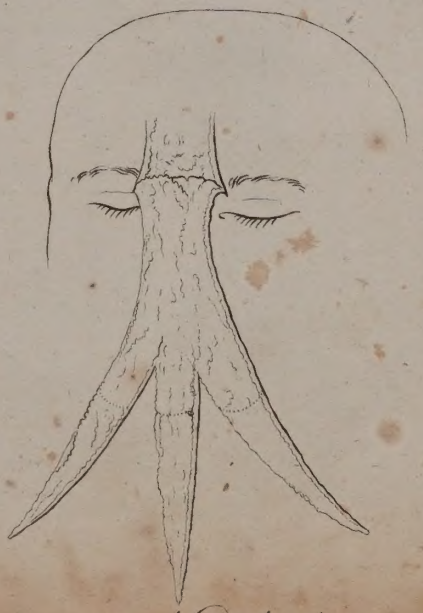

Fig. 3.

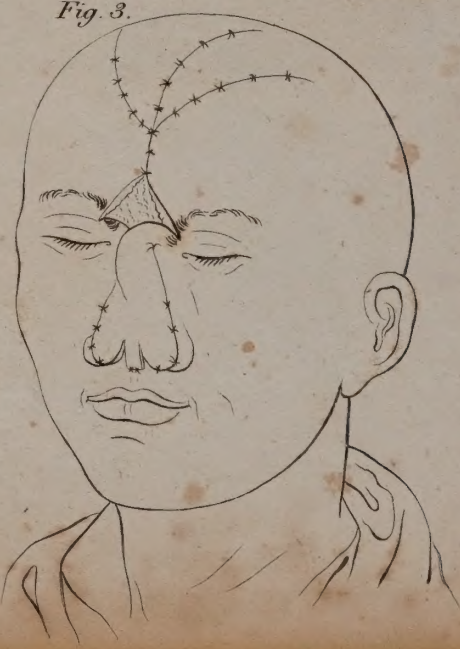

nach Delpech.

Exstirpatio.

Fig. 1.

Fig. 2.

Fig. 3.

Fig. 4.

Fig. 5.

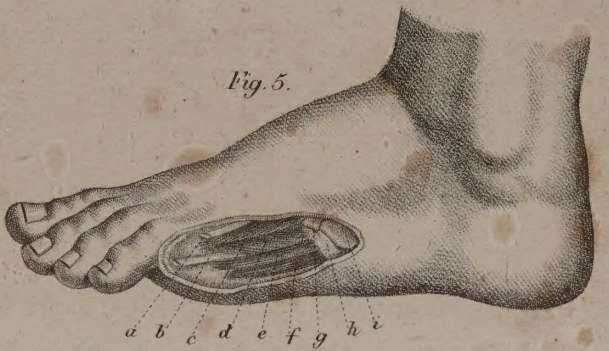

Fig. 6.

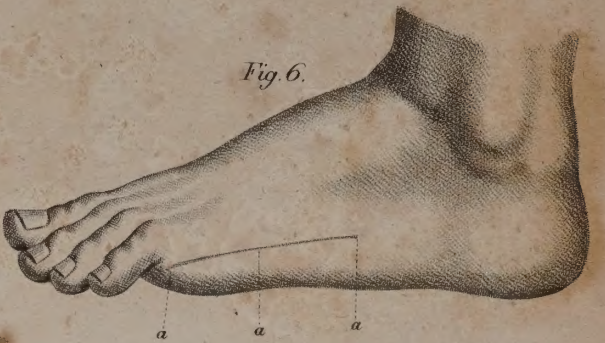

Fig. 7.

Fig. 8.

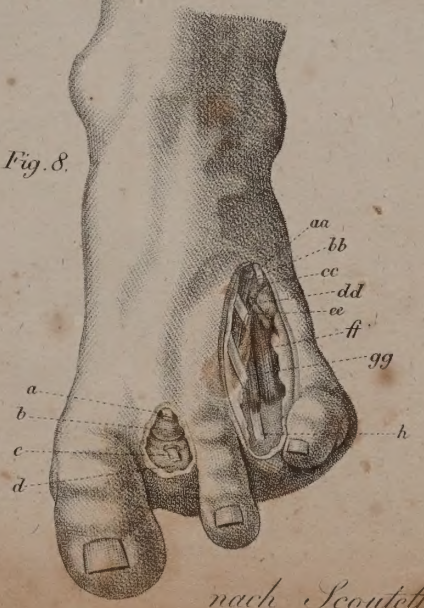

Fig. 9.

nach Scoutetten.

Fig. 1.

Strophulus.

Taf. CCXX, CCXXI, CCXXII.

Fig. 2.

Fig. 3.

Fig. 4.

Fig. 4.
a
b
c
d
e
a
b
a

Fig. 5.
a
c
b
a

Fig. 3.
a
a
a
d
l
l
f
d
i
f
e
g
b
e
b
h
k
c
e
c

Fig. 1.
c
b
a
f
d
g
b
c
e
a
e
c
b
a

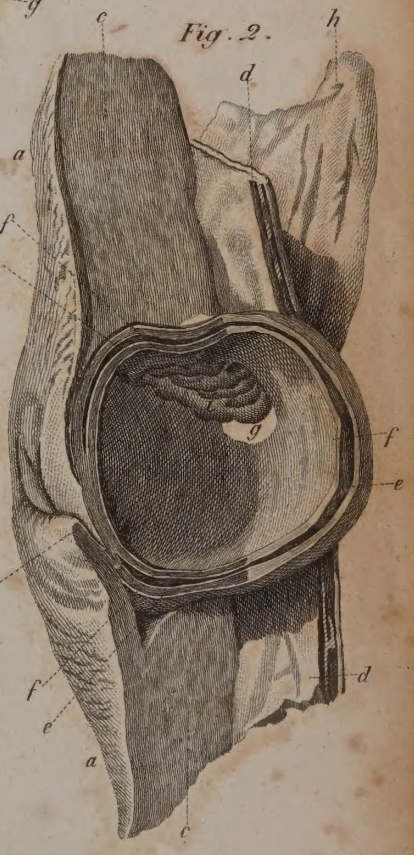
Fig. 2.
c
h
d
a
f
e
g
f
e
b
f
e
d
a
c

Fig. 1.

Fig. 3.

Fig. 2.

Fig. 4.

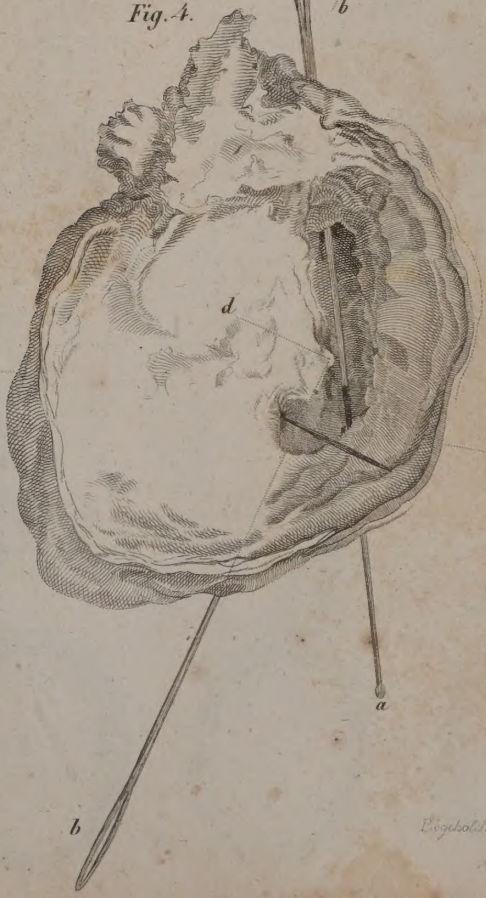

Nach Wardrop.

Engelsold. n. Sc.

Labium leporinum

A.

Fig. 1.



Fig. 7.

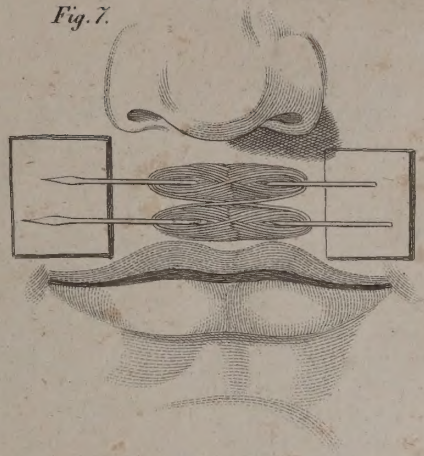

Fig. 5.

Fig. 6.

Fig. 4.



Fig. 3.

Fig. 2.

Fig. 9.

Fig. 8.

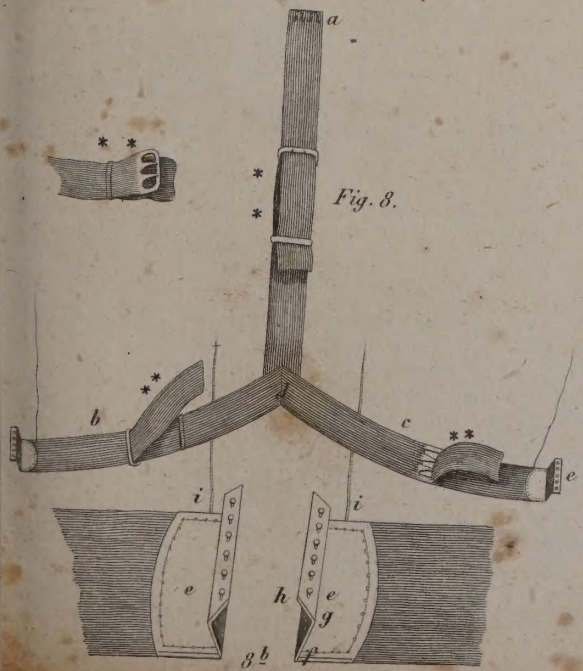

3b

Labium leporinum.

Fig. 1.

B.

Fig. 5.

Fig. 6.

Fig. 4.

Fig. 3.

Fig. 7.

Fig. 8.

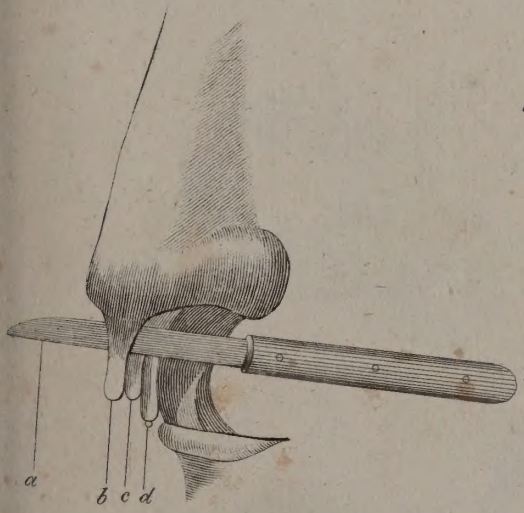

Fig. 10.

Fig. 9.

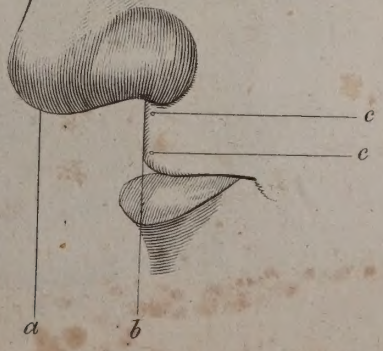

Fig. 1.

Fig. 7.

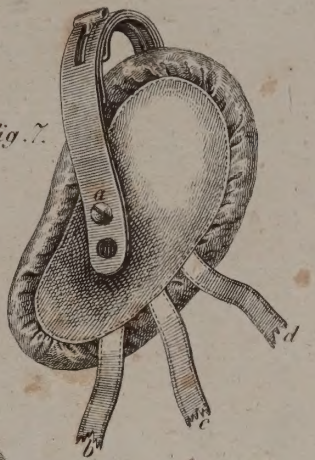

Fig. 3.

Fig. 4.

Fig. 5.

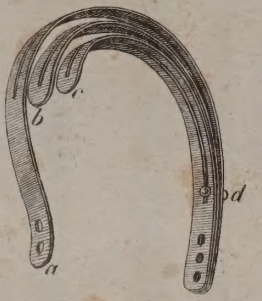

Fig. 6.

Fig. 2.

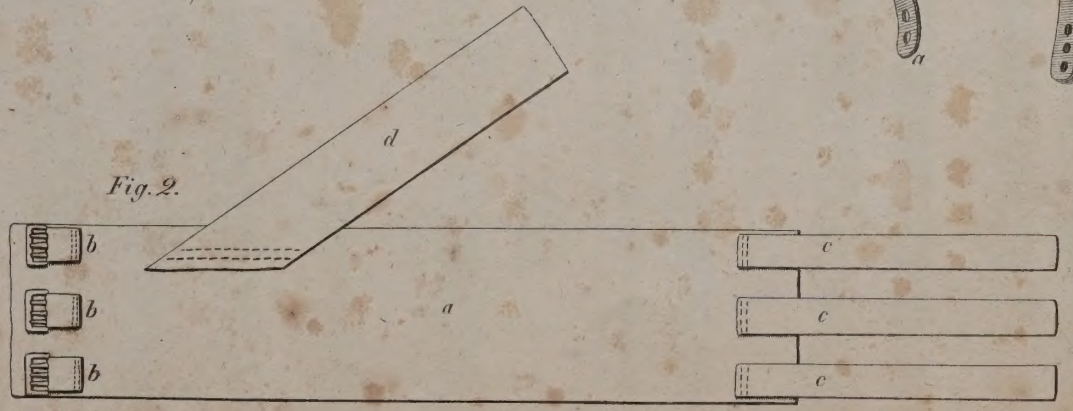

Fig. 8.

Nach Lasserre und Mélier.

Pupilla artificialis.

Fig. 1.

Fig. 2.

Fig. 4.

C.

Fig. 6.

Fig. 5.

Fig. 7.

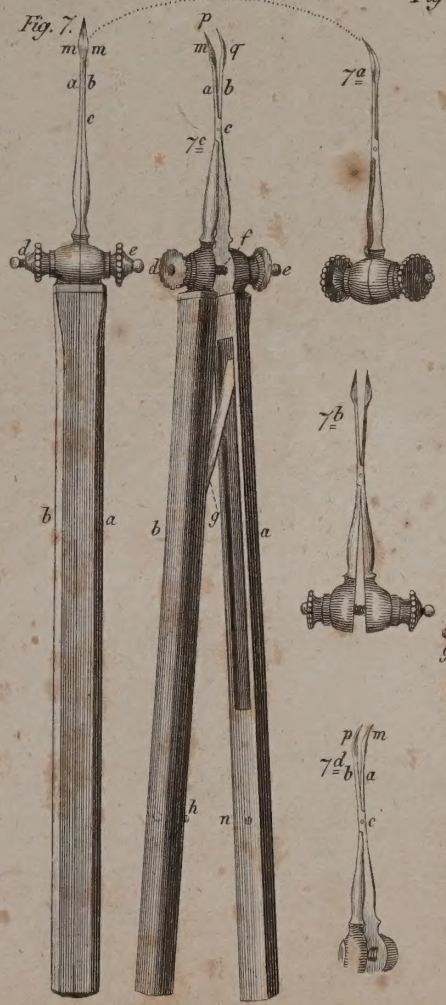

Fig. 8.

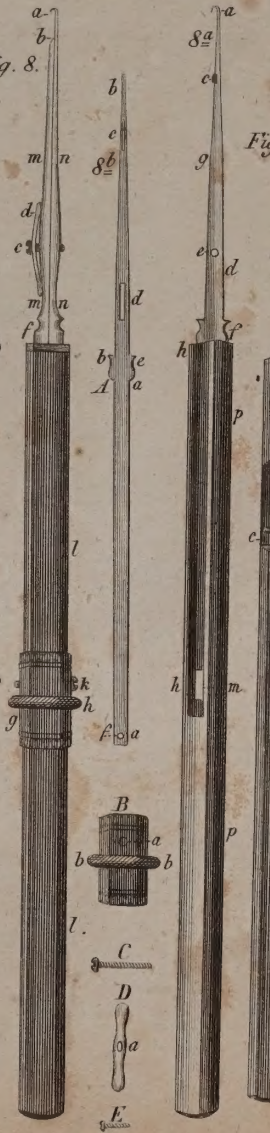

Fig. 9

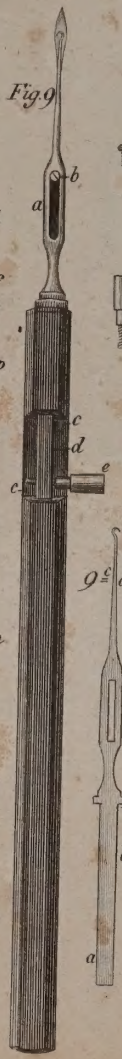

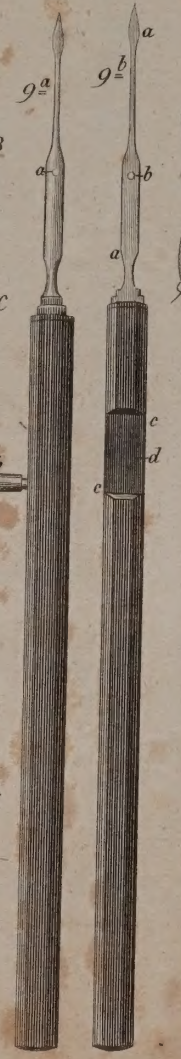

Fig. 10.

Fig. 11.

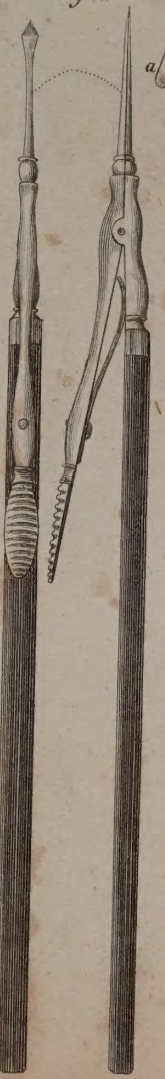

Fig. 12.



Fig. 13.



Fig. 13.*



Fig. 13.**

Fig. 13.***

Fig. 15.



Fig. 16.



Fig. 17.



Fig. 14.

Fig. 14.

Fig. 14.

Pupilla artificialis D.

Fig. 5.

Fig. 6.

Fig. 9.

Fig. 10.


Fig. 1.

Fig. 2.



Fig. 3.



Fig. 4.

Fig. 7.

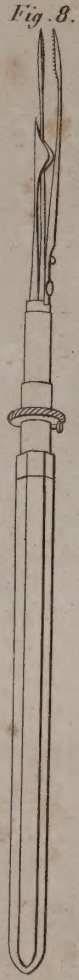
Fig. 8.



Fig. 7.*




Fig. 12.

Fig. 11.

Fig. 13.

Fig. 15.

Fig. 16.

Fig. 13.


Fig. 14.

Fig. 17.

Fig. 13.

Fig. 16.


Fig. 18.

Fig. 19.

Fig. 20.


Fig. 21.

Fig. 21.

Fig. 21.

Fig. 22.

Fig. 22.

Fig. 22.

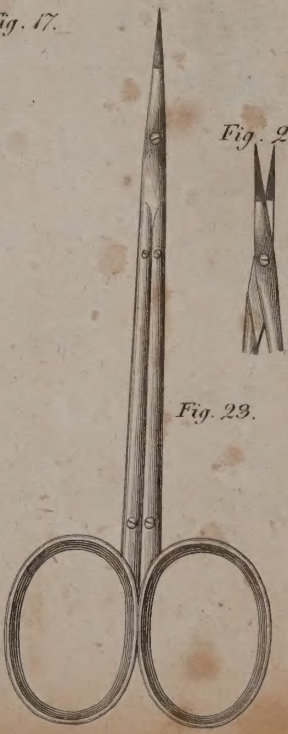
Fig. 23.

Fig. 24.

Fig. 25.

Fig. 26.

Fig. 27.

Fig. 28.

nach Cyfenoort und Menfert

Taf. CCXXX.



Fig. 10.

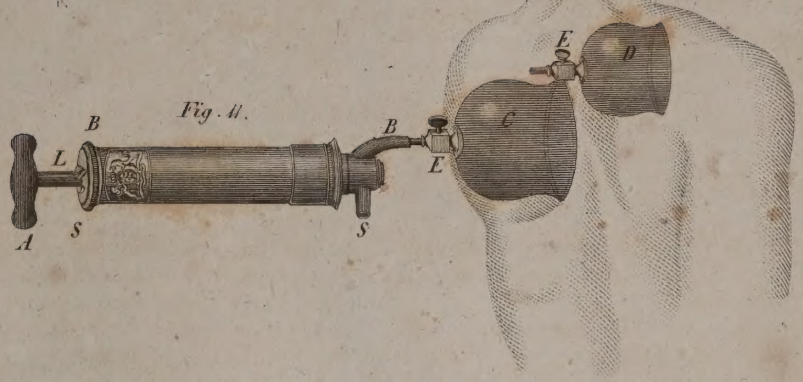

Fig. 11.



Fig. 12.

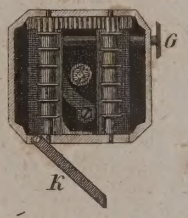

Fig. 13.

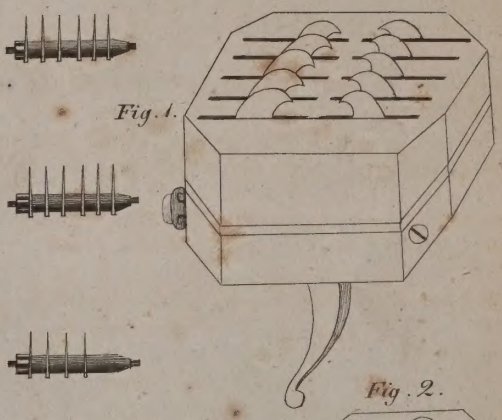

Fig. 1.

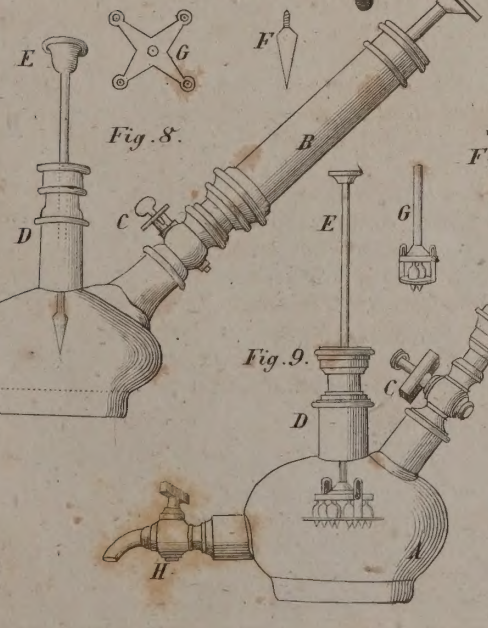

Fig. 8.

Fig. 9.

Fig. 3.

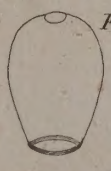

Fig. 4.

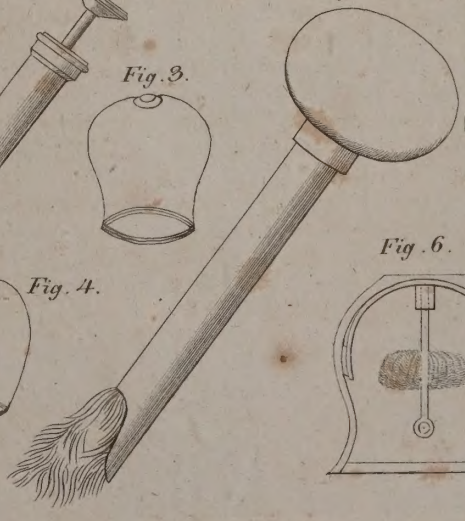

Fig. 5.

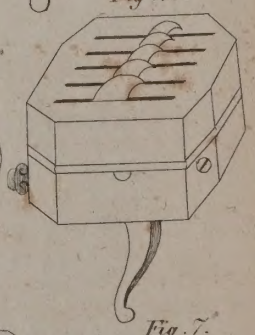

Fig. 2.

Fig. 6.

Fig. 7.

Fig. 2.

Fig. 4.

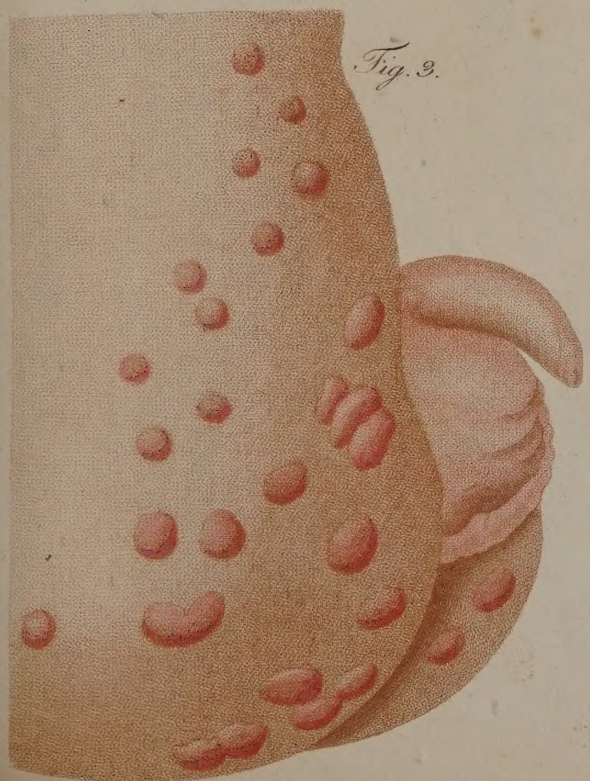

Fig. 3.

Fig. 1.

Fig. 2.

Fig. 3.



Fig. 4.

Fig. 5.

Fig. 6.

Fig. 7.

Fig. 8.

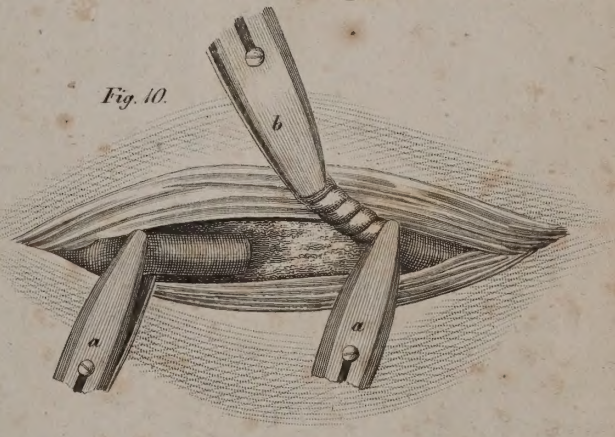

Fig. 10.

Fig. 9.

nach Thierry und Amussat.

Fractura colli ossis femoris.

nach J. A. Mayer und Physick.

Fig. 1.a
Fig. 1.b
Fig. 1.c
Fig. 1.d
Fig. 5.
Fig. 5.a
Fig. 5.b
Fig. 5.c
Fig. 6.
Fig. 10.
Fig. 9.
Fig. 9.a
Fig. 9.b
Fig. 9.c
Fig. 9.d
Fig. 8.a
Fig. 8.
Fig. 8.b
Fig. 7.
Fig. 7.a
Fig. 7.b
Fig. 3.
Fig. 4.
Fig. 2.

Fig. 2.

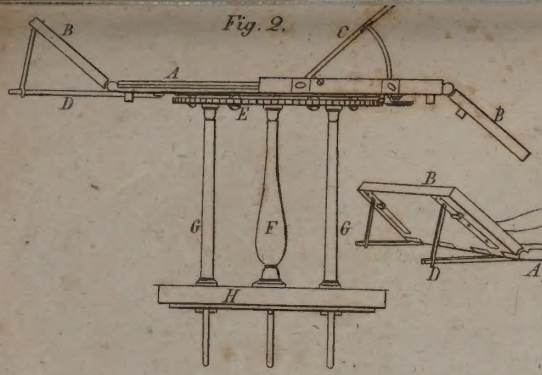

Fig. 1.

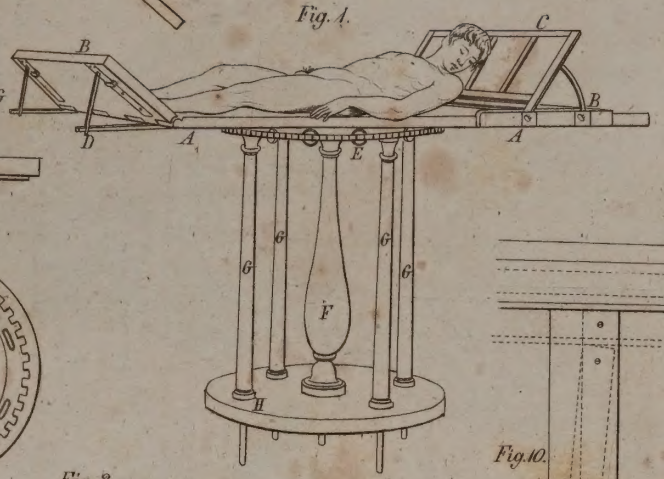

Fig. 4.

Fig. 3.

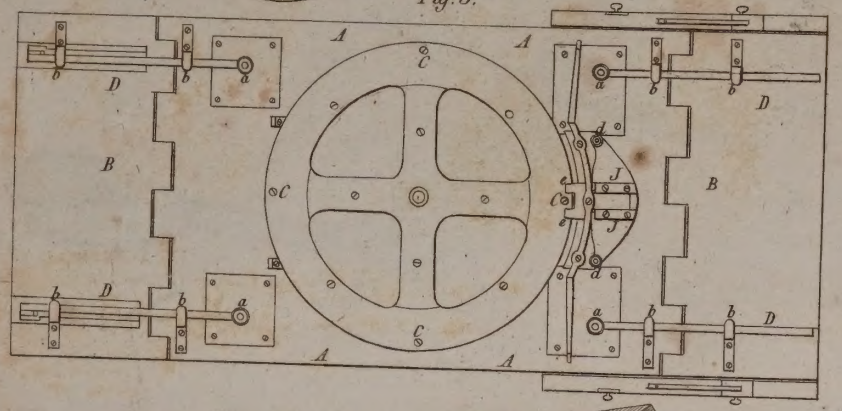

Fig. 10.

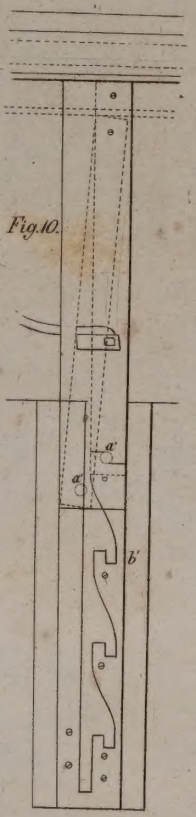

Fig. 5.



Fig. 11.

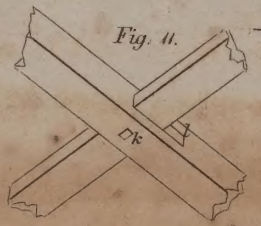

Fig. 7.

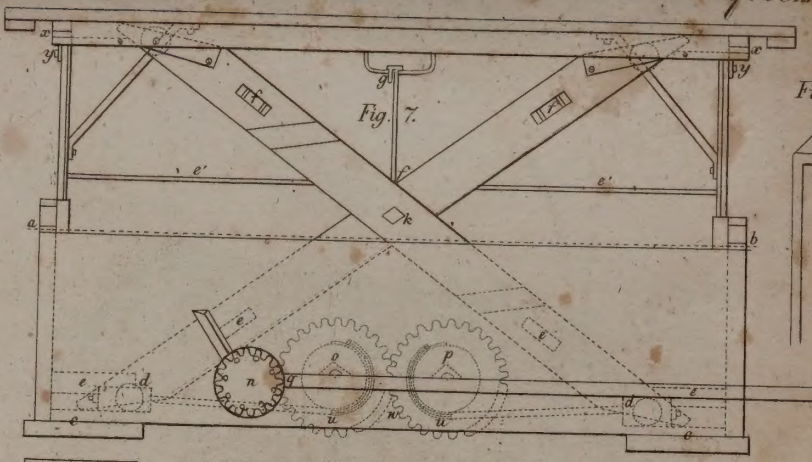

Fig. 12.

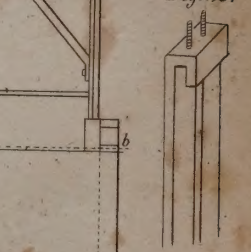

Fig. 6.

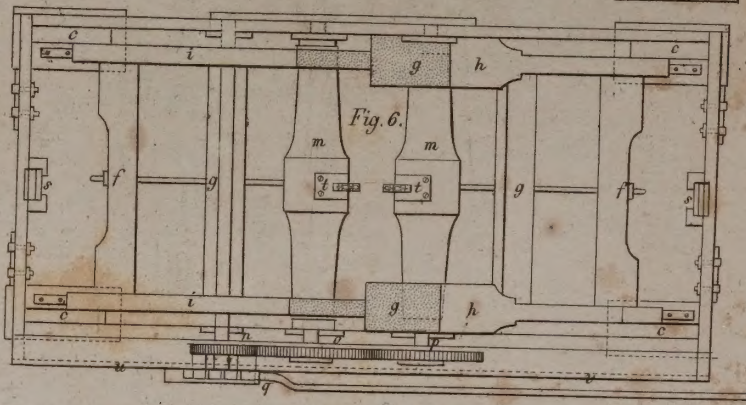

Fig. 8.

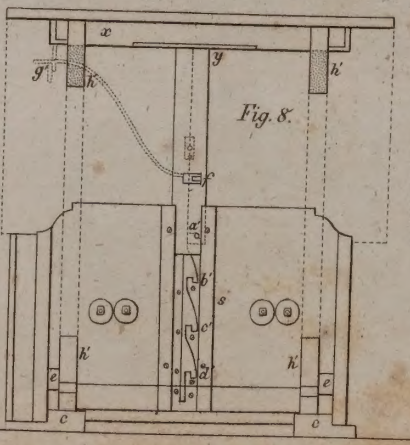

Fig. 9.

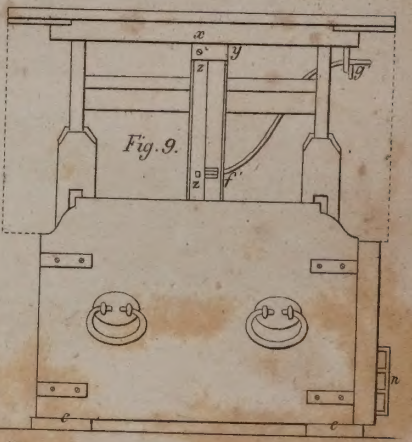

Fig. 13.



Hernia

Taf. CCXXXVII.

Fig. 1.

Fig. 2.

Fig. 4.

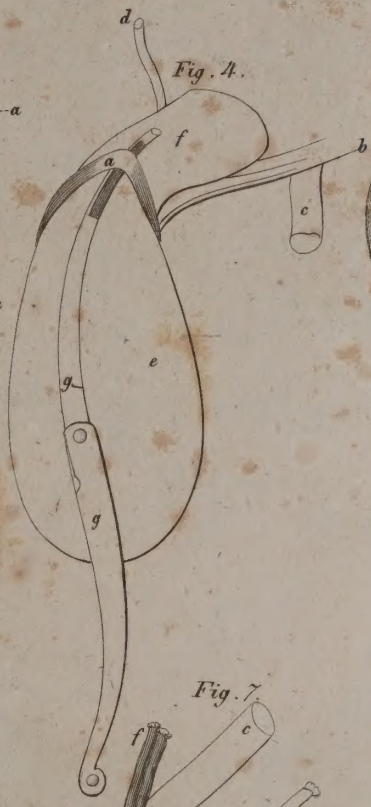

Fig. 3.

nach Sir Astley Cooper.

Fig. 5.

Fig. 7.

Fig. 6.

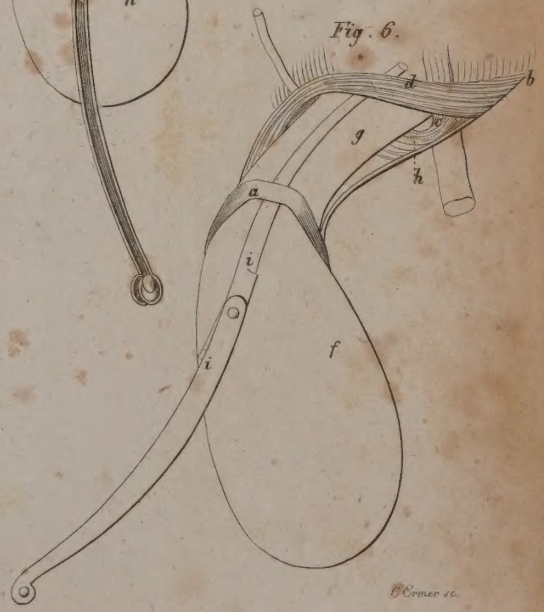

B. Ermer sc.

Fig. 1.

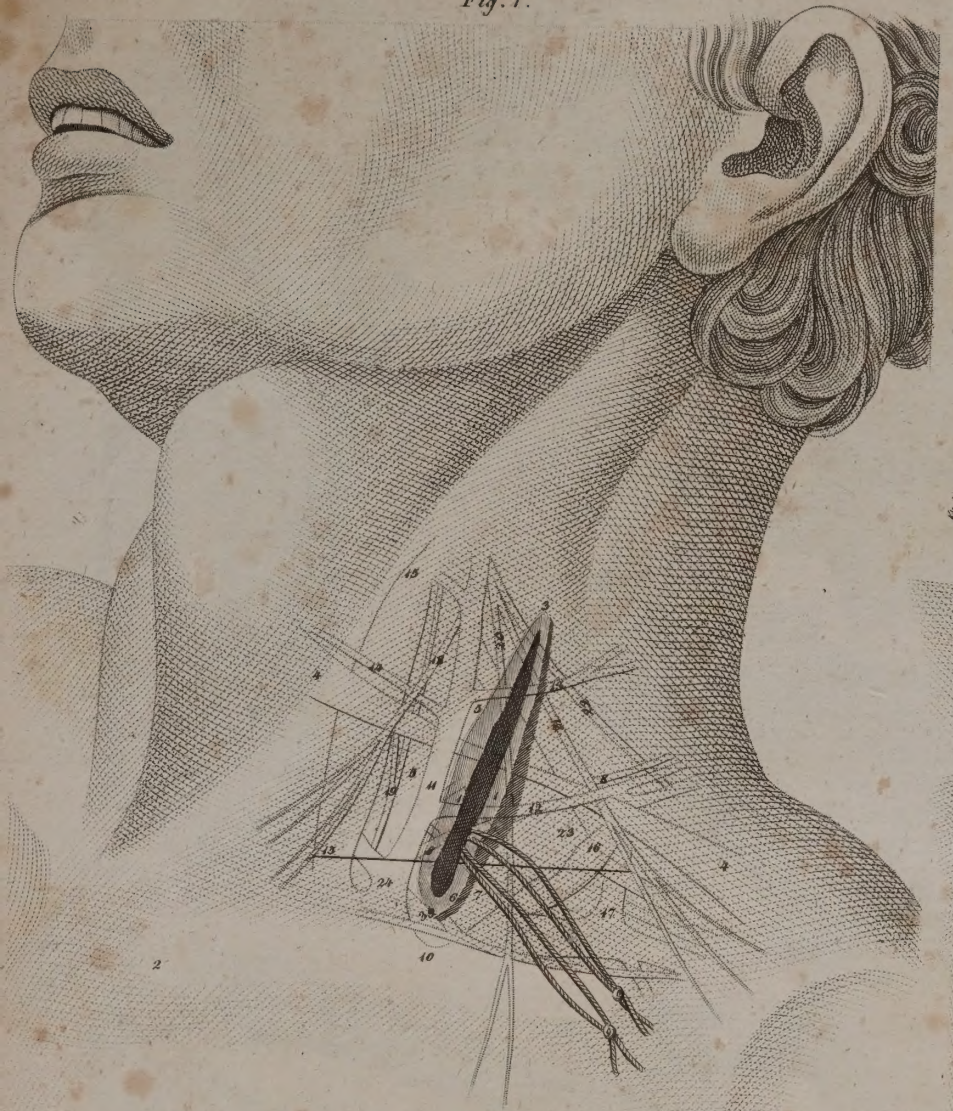

Fig. 2.

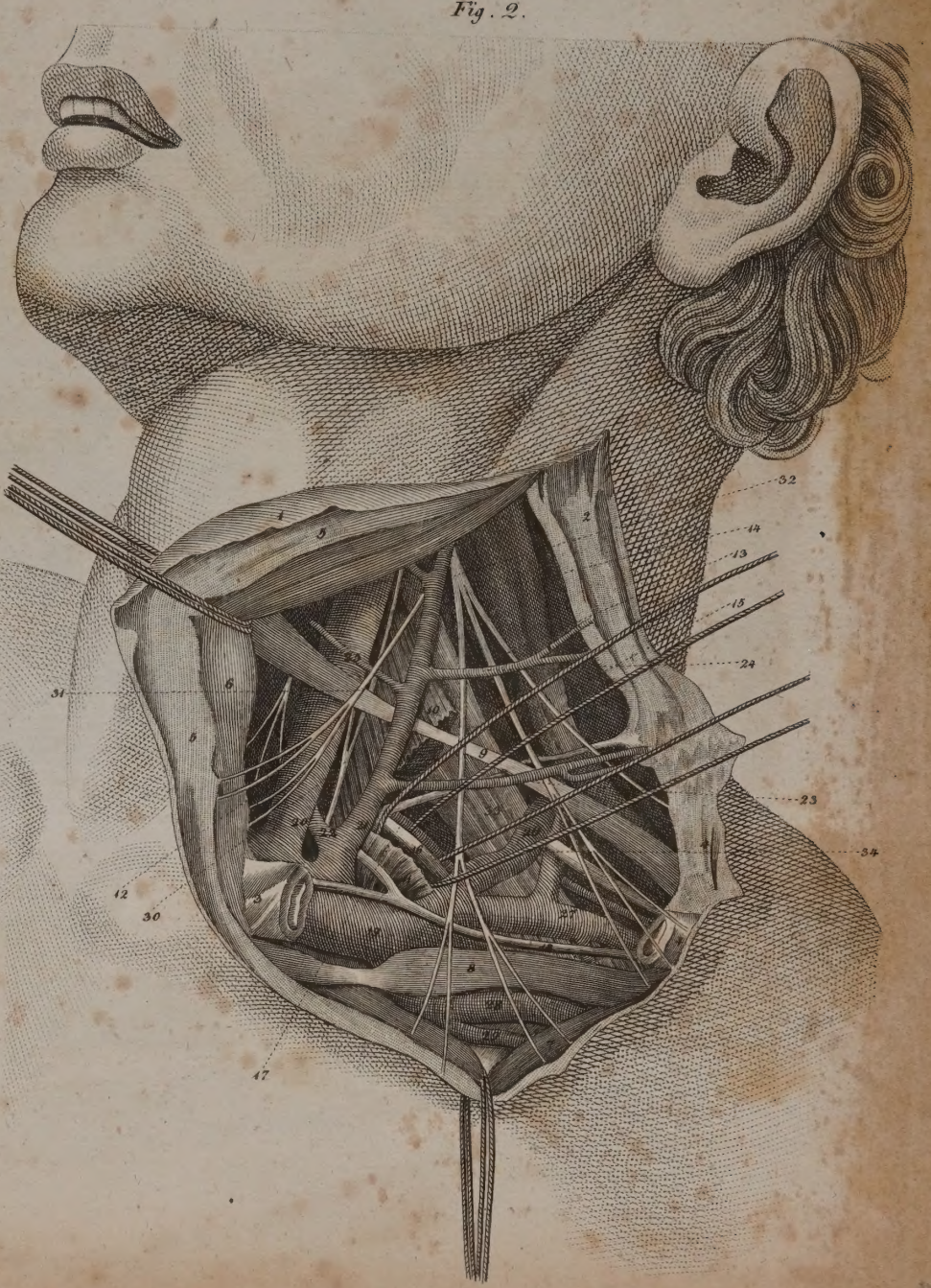

nach Bujalsky.

Fracturen.

Fig. 5.

Fig. 1.

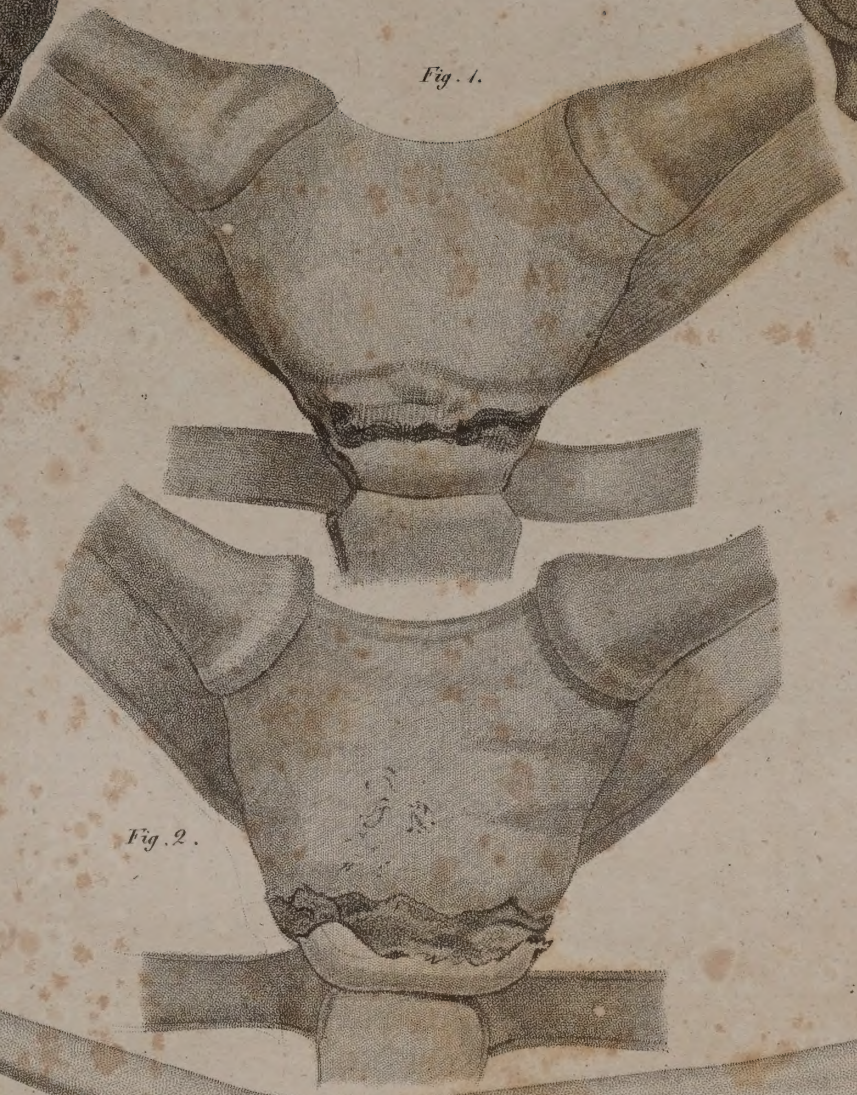

Fig. 2.

Fig. 6.

Fig. 3.

Fig. 4.

Bögeholdt sc. Lpz.

Distorsio.

Taf. CCXL.

Fig. 3.

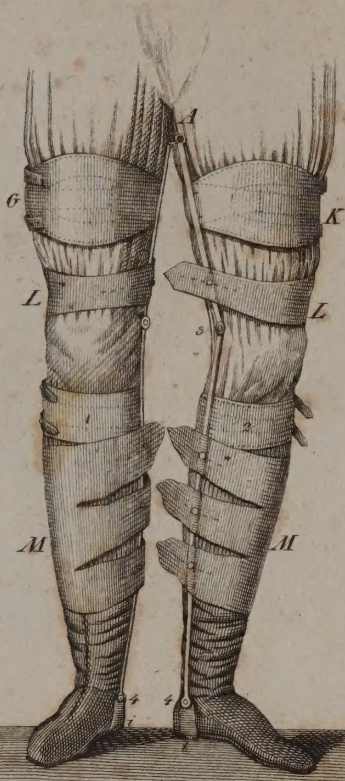

Fig. 1.

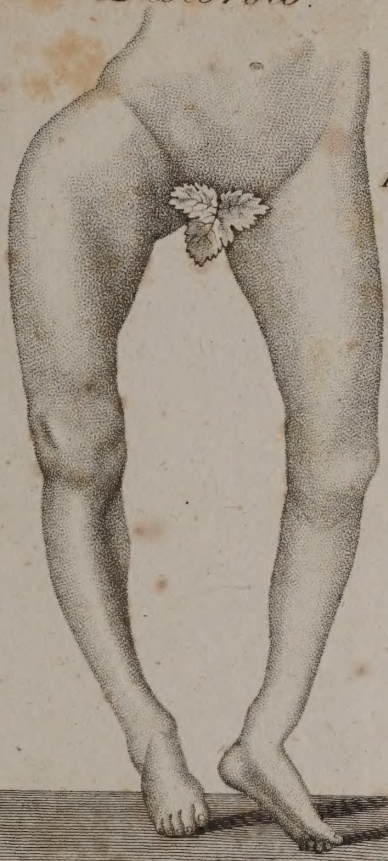

Fig. 2.

Fig. 4.



nach Jalade Lafond.

Fig. 1.

Fig. 2.

Fig. 3.

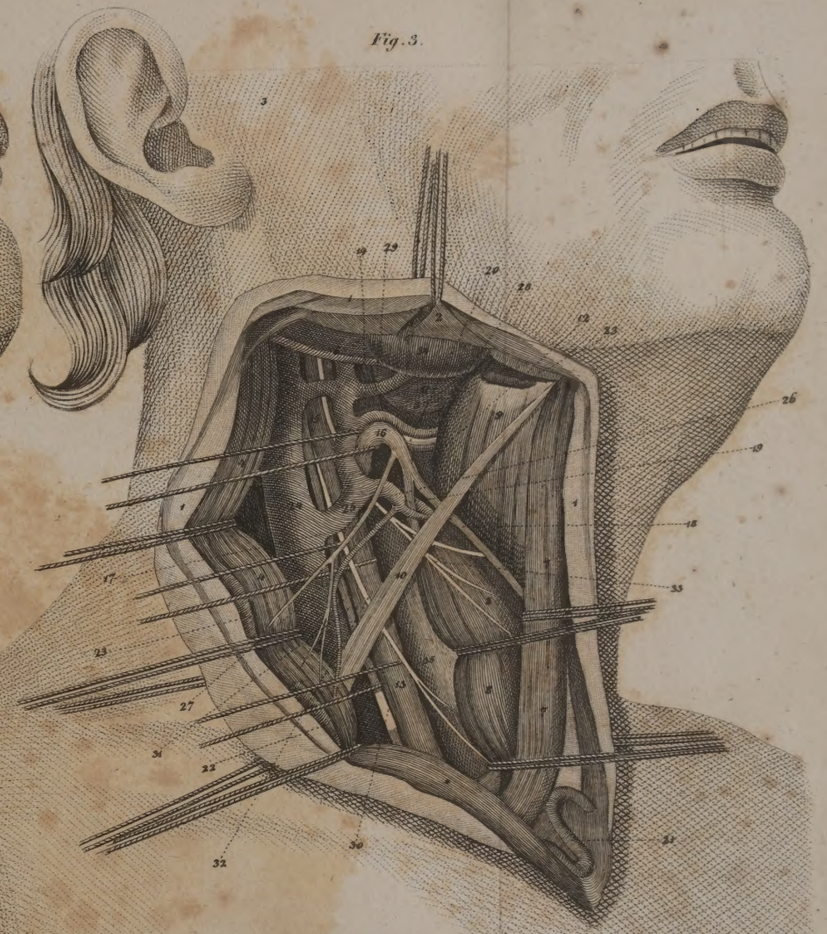

Nach Bujalsky.

Fig. 1.

Fig. 2.

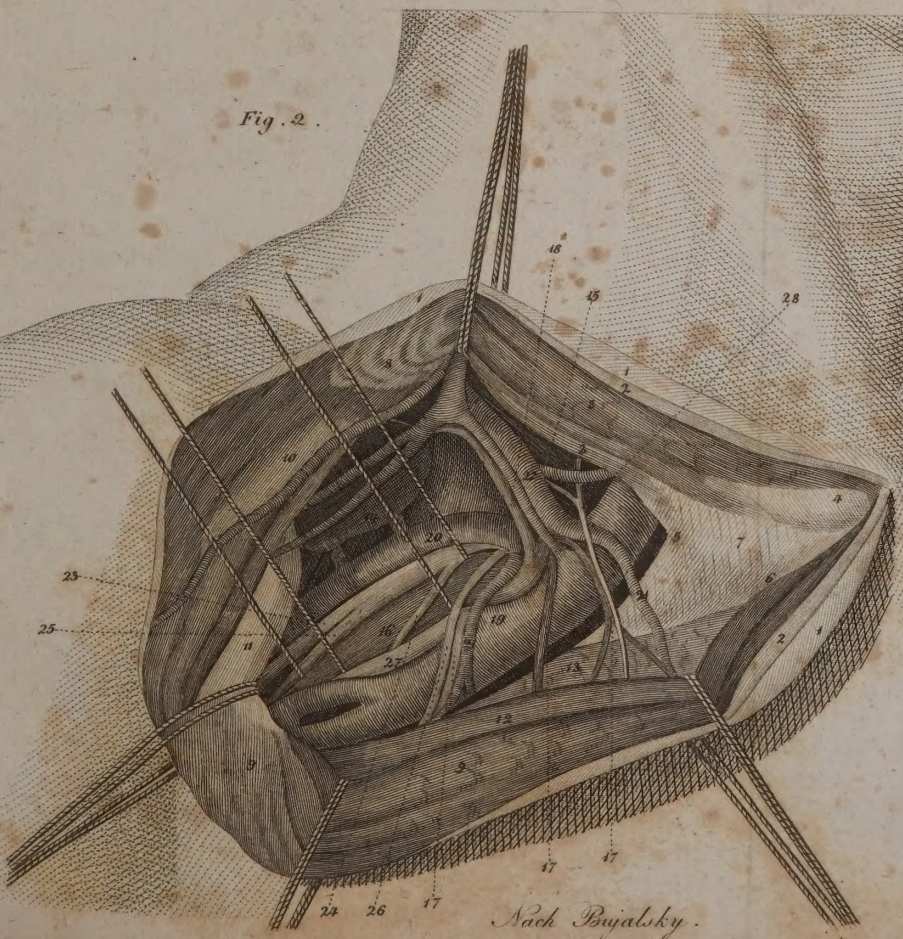

Nach Bujalsky.

Spinae Distorsio

Fig. 2.

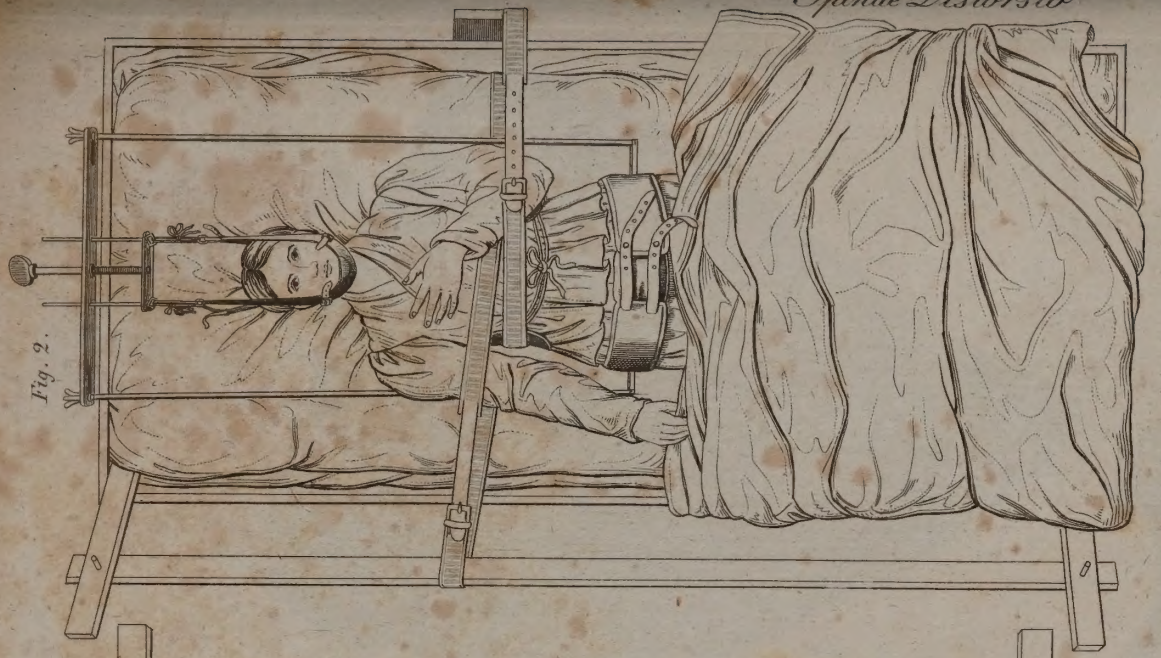

Fig. 1.

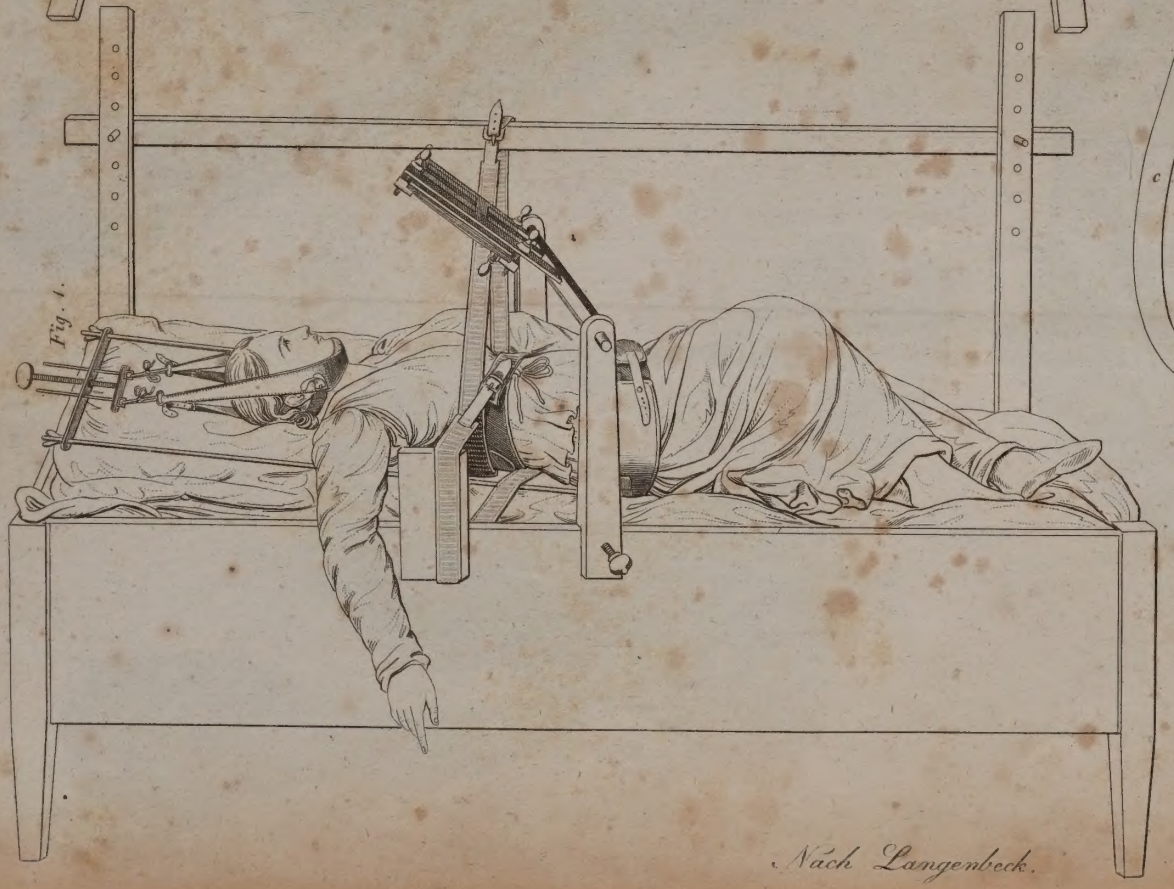

Fig. 3.

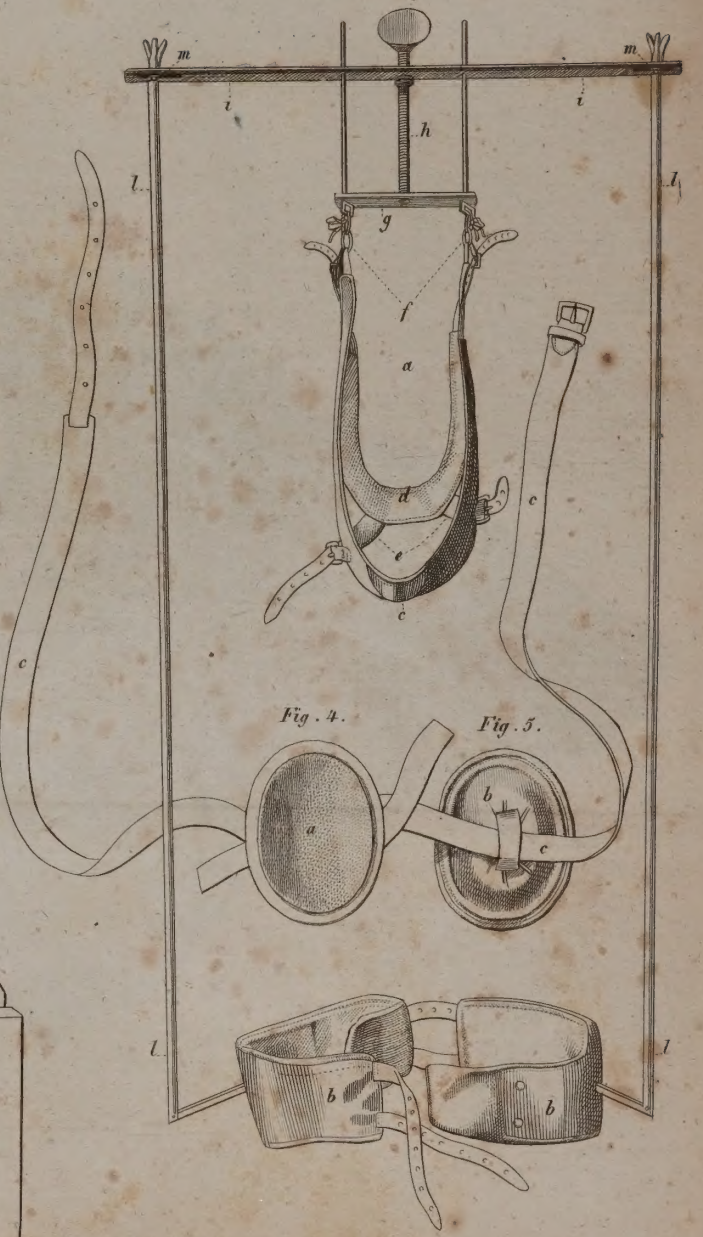

Fig. 4.

Fig. 5.

Nach Langenbeck.

Hernia Cruralis.

Taf. CCXLVII.

Fig. 3.

Fig. 1.

Fig. 2.

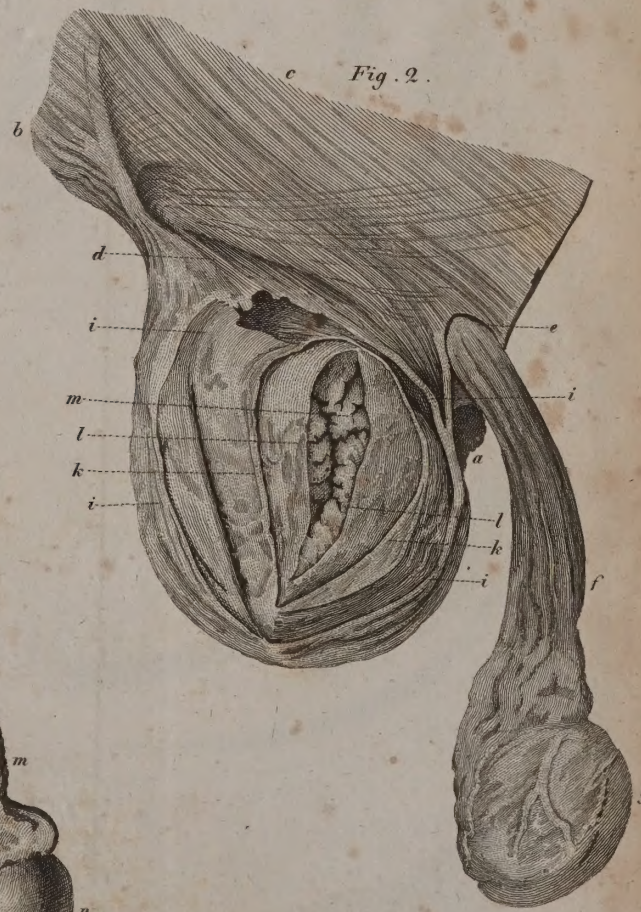

Apparatus lithontripticus.

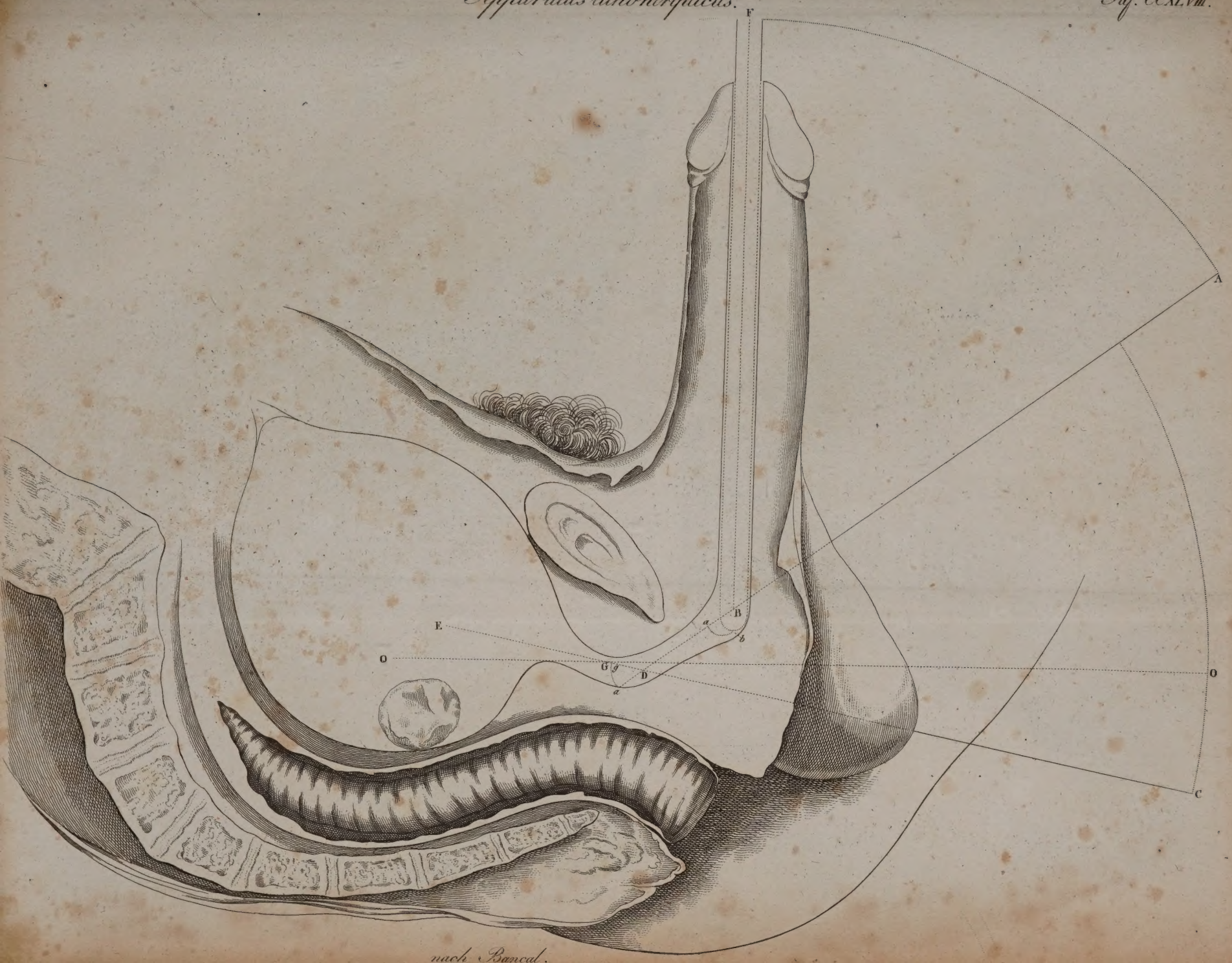

nach Bancal.

Fig. 1.

Fig. 2.

Nach Bujalsky.

Lithotomia.

Fig. 1.

nach Stanley.

Fig. 2.

Fig. 4.

Fig. 3.

Fig. 5.

Fig. 6.

Fig. 7.

Hernia.

Fig. 1.

Fig. 7.

Fig. 8.

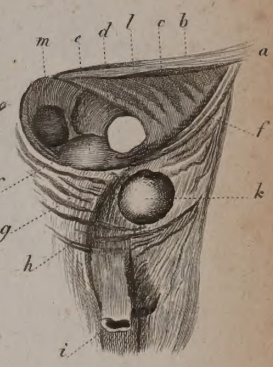

Fig. 5.

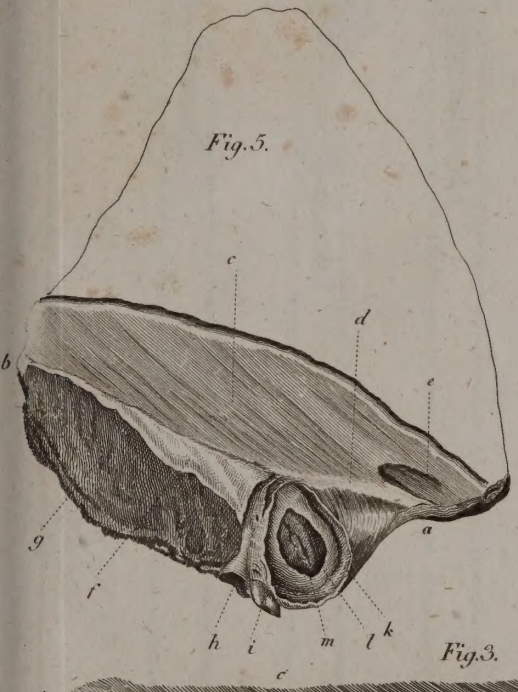

Fig. 2.

Fig. 6.

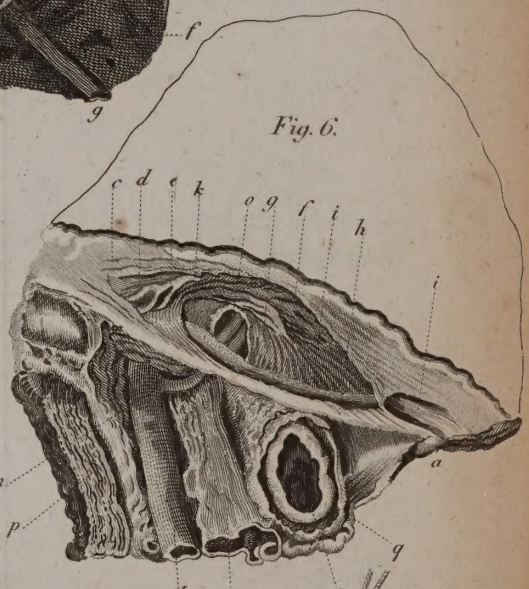

Fig. 3.

Fig. 4.

nach Sir Astley Cooper.

Cataracta.

Fig. 1.

Fig. 2.

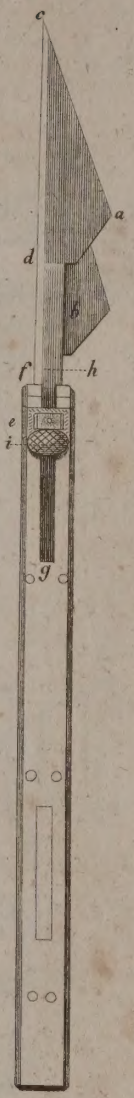

Fig. 3.

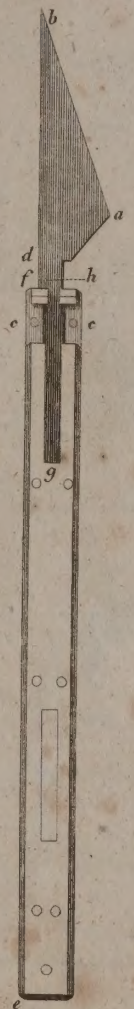

Fig. 4.



Fig. 5.

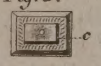

Fig. 6.

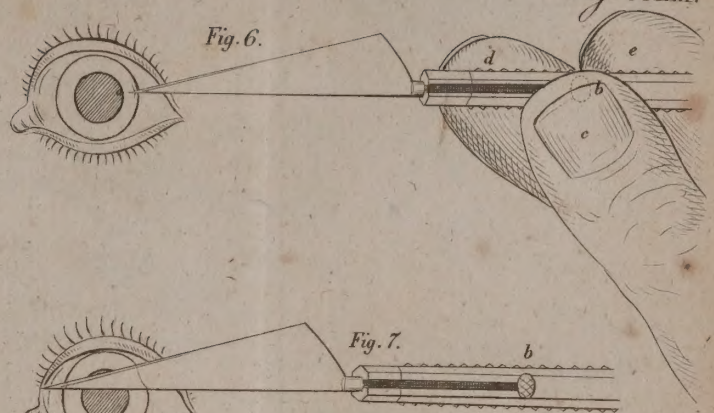

Fig. 7.

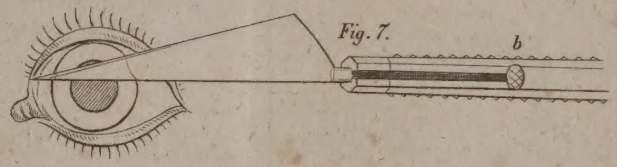

Fig. 8.

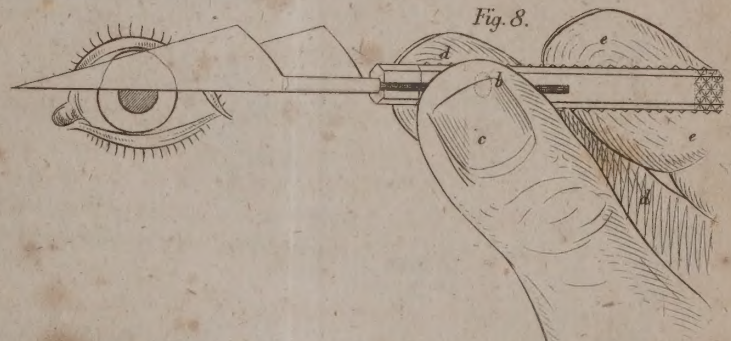

Fig. 9.

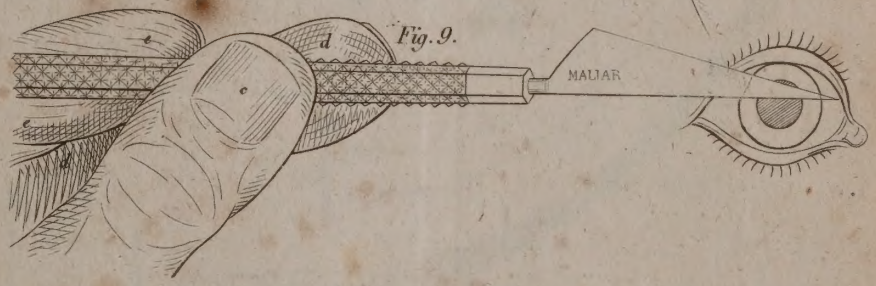

Fig. 12.

Fig. 11.

Fig. 13.

Fig. 10.



Fig. 1.

Fig. 2.

Fig. 3.

Fig. 4.

Fig. 5.

Fig. 6.

Fig. 7.

Fig. 8.

Fig. 9.

Fig. 10.

Fig. 11.

Fig. 12.

Fig. 13.

Fig. 14.

Fig. 15.

Fig. 16.

Fig. 17.

Fig. 18.

Fig. 19.

Fig. 20.

Fig. 21.

Fig. 22.

Fig. 23.

Fig. 24.

Fig. 25.

Fig. 26.

Uteri exstirpatio.

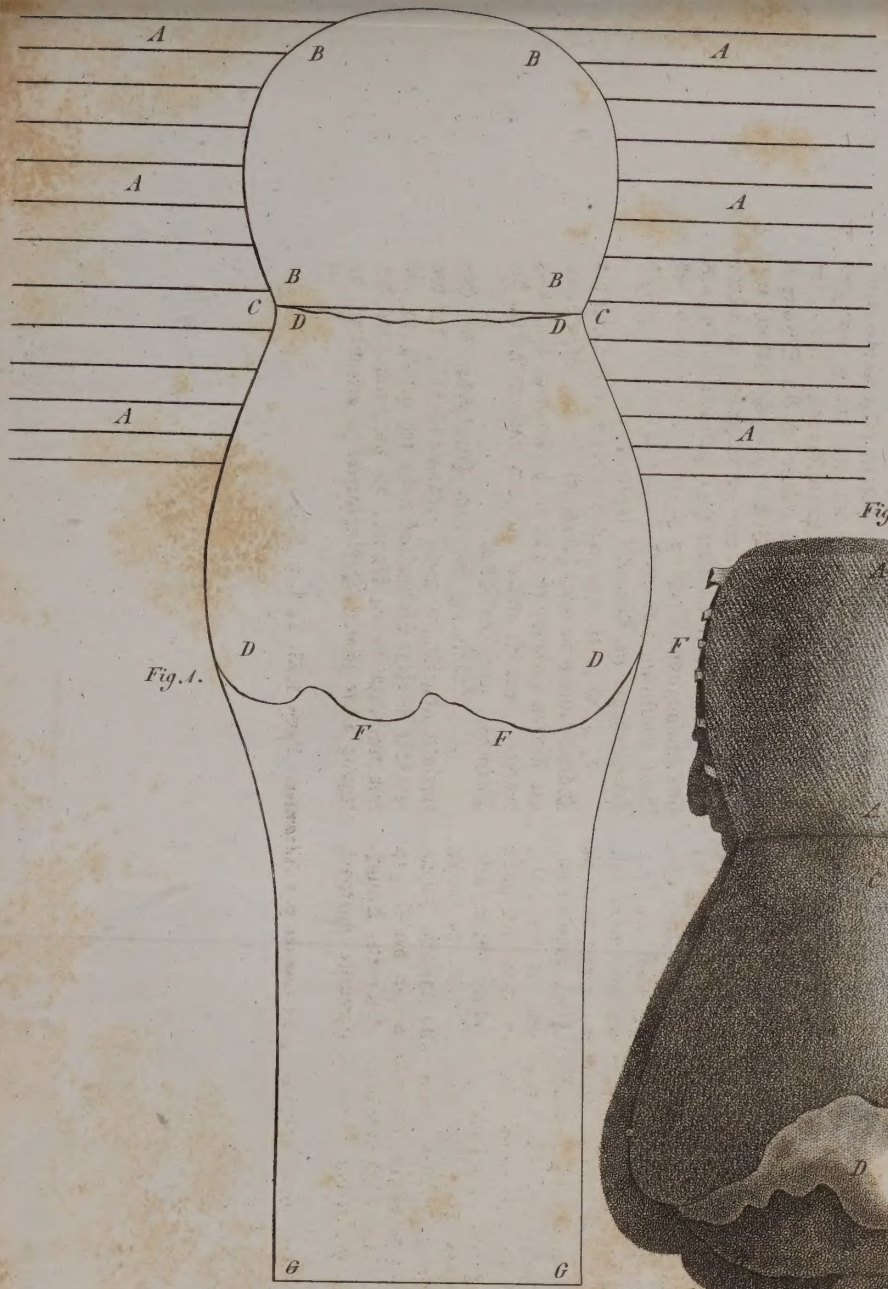

Fig. 1.

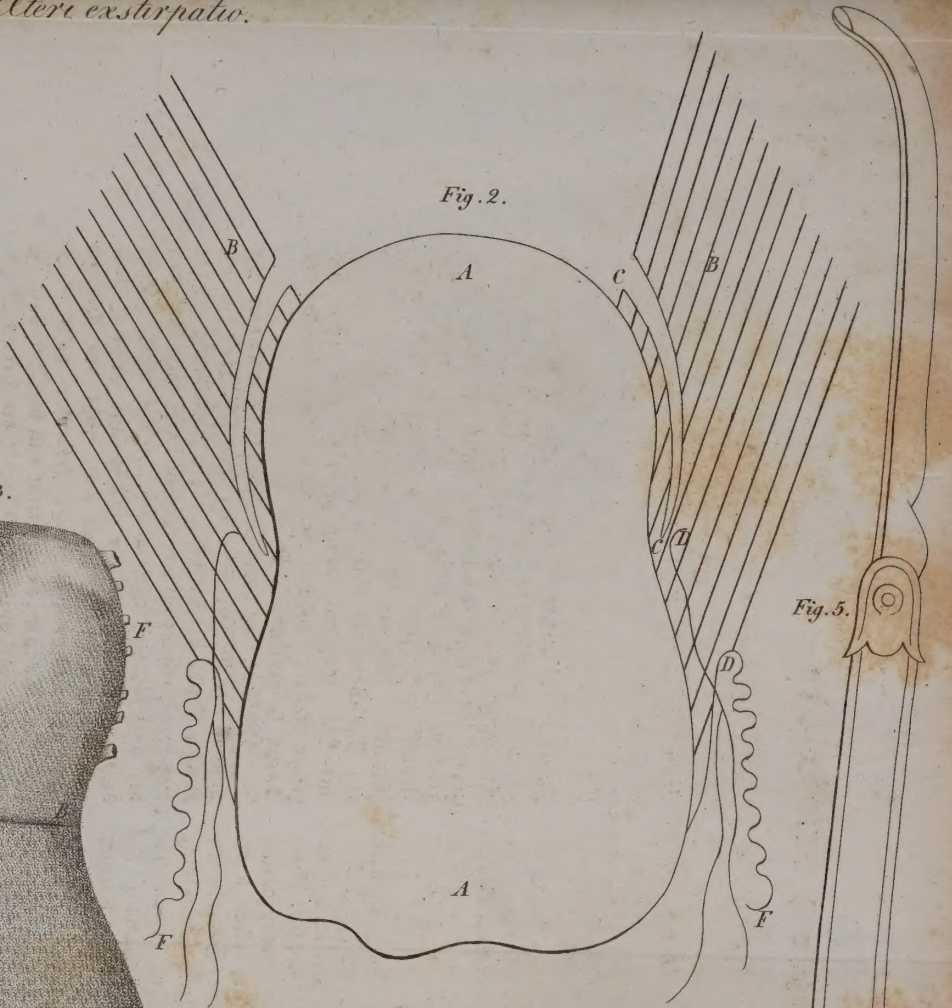

Fig. 2.

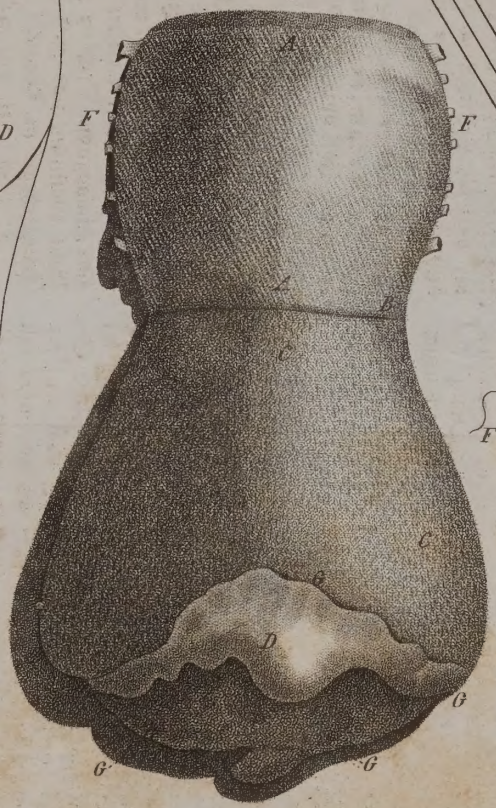

Fig. 3.

Fig. 5.

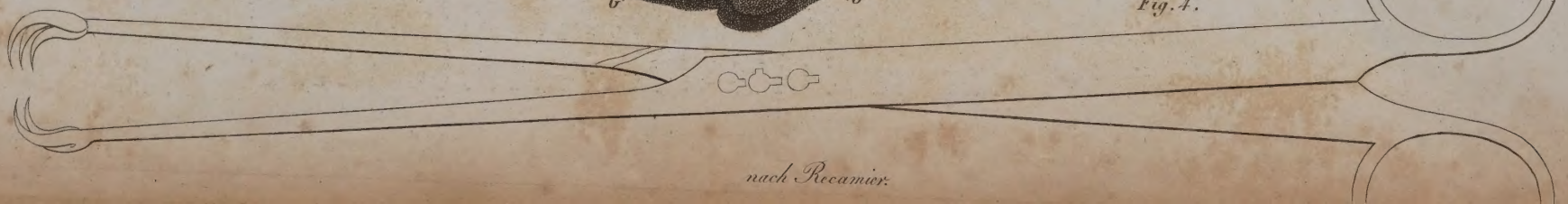

Fig. 4.

nach Recamier.

Taf. CLIX.

Hernia.

Fig. 1.

Fig. 2.

Fig. 3.

Fig. 7.

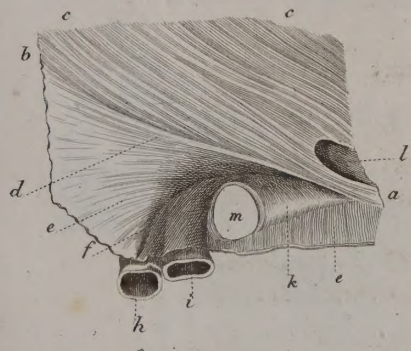

Fig. 8.

Fig. 6.

Fig. 4.

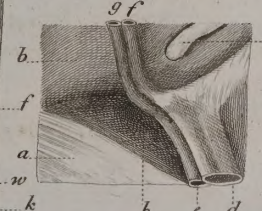

Fig. 5.

nach Sir A. Cooper.

Fig. 1.

Cicatrix.

Taf. CCLVIII.

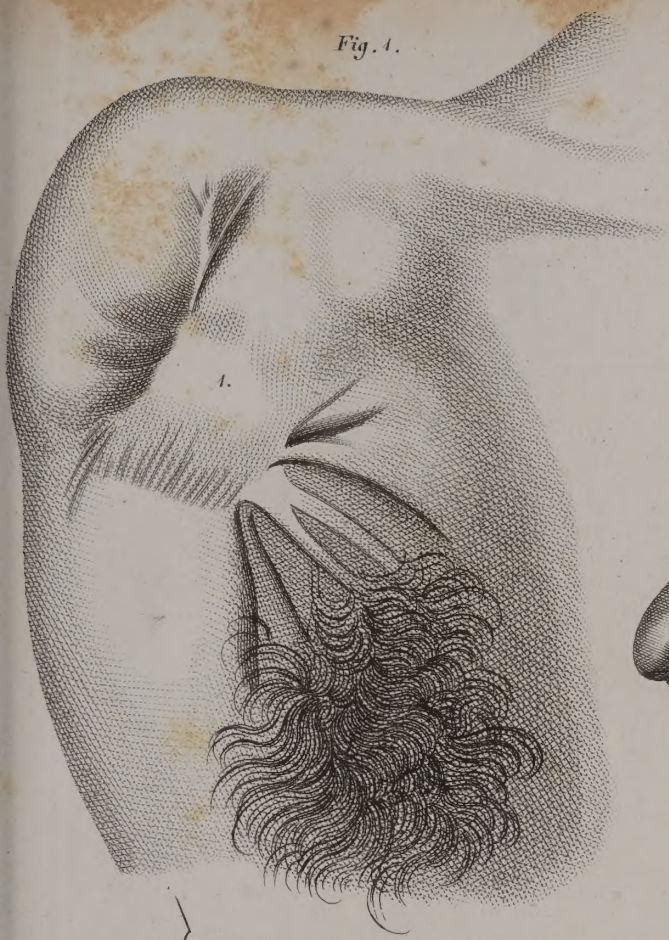

Fig. 4.

Fig. 5.

Fig. 3.

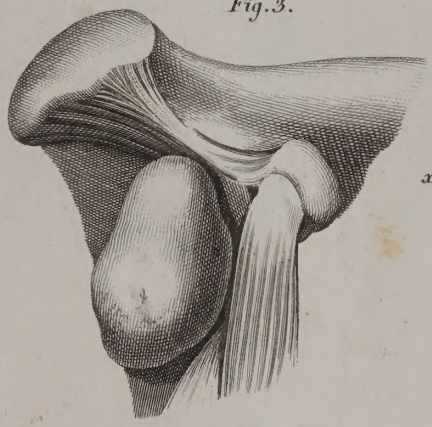

Fig. 2.

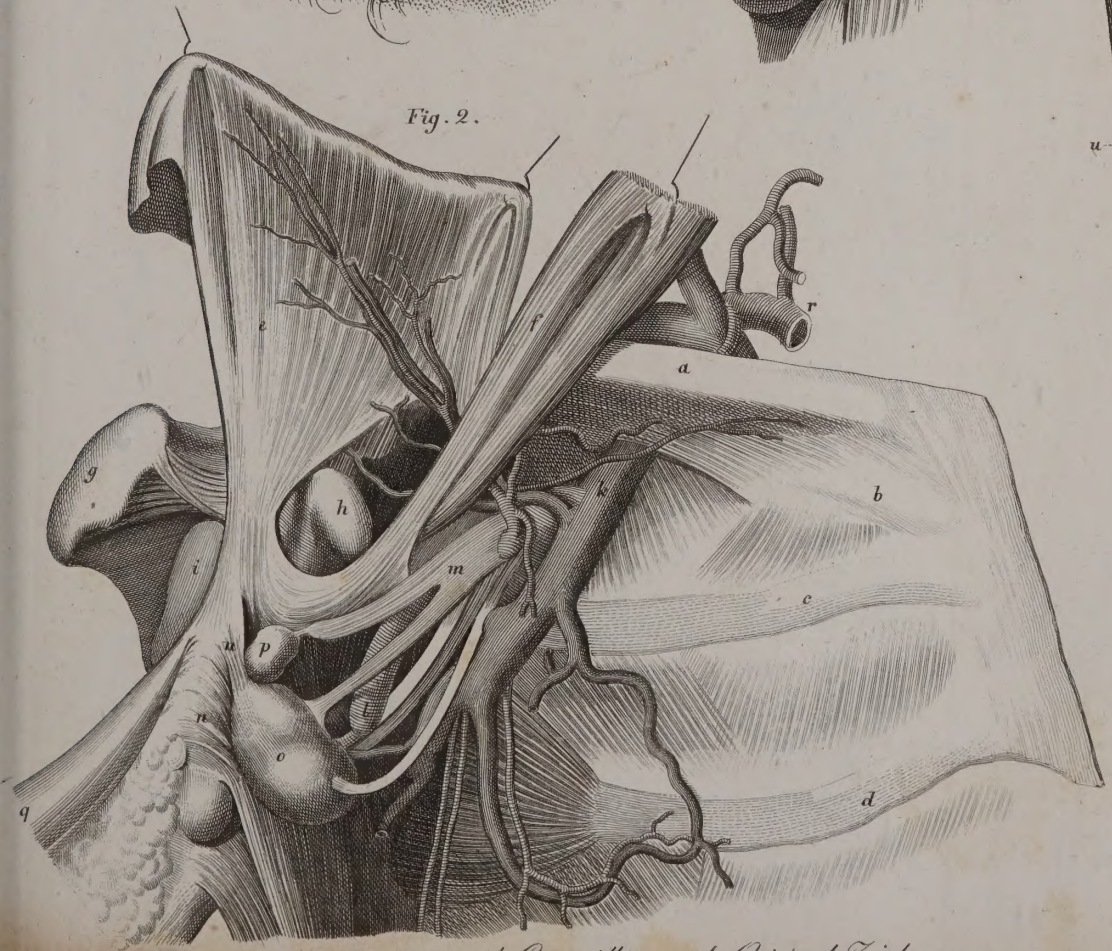

nach Cruveilhier und Original Zeichnung.

Polypus.

Taf. CCLIX.

Fig. 1.

Fig. 2.

Fig. 3.

Fig. 4.

Fig. 7.



Fig. 6.

Fig. 5.



Fig. 8.

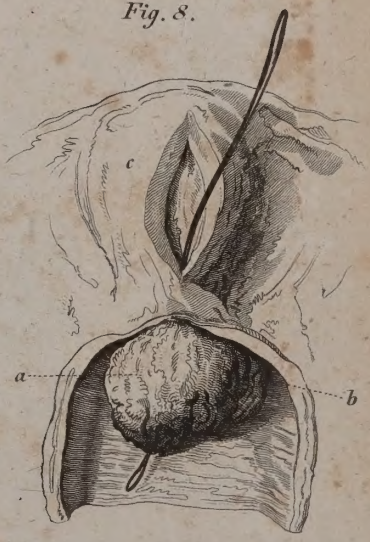

nach Gooch.

Distorsio Spinae

Taf. CCLX.

Fig. 1.

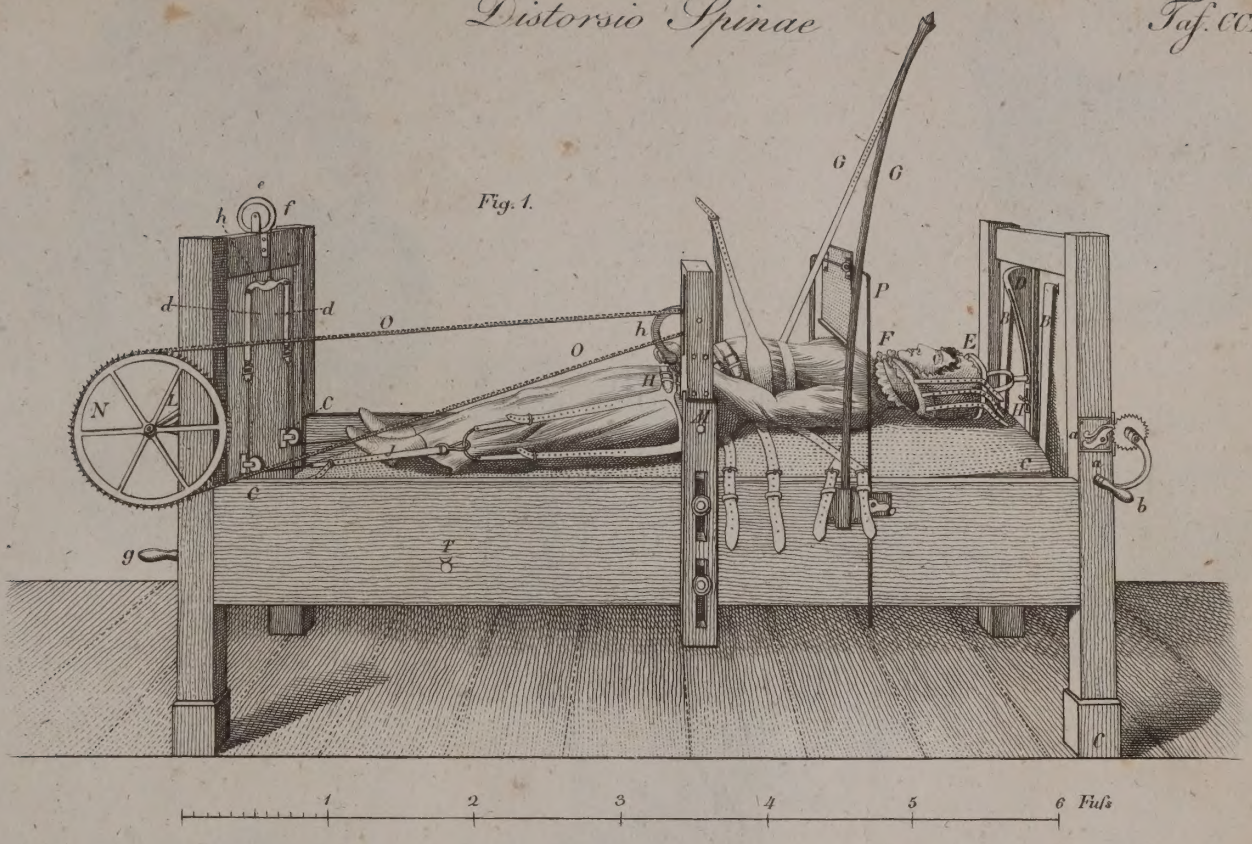

Fig. 2.

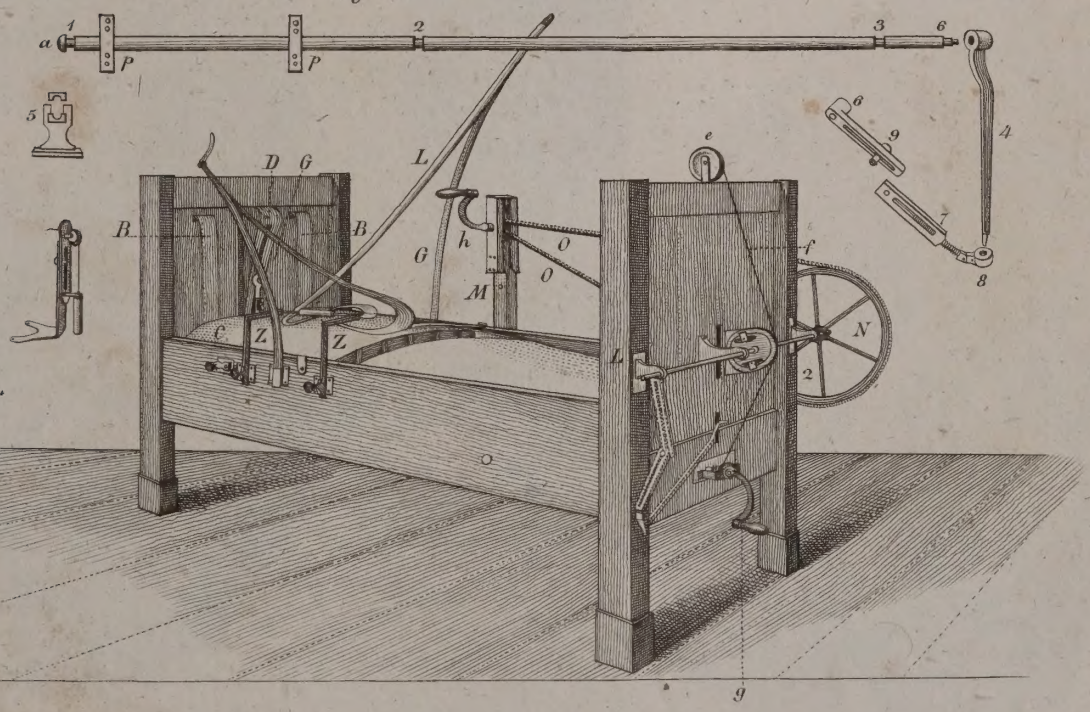

Fig. 2.

Fig. 3.

Fig. 4.

Fig. 4.

Fig. 5.

Fig. 6.

nach Sir Astley Cooper.

Varix aneurismaticus — *Taf. CCLXIII.*

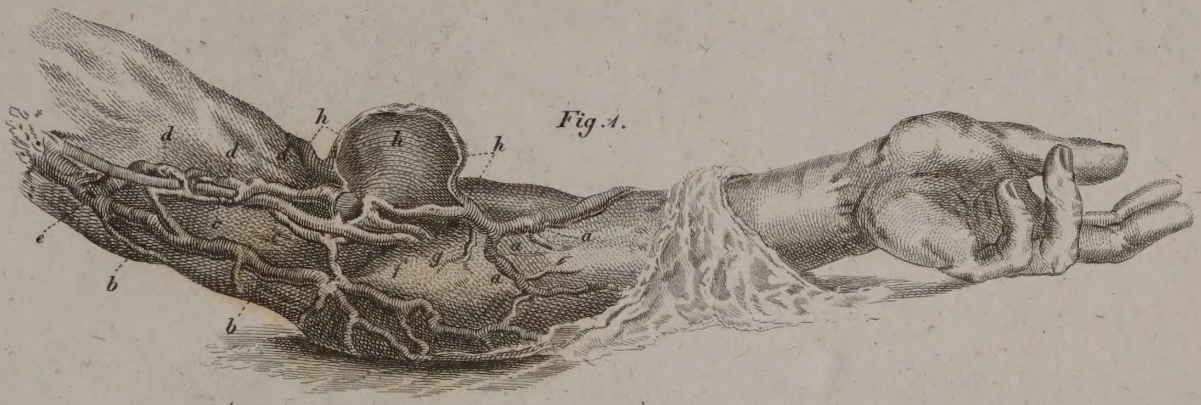

Fig. 1.

Fig. 2.

Fig. 3.

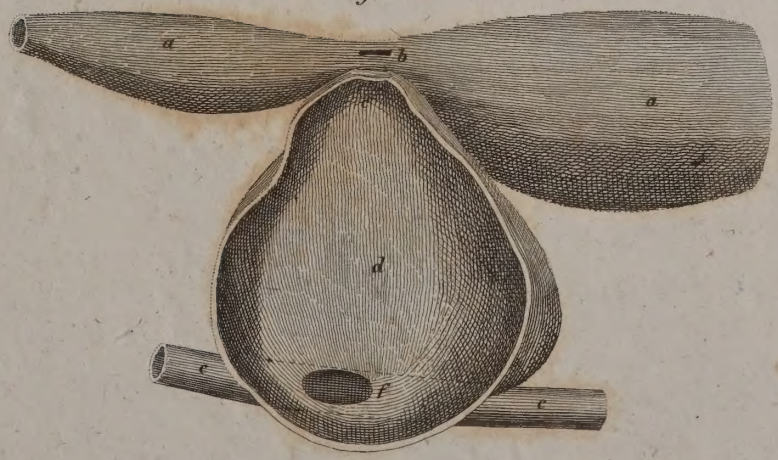

nach Bell und Dorsey.

Anchylosis.


x
r
s
Fig. 1.
s
r
x
n
k
D
c
m
a
l
T
A
B
x
l
k
z
z
E
b
c
x
i
F
H
P
G
m
m 5
m 4
m 3
m 2
m 1
R

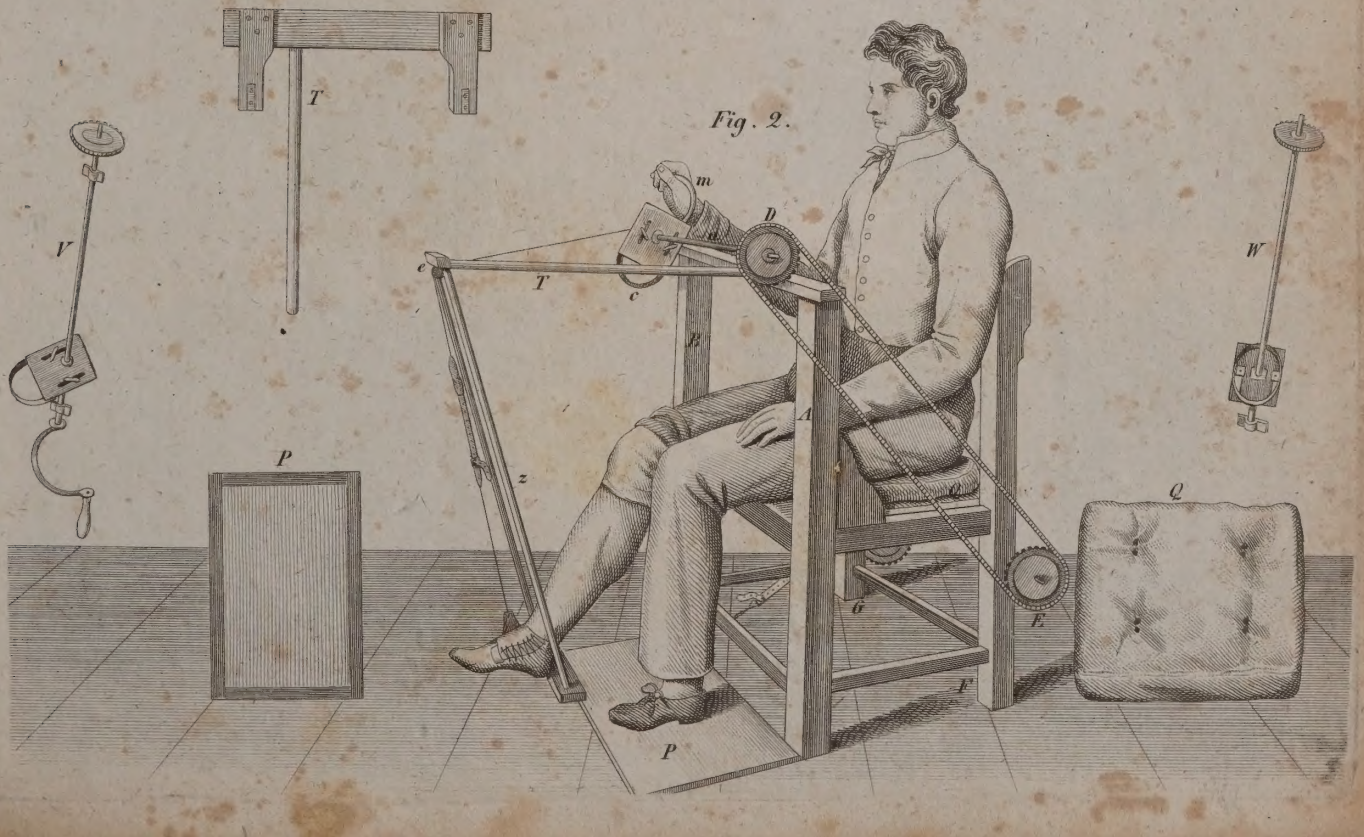
T
Fig. 2.
V
m
D
a
c
T
c
B
A
z
P
W
Q
G
E
F
P

Hernia umbilicalis.

Fig. 1.

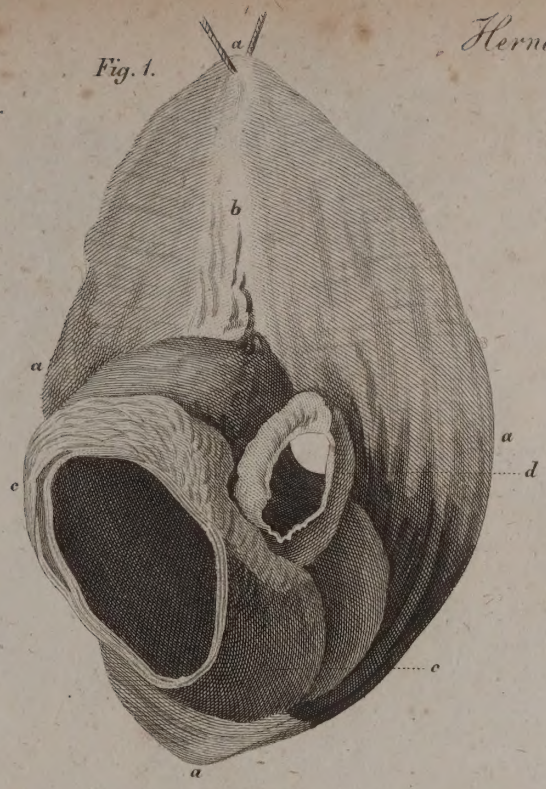

Fig. 2.

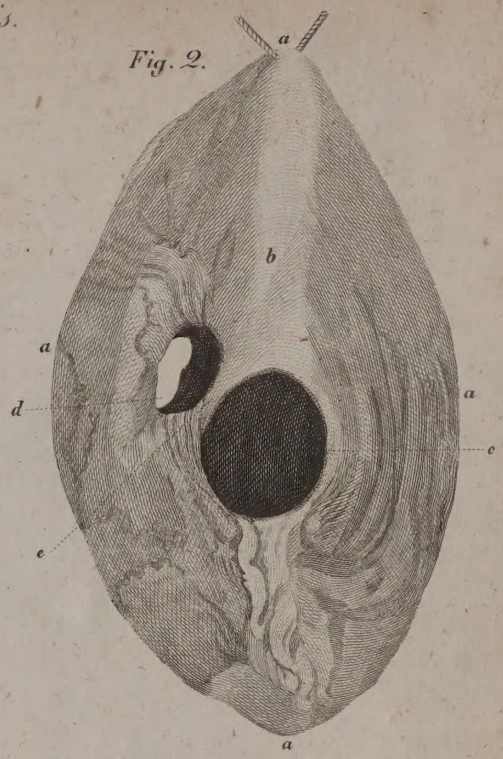

Fig. 6.

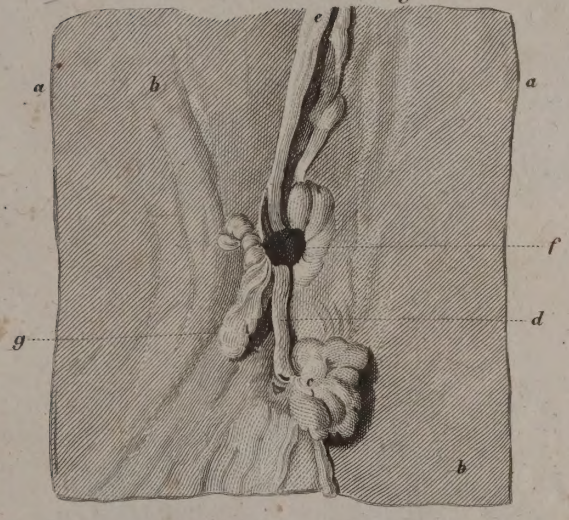

Fig. 4.

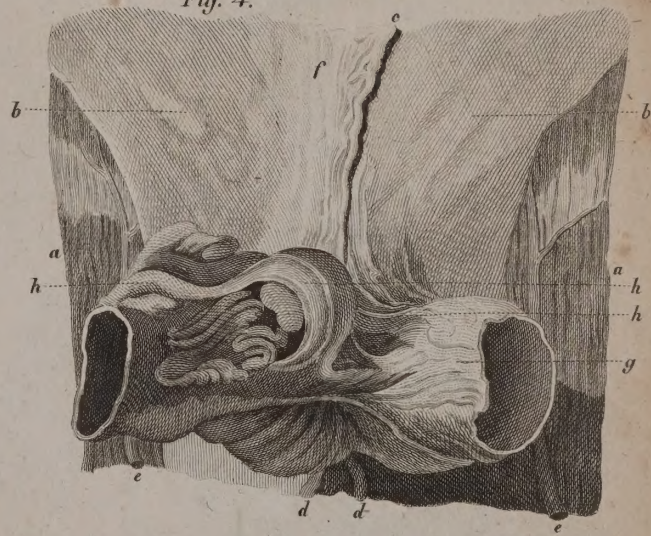

Fig. 5.

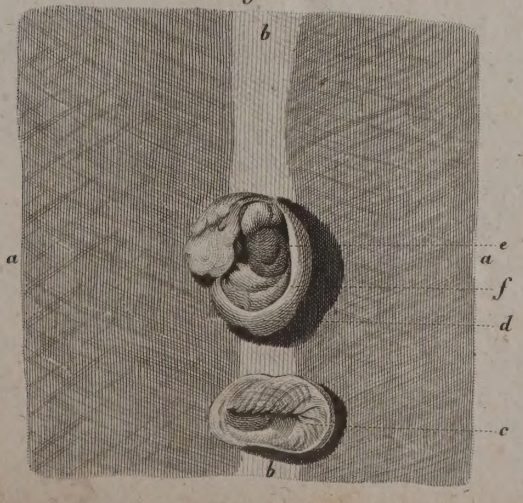

Fig. 3.

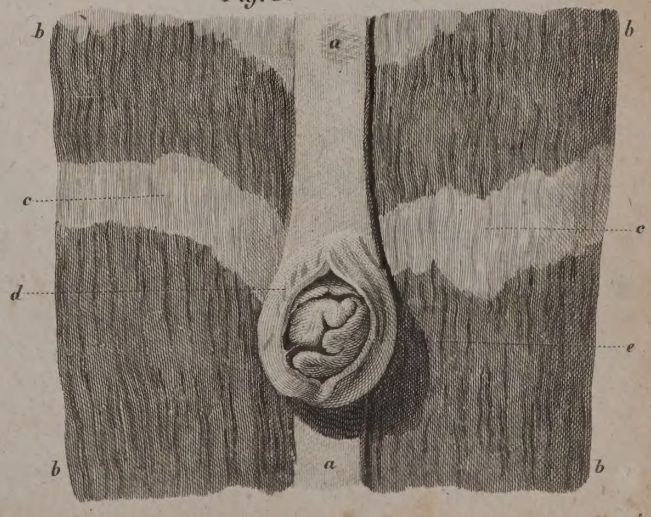

Testium morbi.

Fig. 1.

Fig. 4.

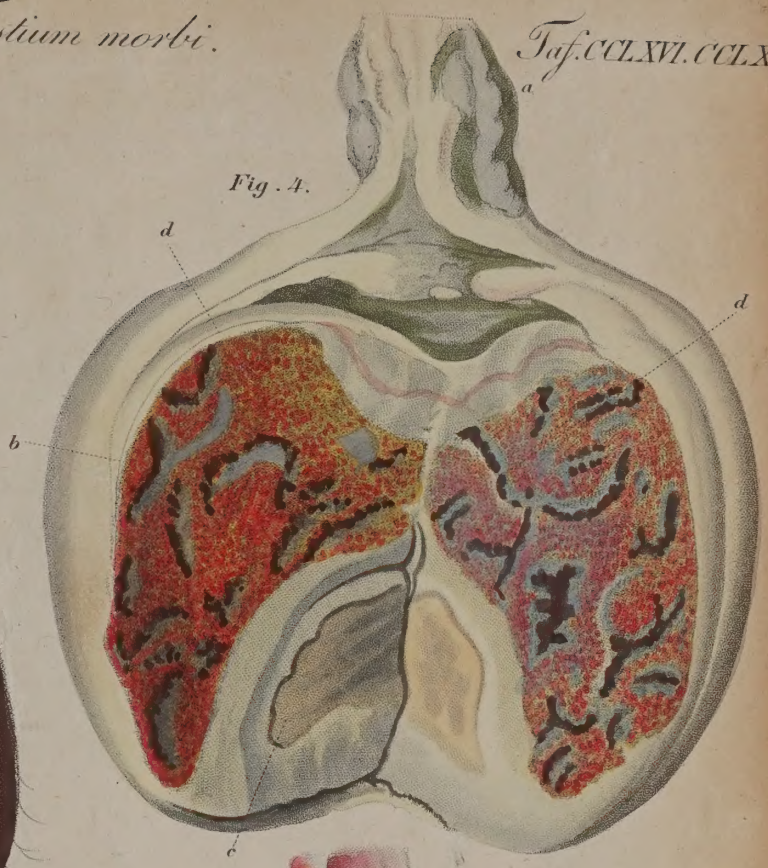

Fig. 3.

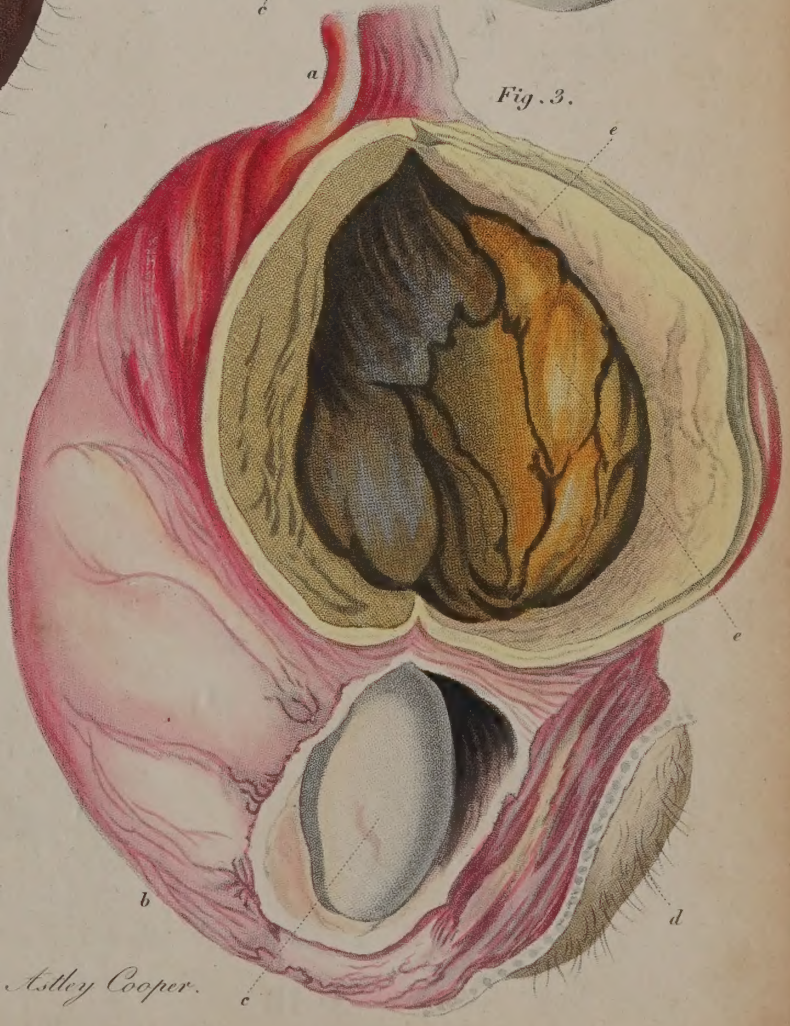

Fig. 2.

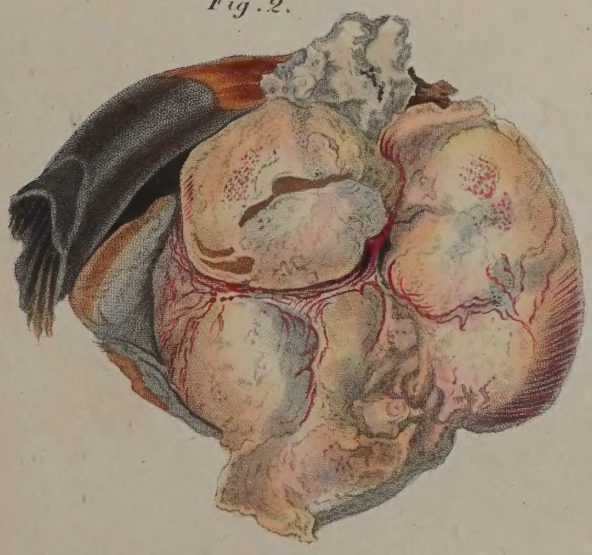

nach Sir Astley Cooper.

Fig. 1.

Anus artificialis.

Taf. CCLXVIII.

Fig. 2.

Fig. 3.

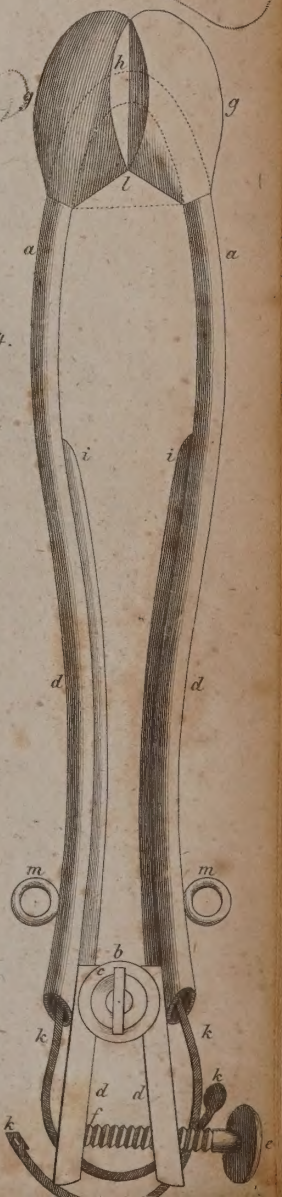

Fig. 4.

nach Lallemand und Delpech.

Scirrhus.
B.

Taf. CCLXIX.

Fig. 1.

Fig. 2.

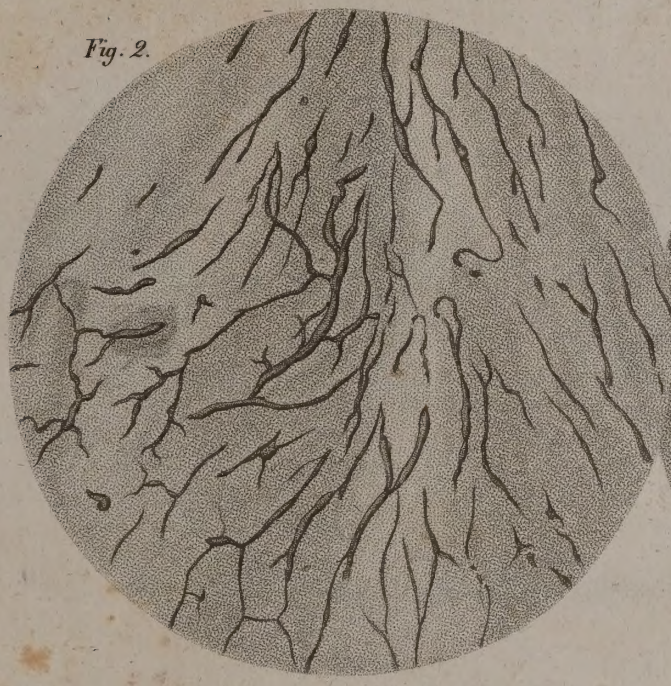

Fig. 3.

Fig. 4.

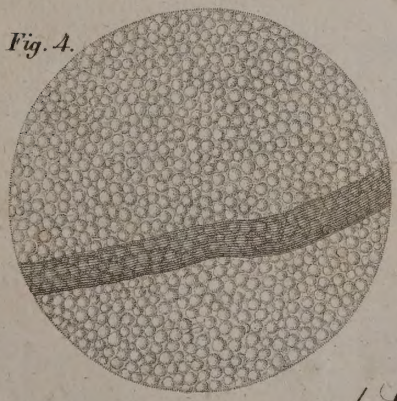

Fig. 5.

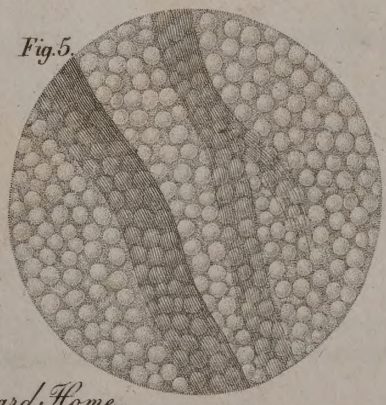

Fig. 6.

Fig. 7.

nach Sir Everard Home

Pupilla artificalis

E

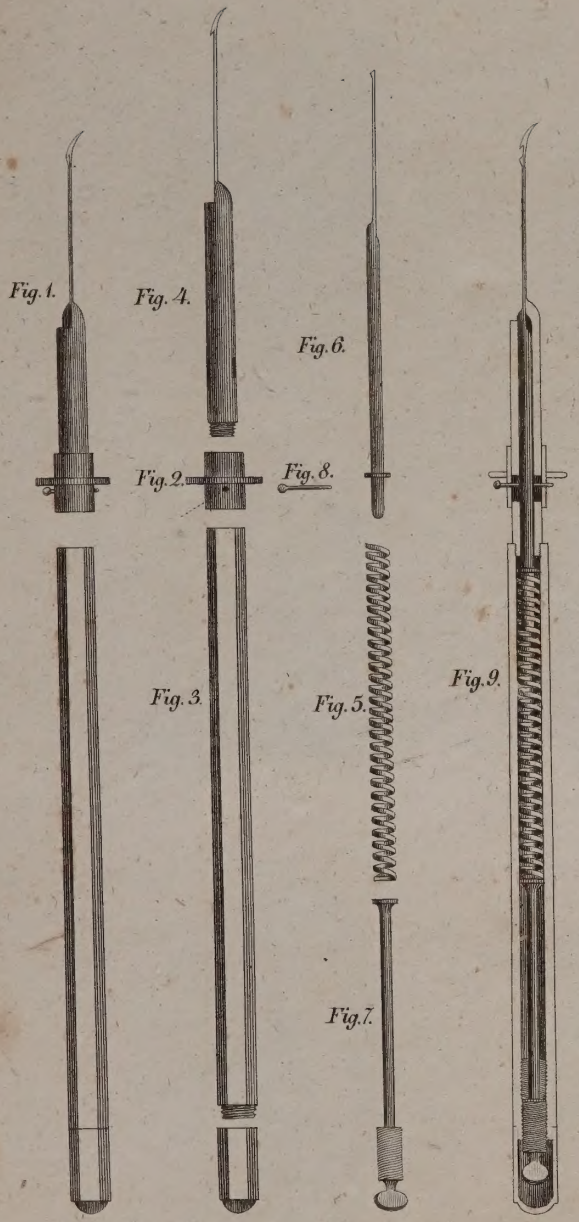

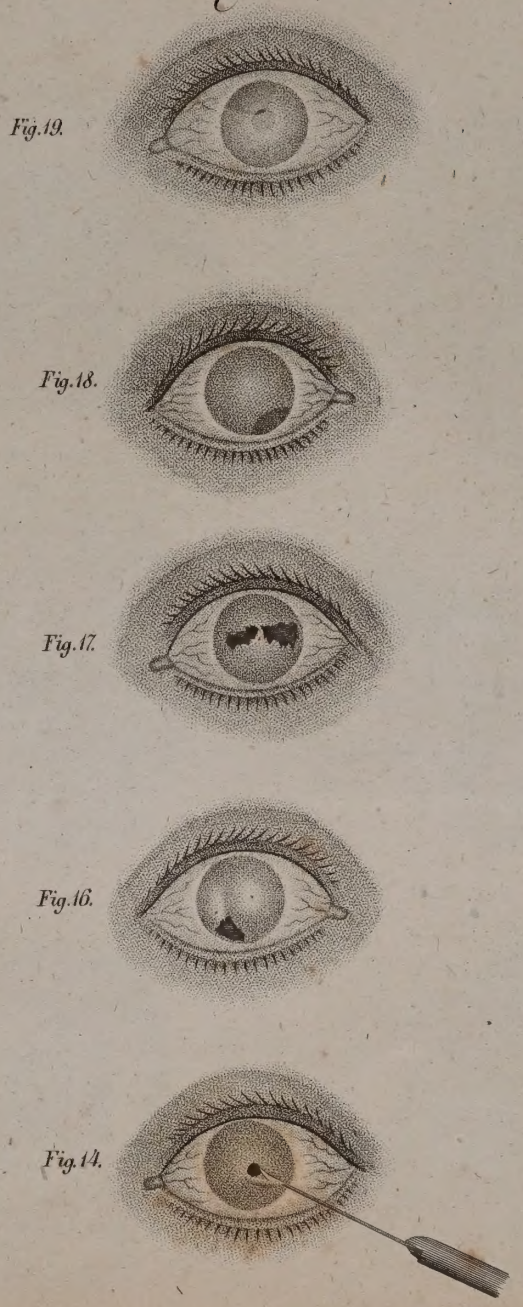

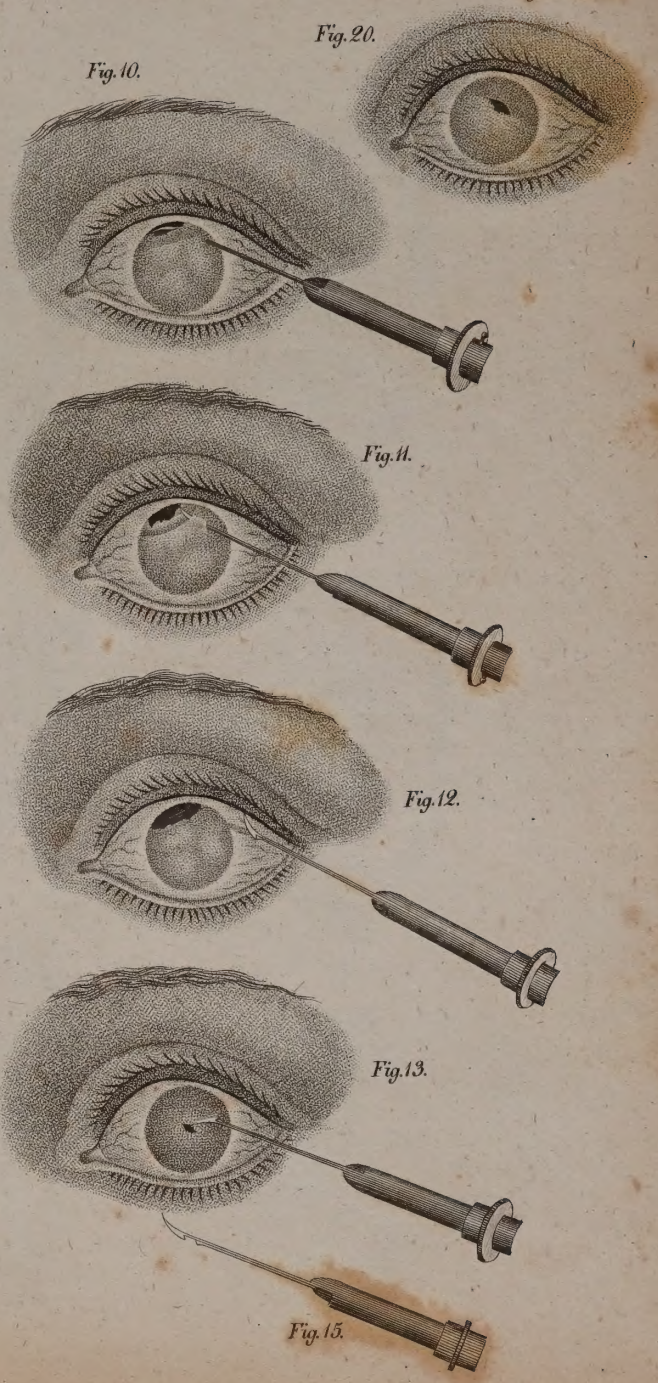

nach Lusardi

Taf. CCLXXI. CCLXXII.

Fig. 1.

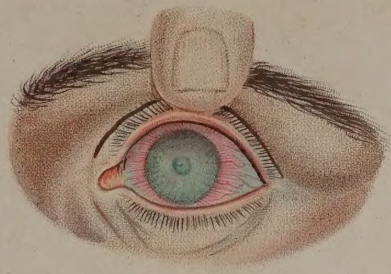

Fig. 2.

Fig. 3.

Fig. 4.

Fig. 5.

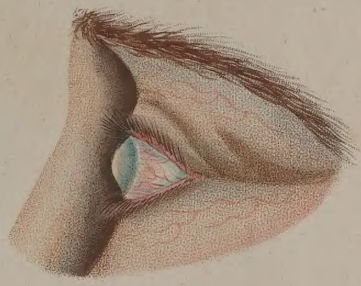

Fig. 6.

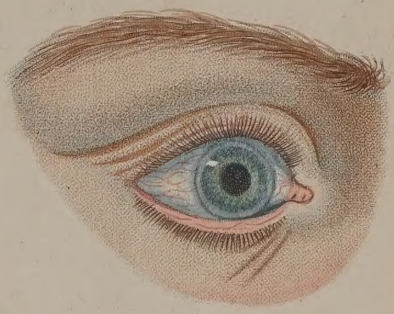

Fig. 7.

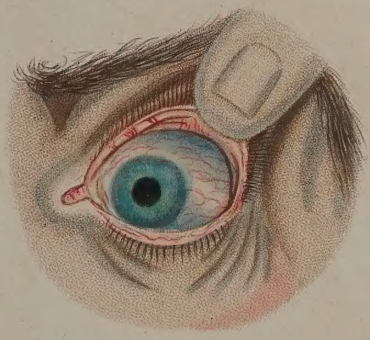

Fig. 8.

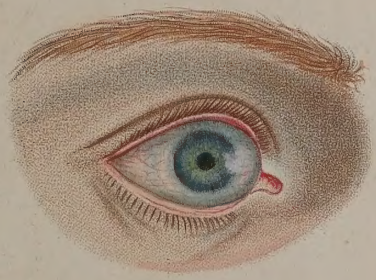

Fig. 9.

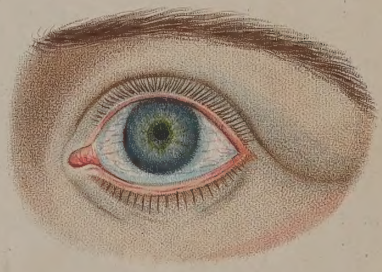

Fig. 10.



Fig. 11.

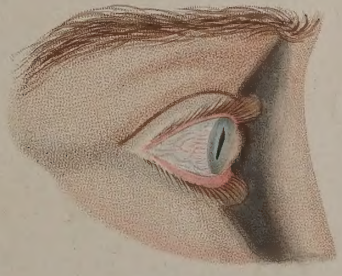

Fig. 12.

D.C.R. Fioriep ad naturam pinx.

Lithotomia

Fig. 1.



Fig. 2.

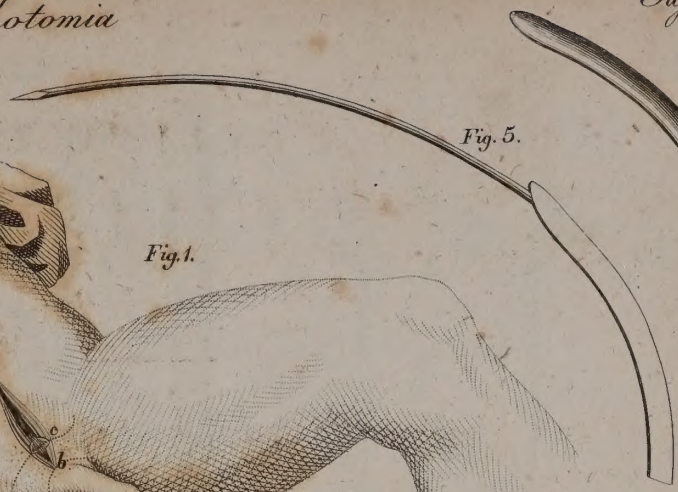

Fig. 5.



Fig. 4.

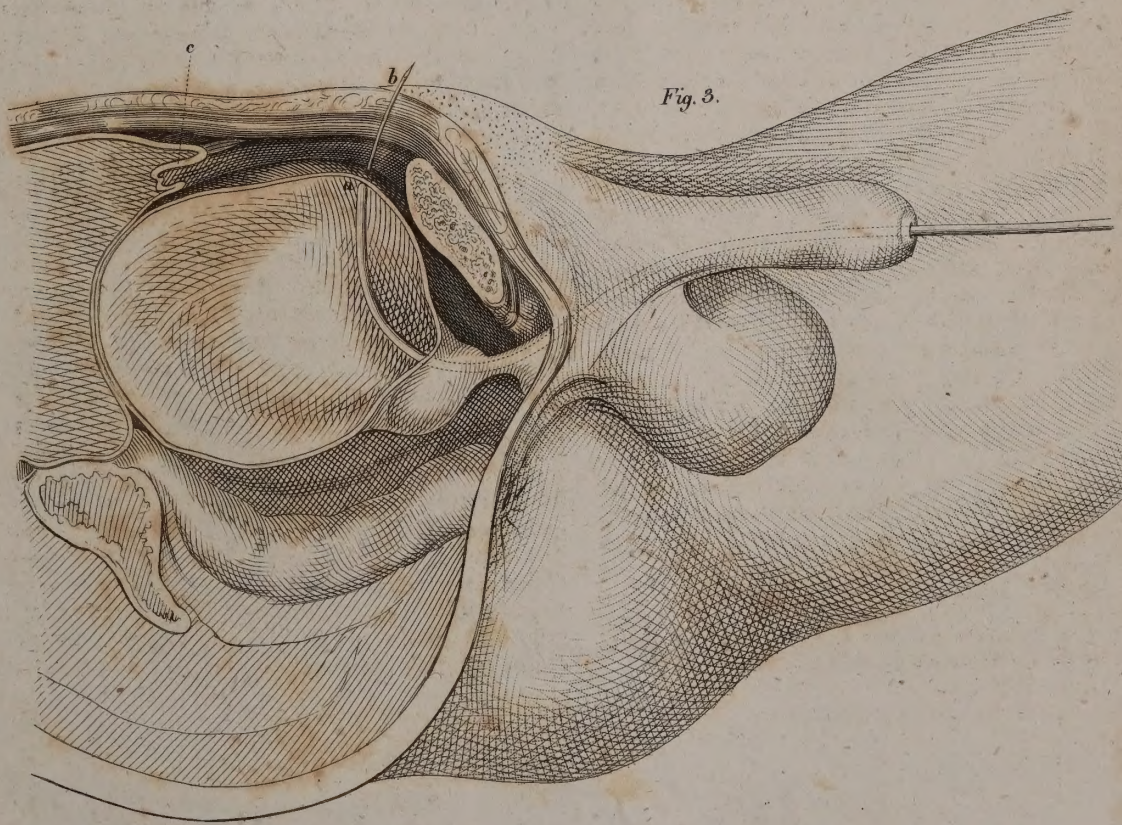

Fig. 3.



Fig. 6.

Cathelerismus.

Taf. CCLXXIV.

Fig. 1.

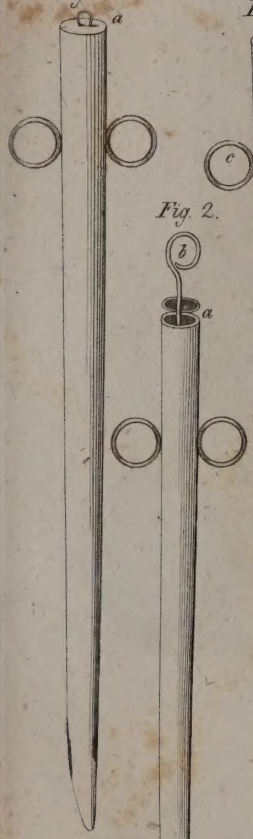

Fig. 2.



Fig. 3.

Fig. 4.



Fig. 5.



Fig. 6.



Fig. 7.

Fig. 8.

Fig. 9.

Fig. 10.

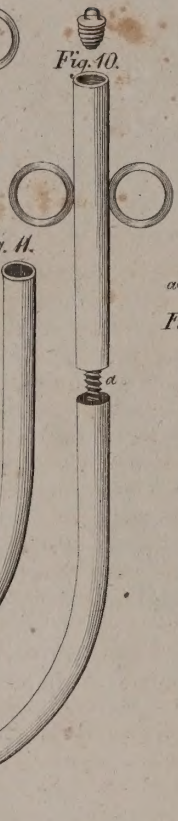

Fig. 11.

Fig. 12.



Fig. 13.

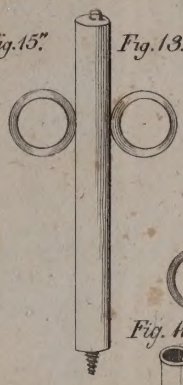

Fig. 14.

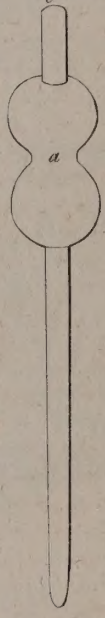

Fig. 15.



Fig. 15'

Fig. 16.

Fig. 17.

Fig. 18.

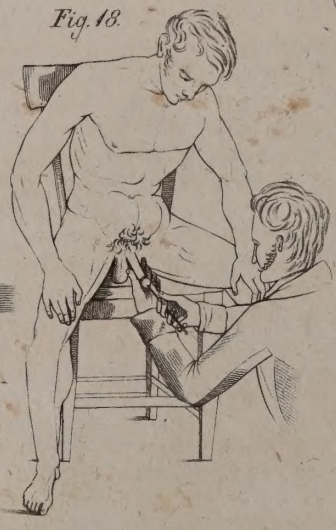

Fig. 19.

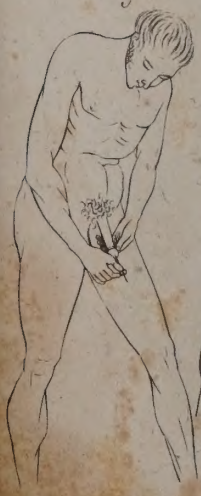

Fig. 20.

Fig. 21.

Fig. 22.

Fig. 23.

Fig. 1.

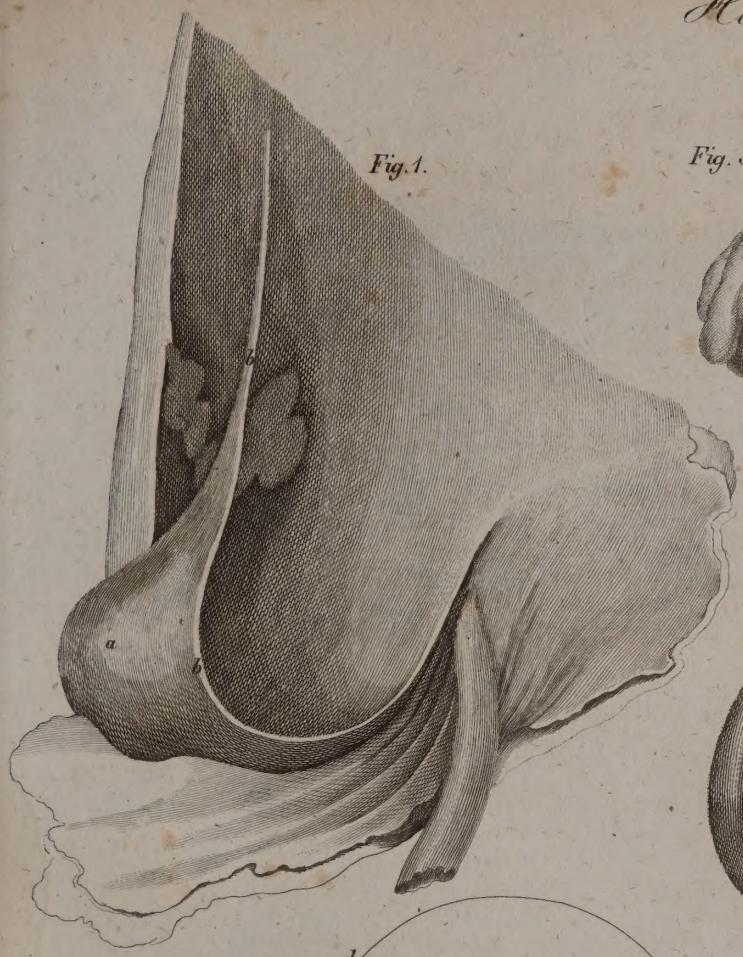

Fig. 3.

Fig. 2.

Fig. 4.

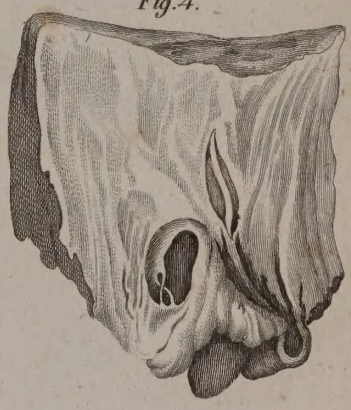

Fig. 5.

Fig. 6.

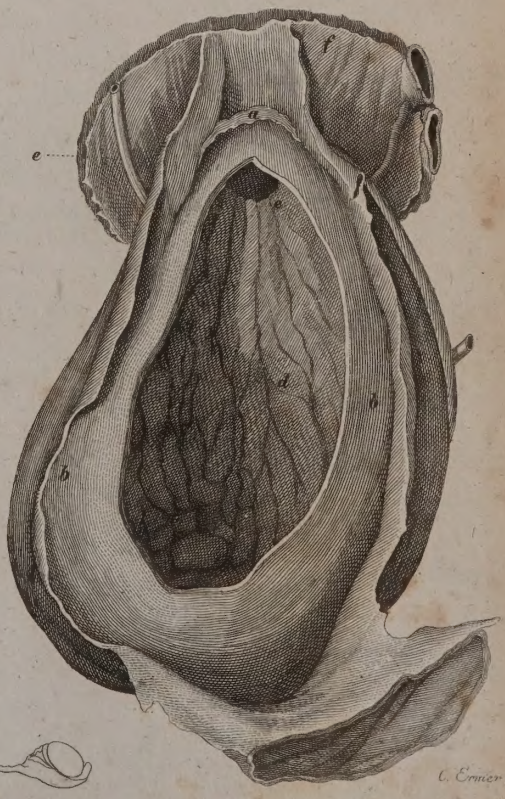

Fig. 7.

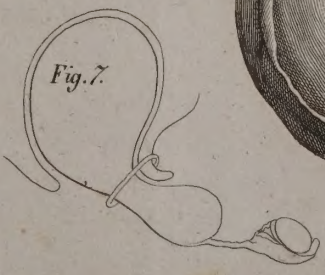

C. Ermer fc.

nach Sir Astley Cooper.

Syphilis.

Fig. 1.

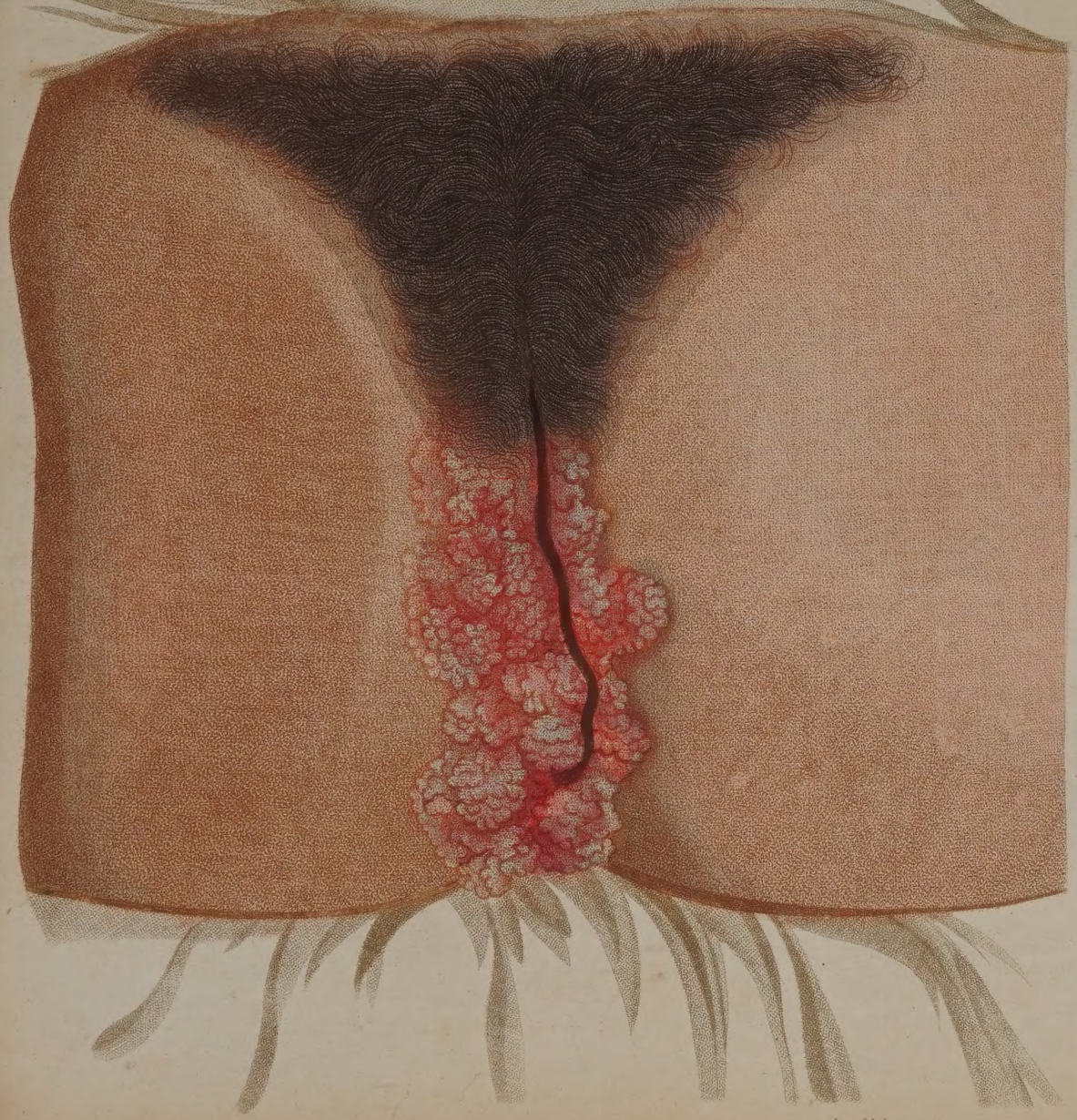

Fig. 2.

ad. Albert

Fig. 1.

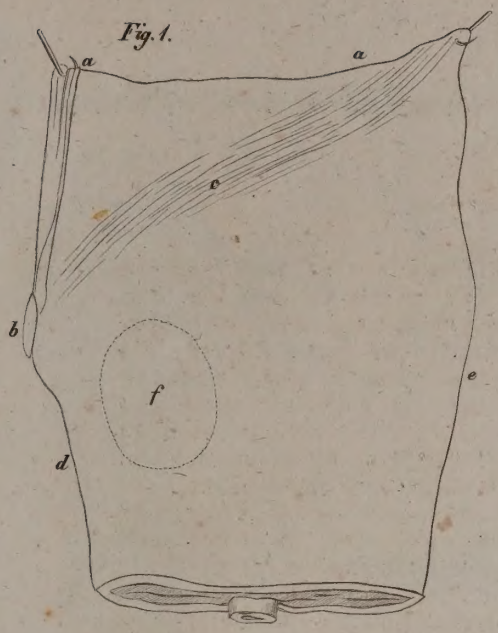

Fig. 2.

Fig. 3.

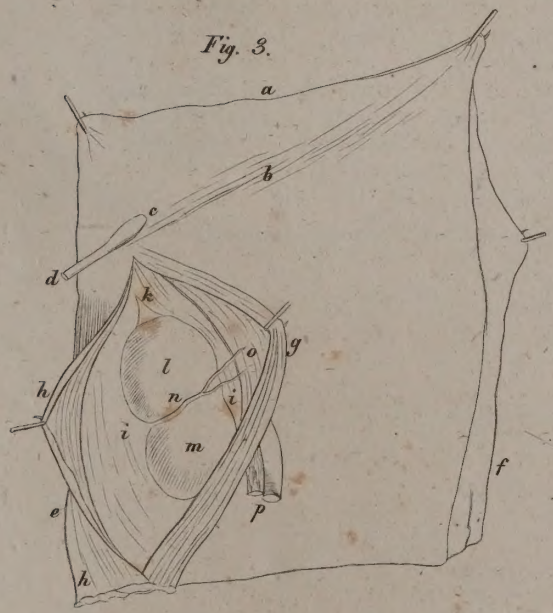

Fig. 4

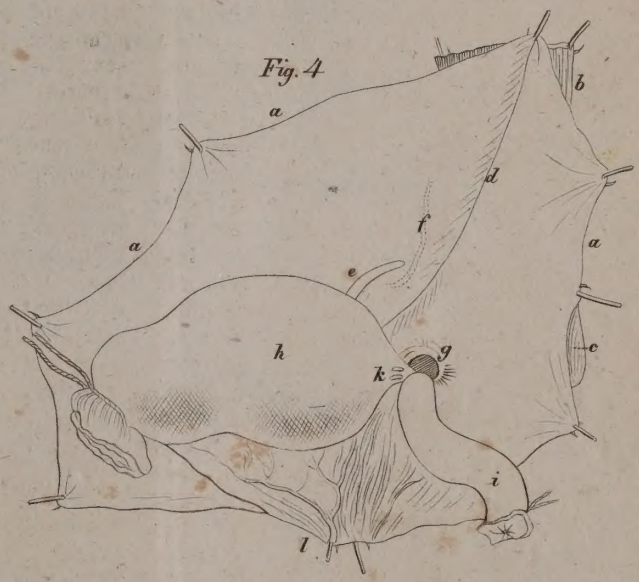

Fig. 5.

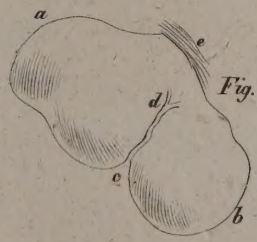

Fig. 6.

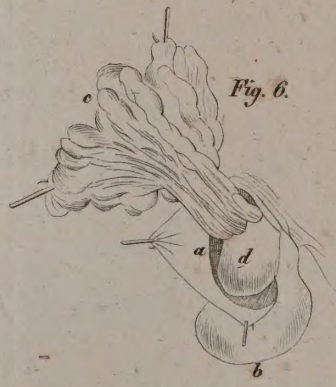

nach Jules Cloquet.

Apparatus lithontripticus.

Fig. 1.

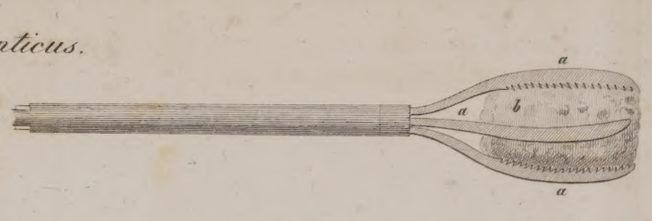

Fig. 2.

Fig. 3.



Fig. 4.



Fig. 5.

Fig. 6.

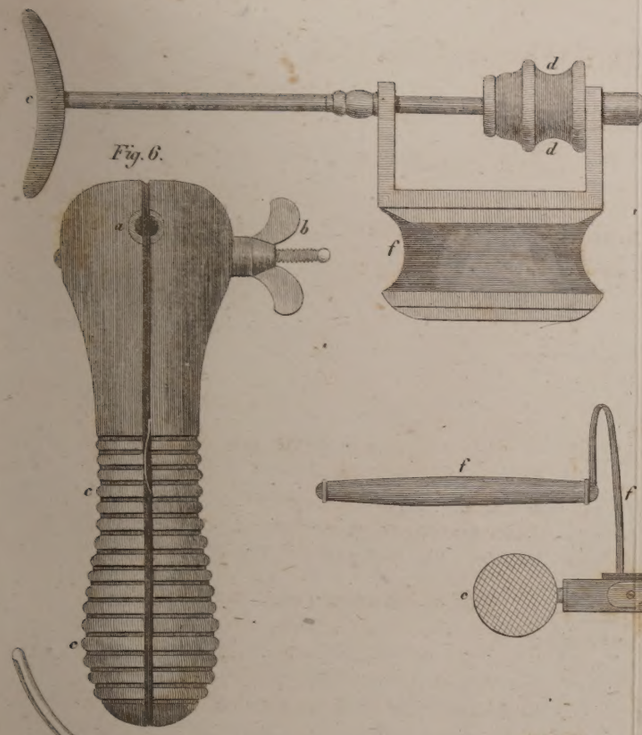

Fig. 7.



Fig. 8.



Fig. 9.



Fig. 10.

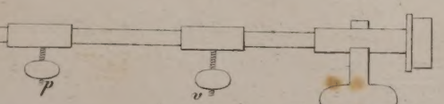

Fig. 11.



Fig. 12.



Fig. 13.



Fig. 14.



Fig. 16.



Fig. 15.



nach Amussat, Leroy und Elderdon.

Apparatus lithontripticus.

Fig. 1.



Fig. 2.



Fig. 3.



Fig. 4.



Fig. 5.

Fig. 6.

Fig. 7.



Fig. 8.

Fig. 9.



Fig. 10.



Fig. 11.

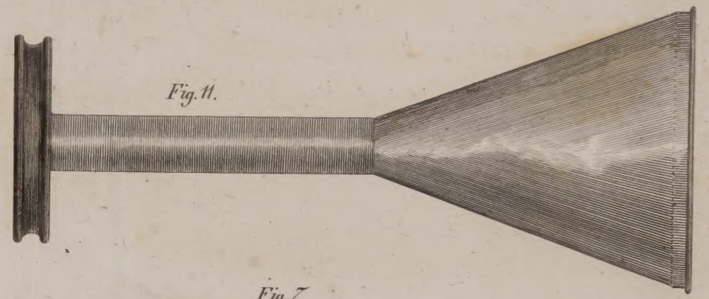

Fig. 12.



Fig. 13.



Fig. 14.



Fig. 17.

Fig. 16.

Fig. 15.

nach Tanchou.

Ectropium.

Fig. 1.

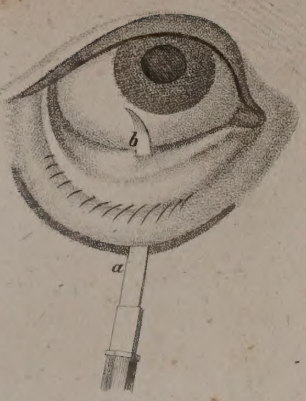

Fig. 2.

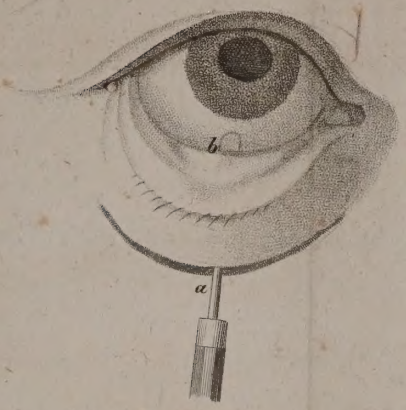

Fig. 3.



Fig. 4. a



Fig. 4. b

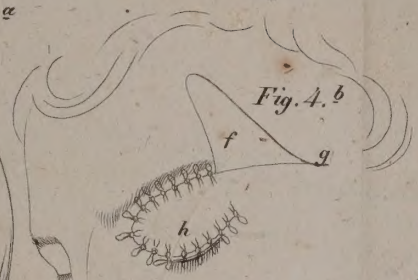

Fig. 5. b

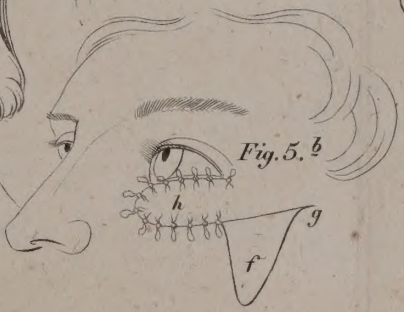

Fig. 5. a

Fig. 6.

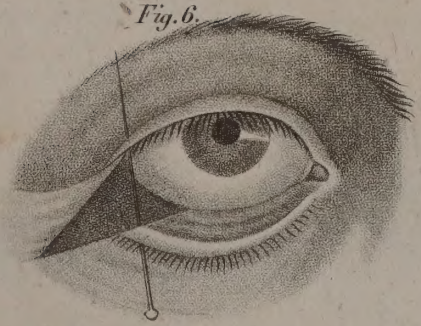

Fig. 7.

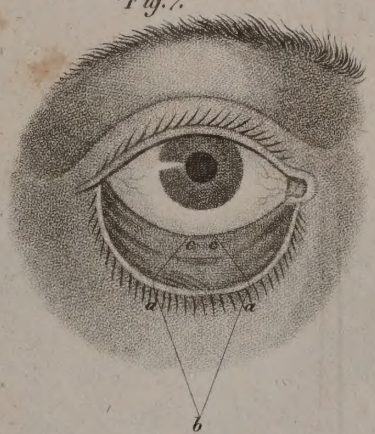

Fig. 8.

Fig. 9.

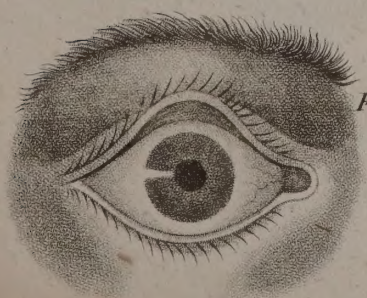

Fig. 10.

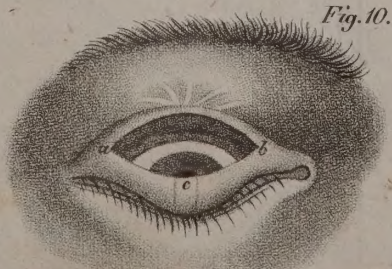

Fig. 11.

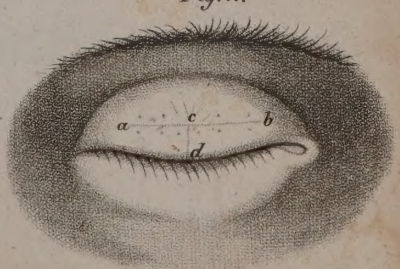

Fig. 5.

Fig. 2.

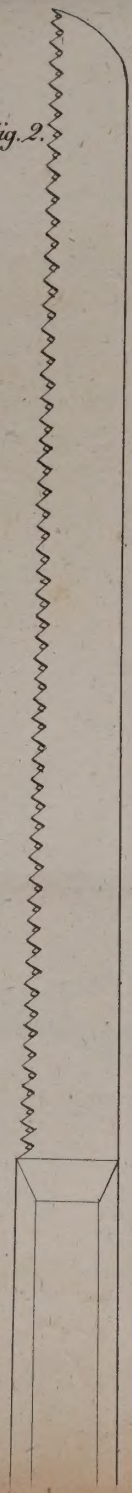

Fig. 1.

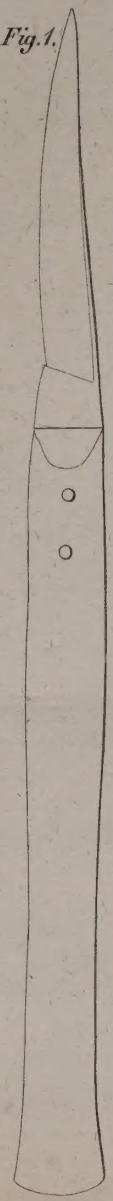

Fig. 6.



Fig. 7.

Fig. 3.

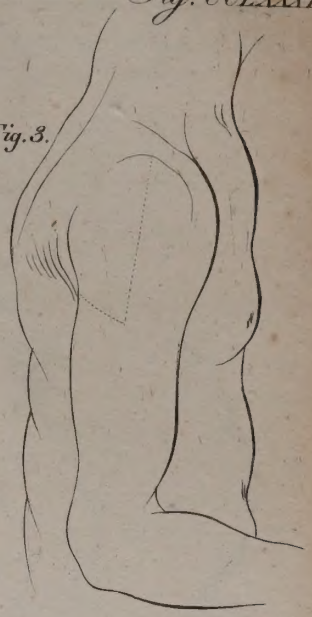

Fig. 11.



Fig. 4.

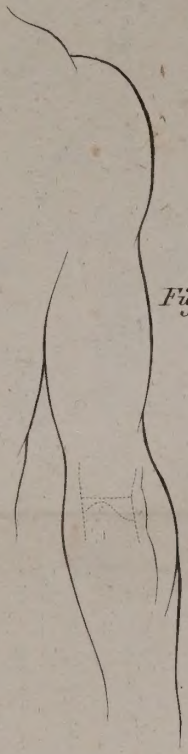

Fig. 8.

Fig. 9.

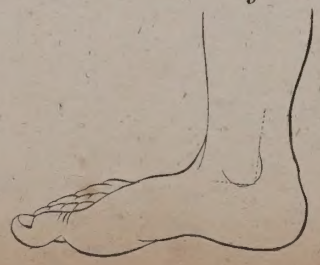

Fig. 10.

nach Syme.

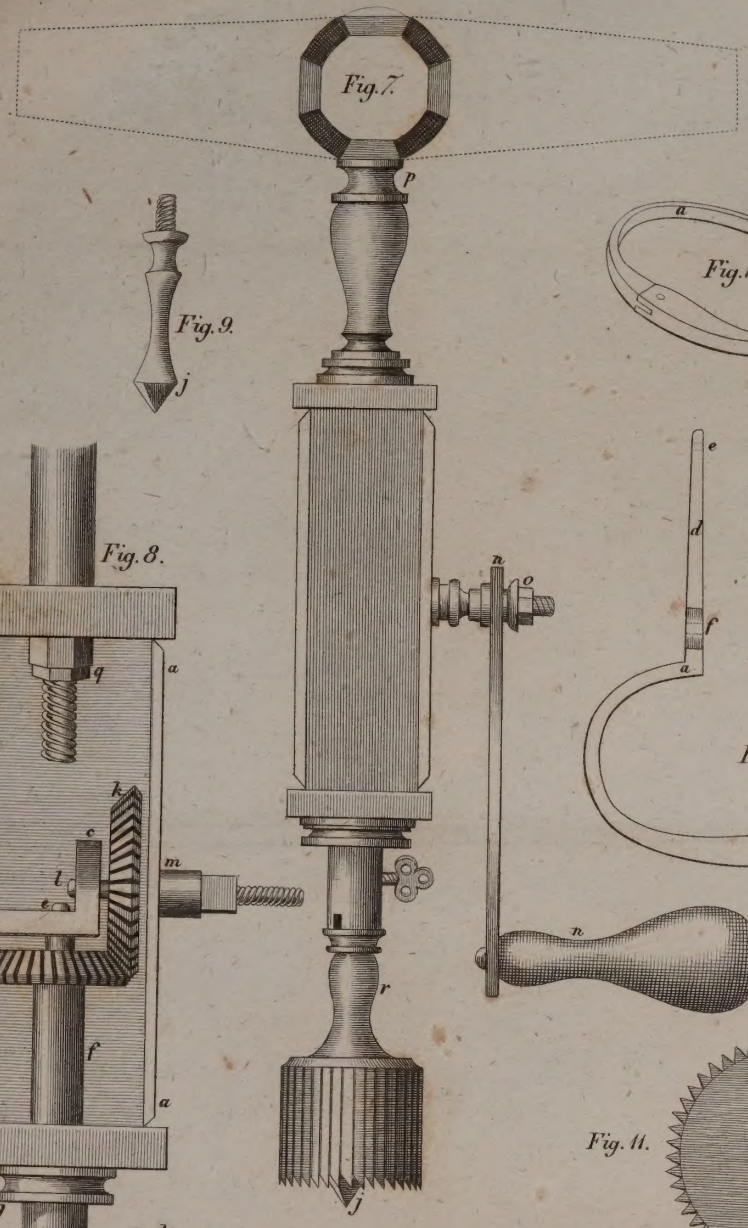
Fig. 7.
p
Fig. 9.
j
Fig. 8.
a
q
k
c
t
b
e
m
d
f
g
h
i
n
o
r
j

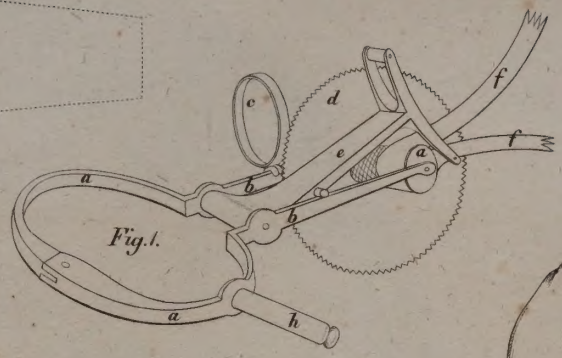
Fig. 1.
c
d
f
e
a
b
h

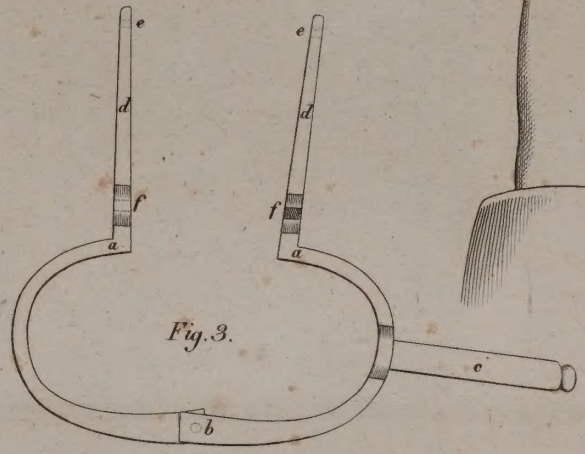
Fig. 3.
e
d
f
a
c
b

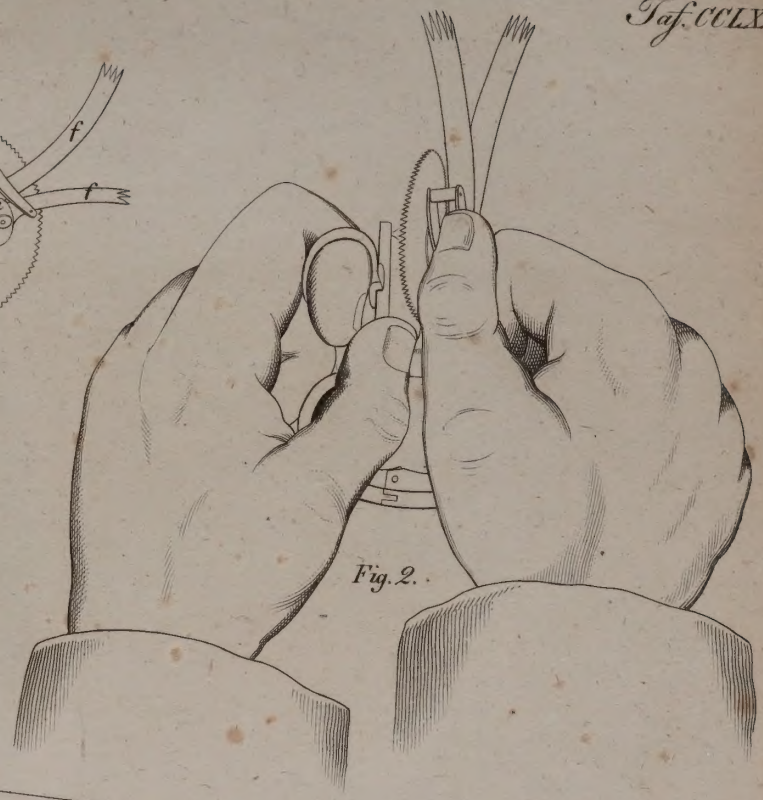
Fig. 2.

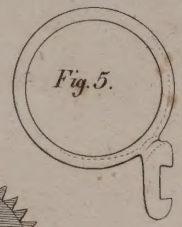
Fig. 5.

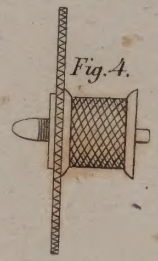
Fig. 4.

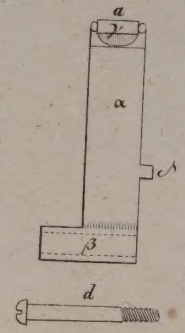
a
α
β
d

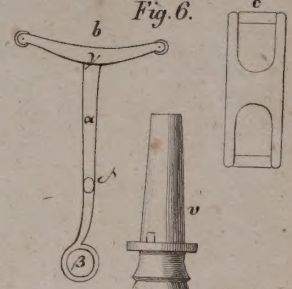
Fig. 6.
b
α
β
c

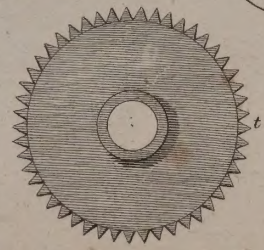
Fig. 11.
t


Fig. 12.
x

v
u
Fig. 10.
t
w

Framboesia

Fig. 1.

Fig. 2.

nach Albert

Cataracta.

Taf. CCLXXVIII.

Fig. 1.

Fig. 2.

Fig. 3. a.

Fig. 3. b.

Fig. 3. c.

Fig. 4. a.

Fig. 4. b.

Fig. 5.

Fig. 6. a.

Fig. 6. b.

Fig. 7.

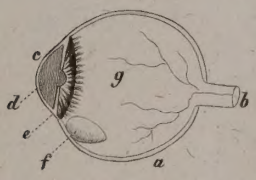

Fig. 8.

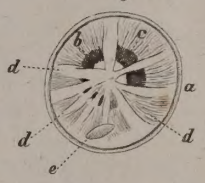

Fig. 9.

Fig. 10.

Fig. 11.

Verletzungen der Arterien.

Fig. 1.

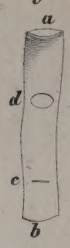

Fig. 2.

Fig. 3.



Fig. 4.



Fig. 5.



Fig. 6.

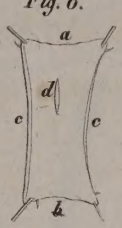

Fig. 7.



Fig. 8.

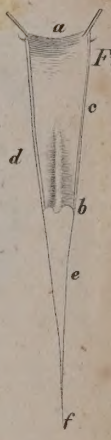

Fig. 9.

Fig. 10.

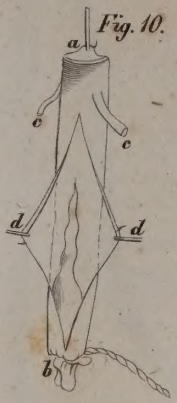

Fig. 13.

Fig. 14.

Fig. 15.

Fig. 11.

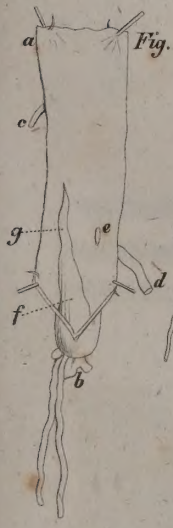

Fig. 12.

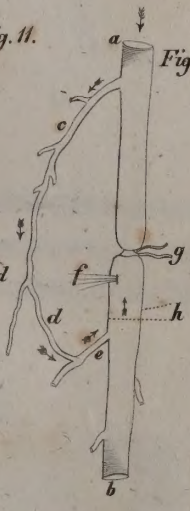

Fig. 21.

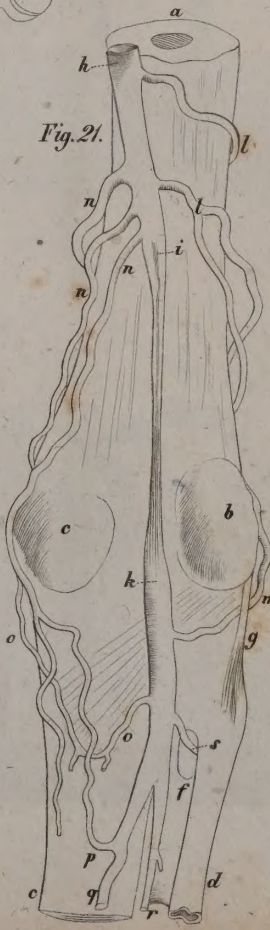

Fig. 16.

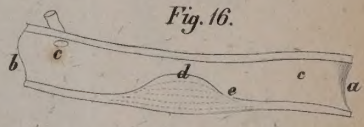

Fig. 17.

Fig. 18.

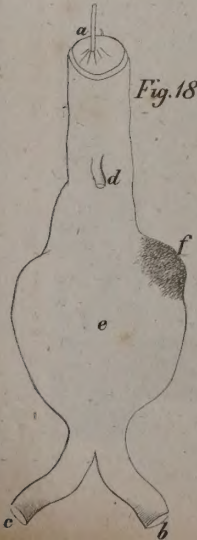

Fig. 19.

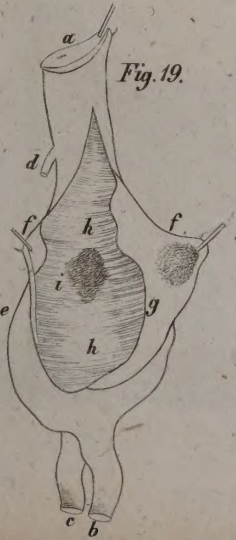

Fig. 20.

Fig. 22.

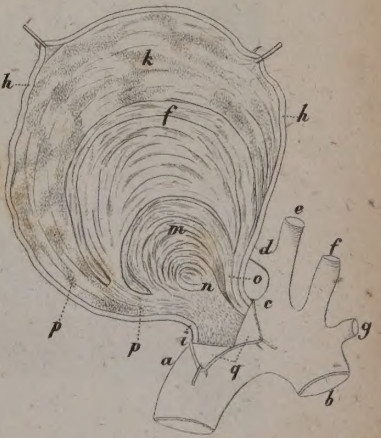

Fractura.

Fig. 4.



Fig. 5.

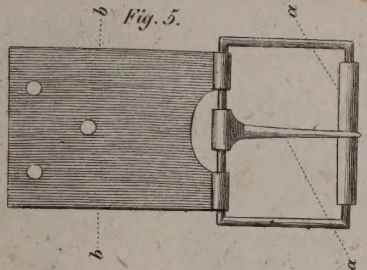

Fig. 3.

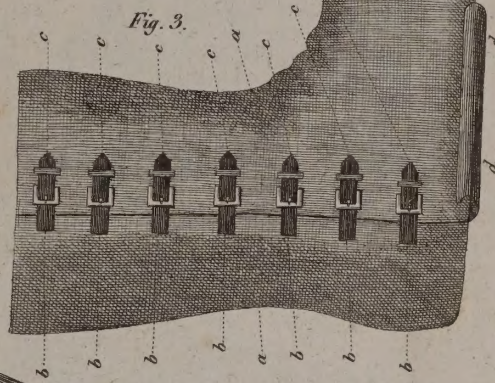

Fig. 2.

Fig. 1.

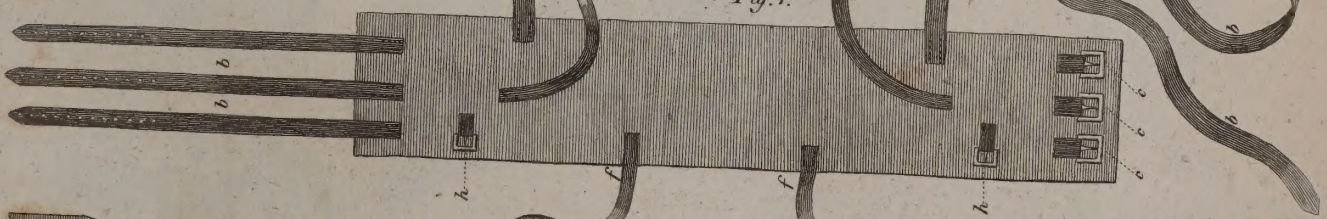

Fig. 6.

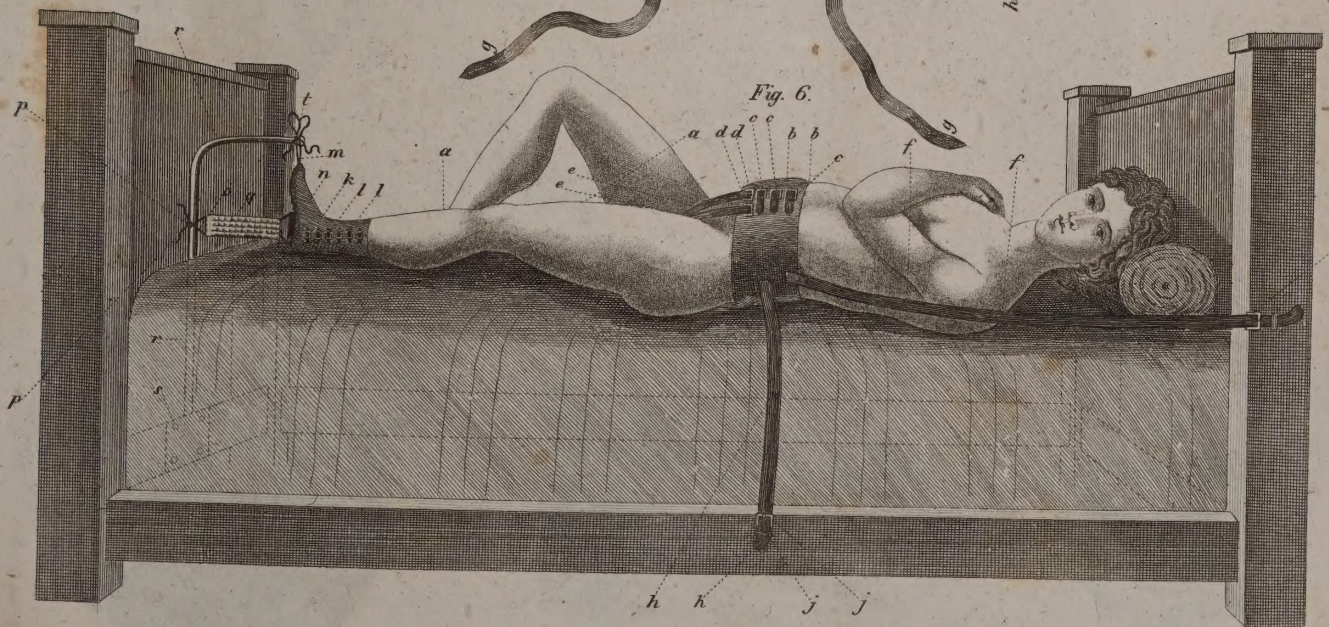

Hernia.

Fig. 1.

Fig. 3.

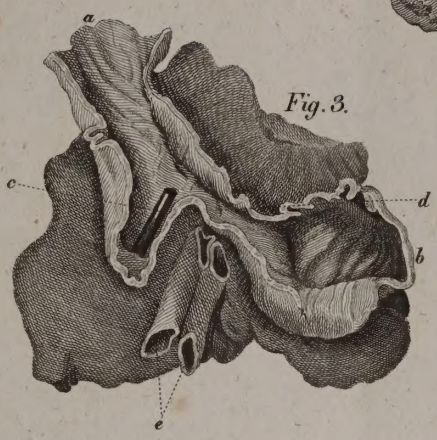

Fig. 2.

Fig. 4.

Fig. 5.

Fig. 6.

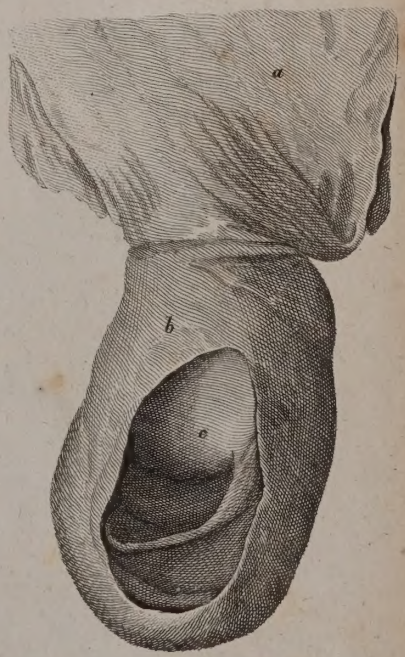

Fig. 7.

Exstirpatio maxillae superioris

Taf. CCXCII.

Fig. 1.

Fig. 2.

Fig. 3.

Fig. 4.

Fig. 5.

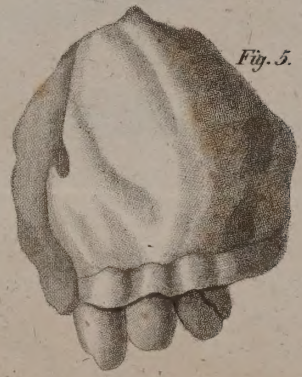

Prolapsus intestini recti.

Fig. 1.

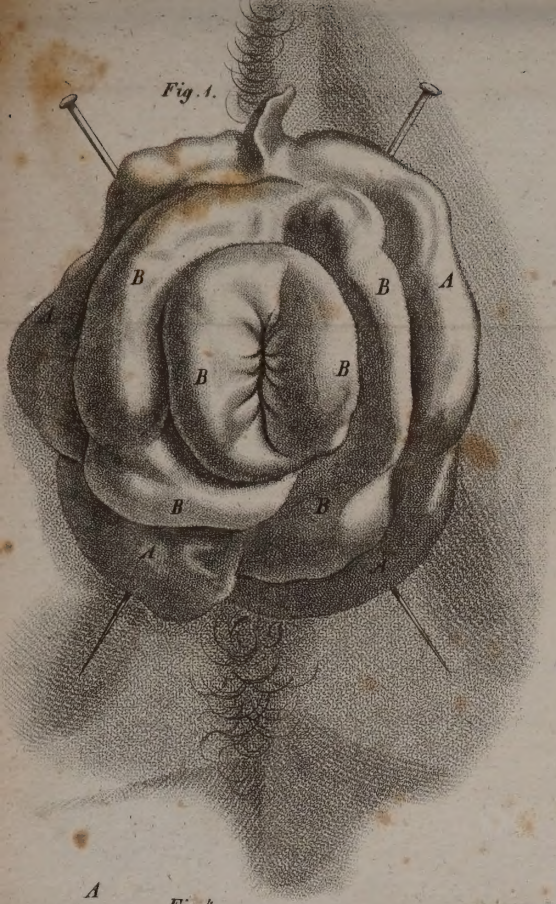

Fig. 2.

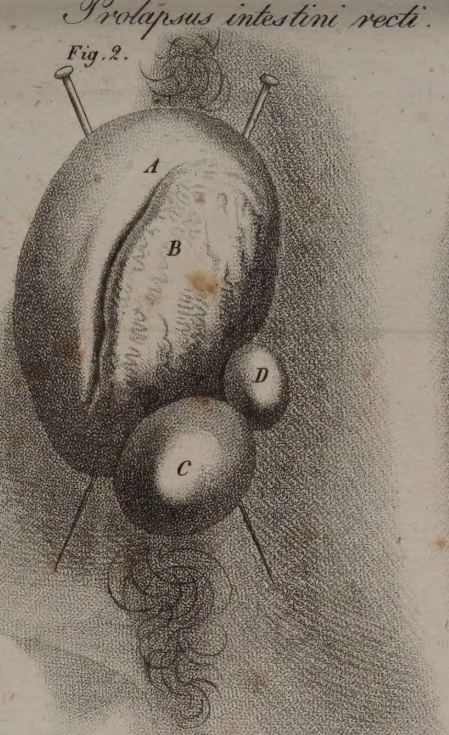

Fig. 3.

Fig. 4.

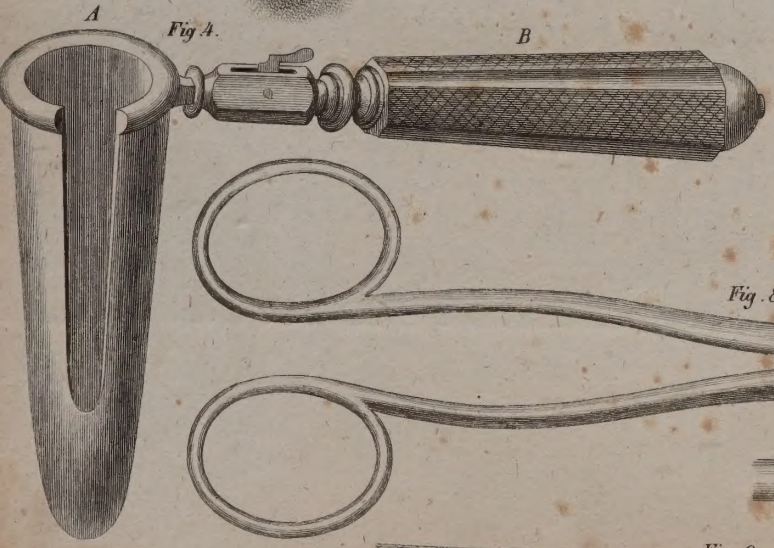

Fig. 5.



Fig. 7.

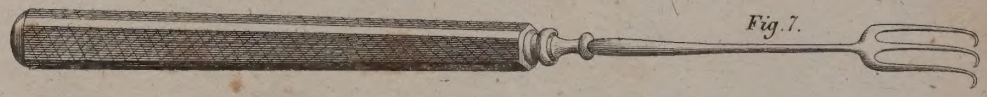

Fig. 8.

Fig. 6.



Fig. 8.a

Fig. 9.

Fig. 9.a



nach Salmon.

Apparatus lithontripticus.

Fig. 1.

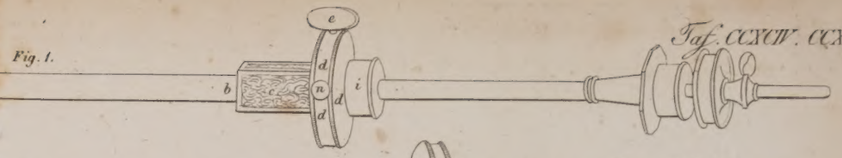

Fig. 2.

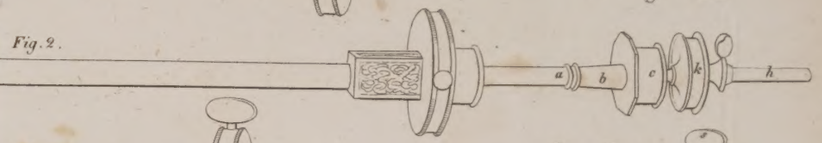

Fig. 10a

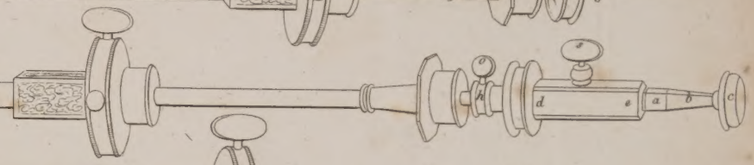

Fig. 11a

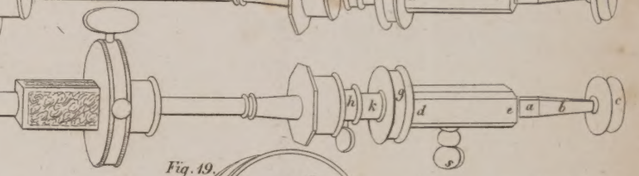

Fig. 19.

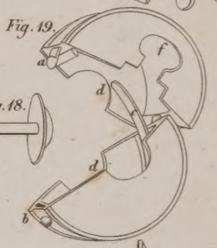

Fig. 20.

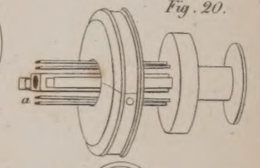

Fig. 18.

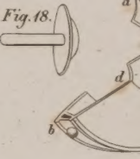

Fig. 24.

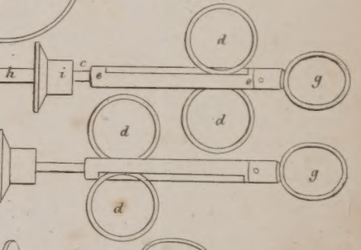

Fig. 27.

Fig. 29.

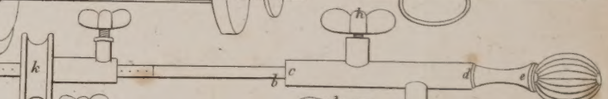

Fig. 32.

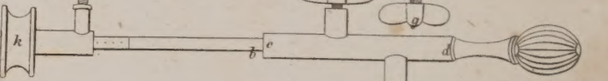

Fig. 34.



Fig. 26.

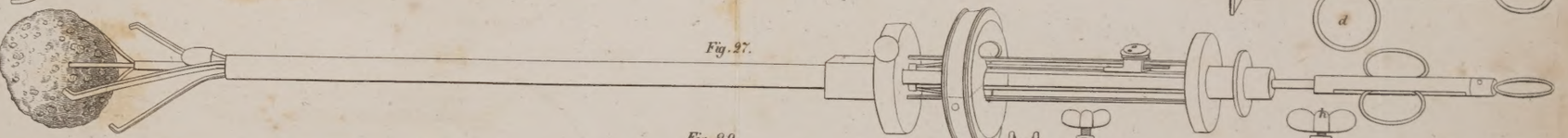

Fig. 17.



Fig. 21.



Fig. 23.

Fig. 22.

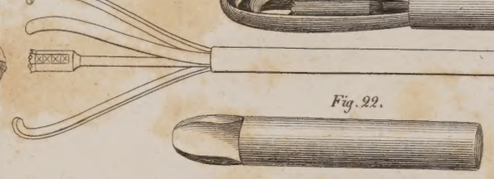

Fig. 25.

Fig. 8.

Fig. 9.

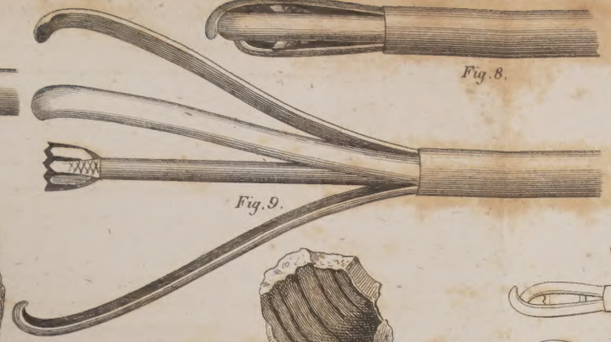

Fig. 14.

Fig. 4.

Fig. 7.

Fig. 5.

Fig. 3.

Fig. 6.

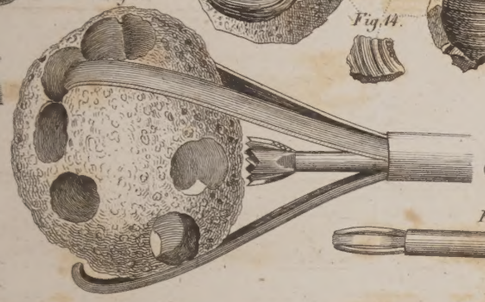

Fig. 12.

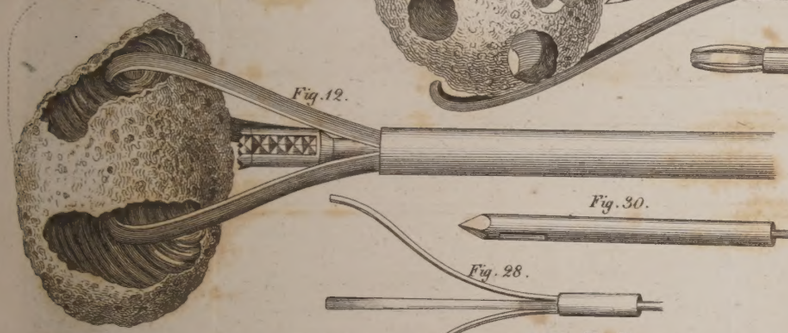

Fig. 30.

Fig. 28.

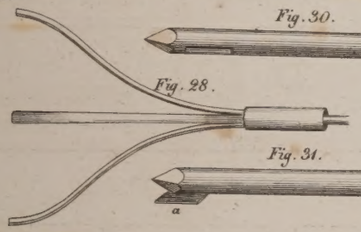

Fig. 31.



Fig. 13.

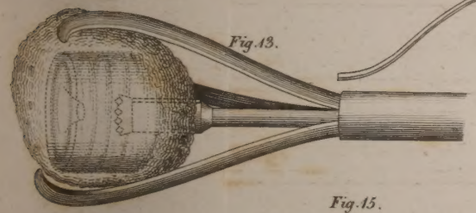

Fig. 33.

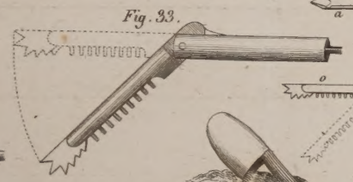

Fig. 15.

Fig. 11b

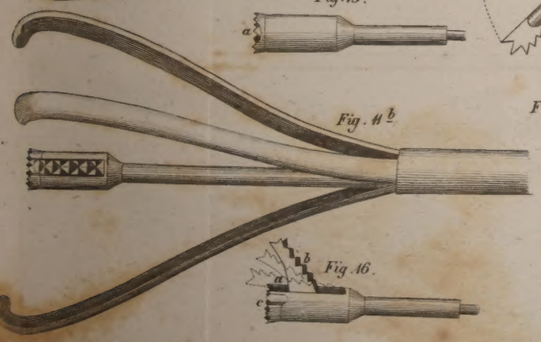

Fig. 16.

Fig. 37.

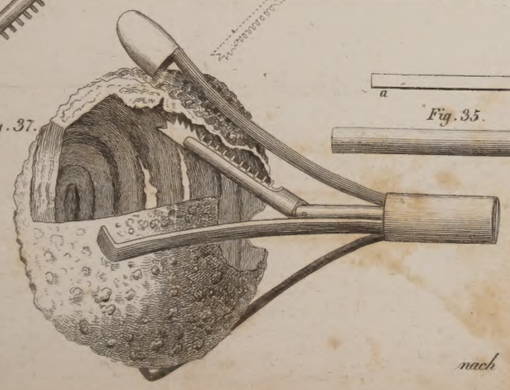

Fig. 35.



Fig. 36.

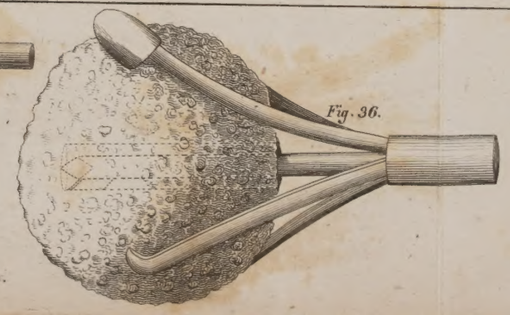

Fig. 38.

Fig. 39.

nach Heurteloup.

Apparatus lithontripticus.

Fig. 1.

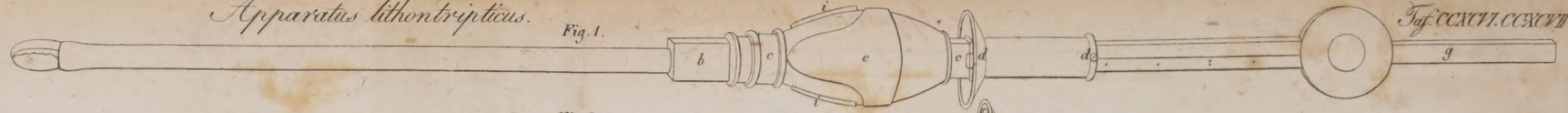

Fig. 2.

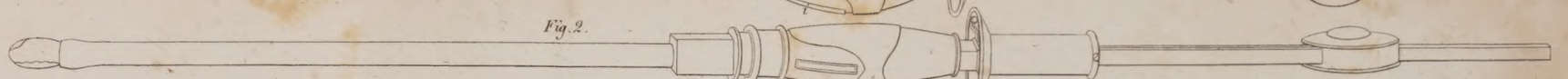

Fig. 3.

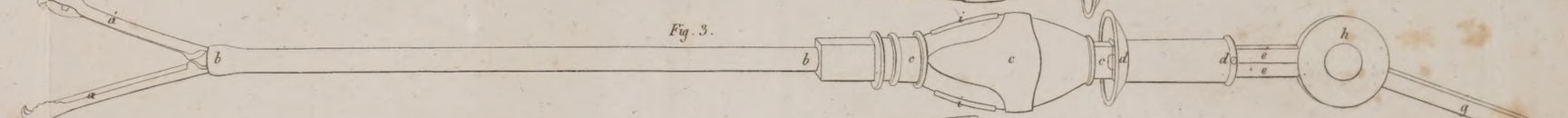

Fig. 4.

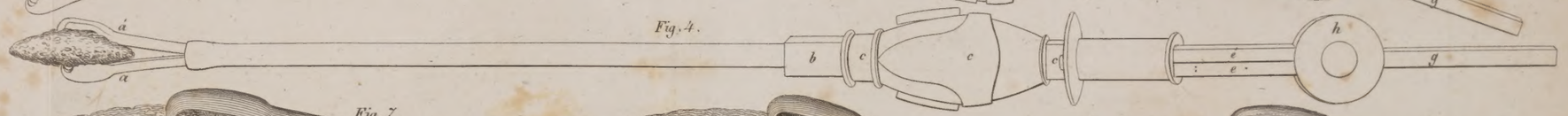

Fig. 5.

Fig. 6.

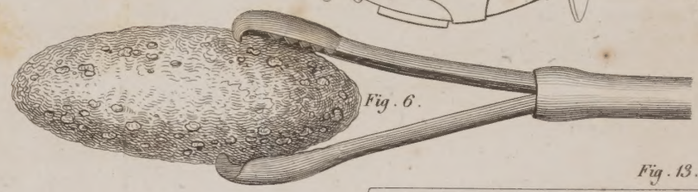

Fig. 7.

Fig. 8.

Fig. 9.

Fig. 10.

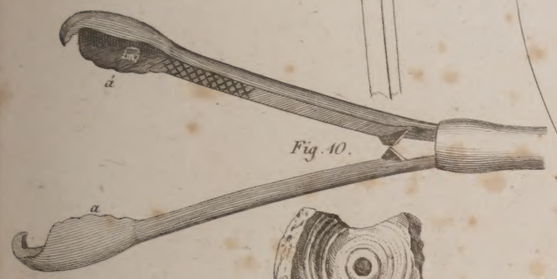

Fig. 11.



Fig. 12.



Fig. 13.



Fig. 14.

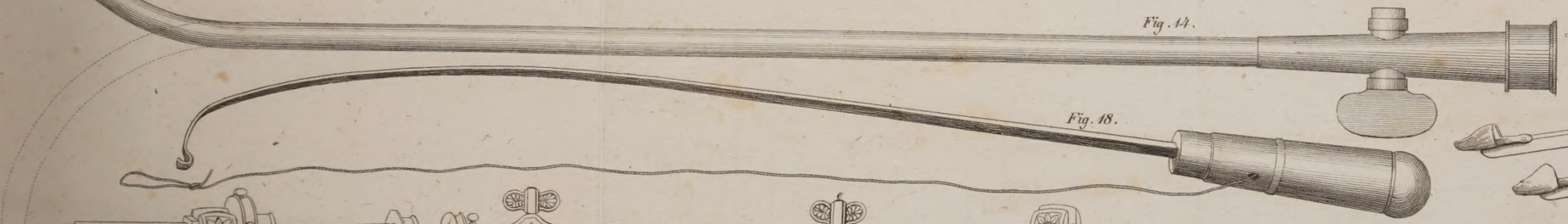

Fig. 15.

Fig. 16.



Fig. 17.

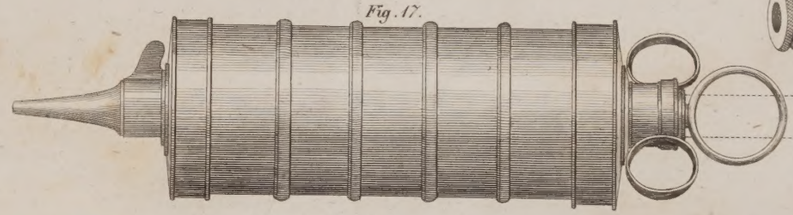

Fig. 18.

Fig. 19.

Fig. 20.



Fig. 21.

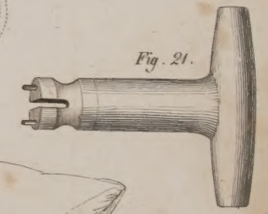

Fig. 22.

Fig. 23.



Fig. 24.

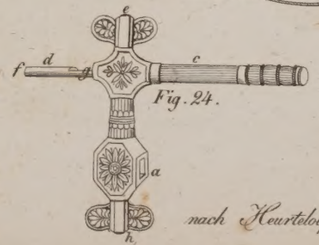

Fig. 25.

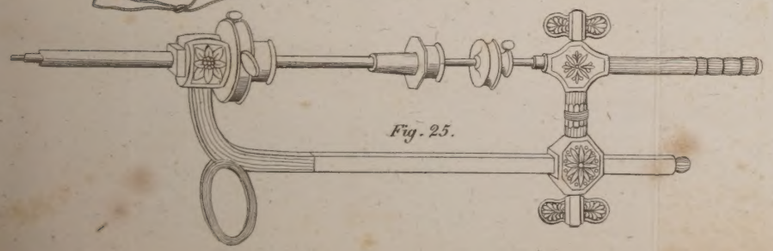

Fig. 26.

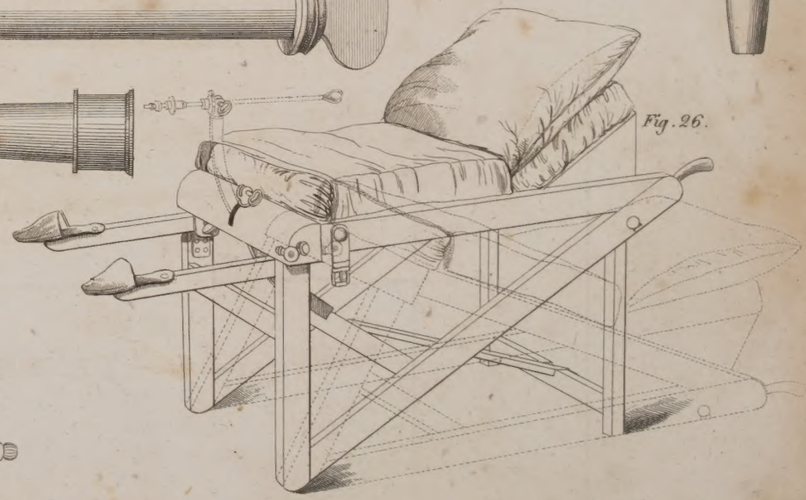

Fig. 27.

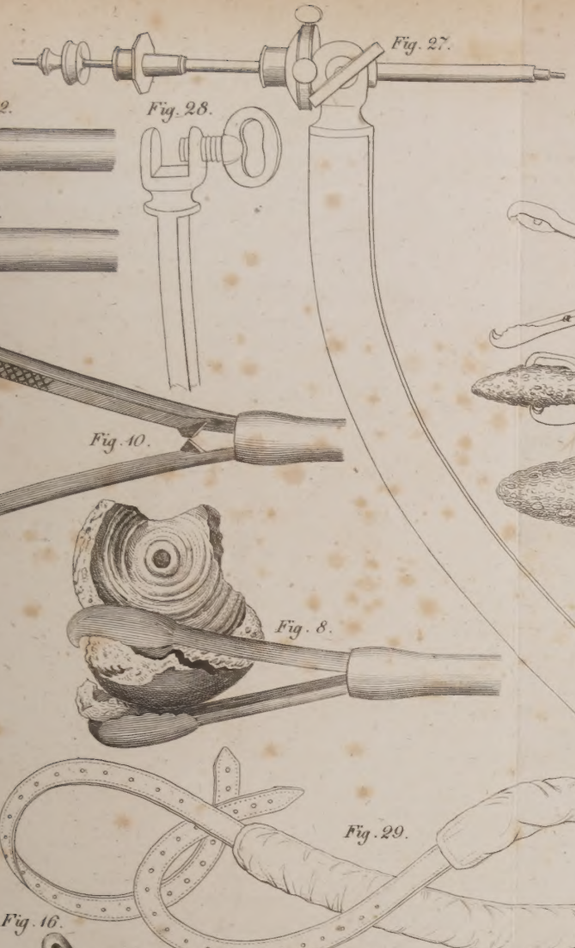

Fig. 28.

Fig. 29.

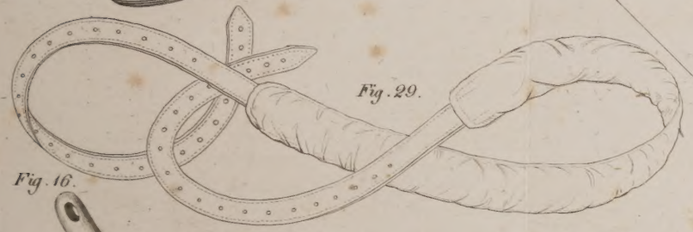

nach Heurteloup.

Fig. 1.

Fig. 2.

Fig. 3.



Fig. 1.

Fig. 2. A.

Fig. 2. B.

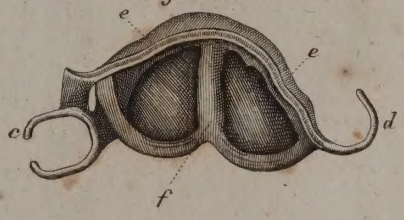

Fig. 7.

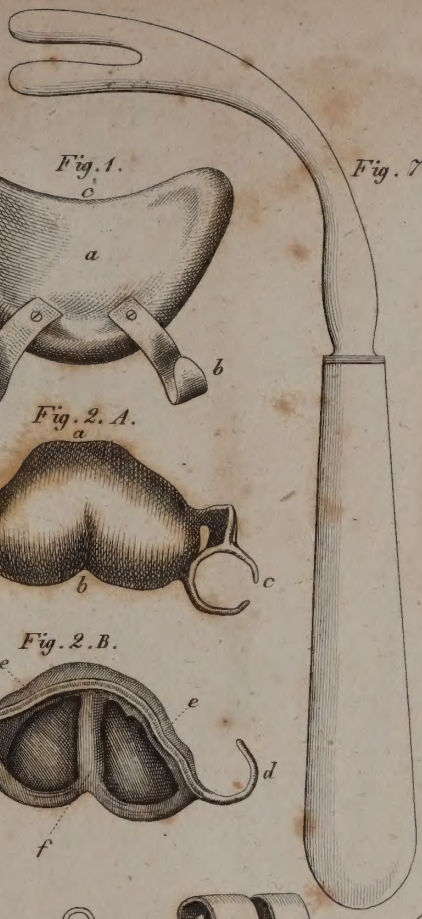

Fig. 9.

Fig. 8.

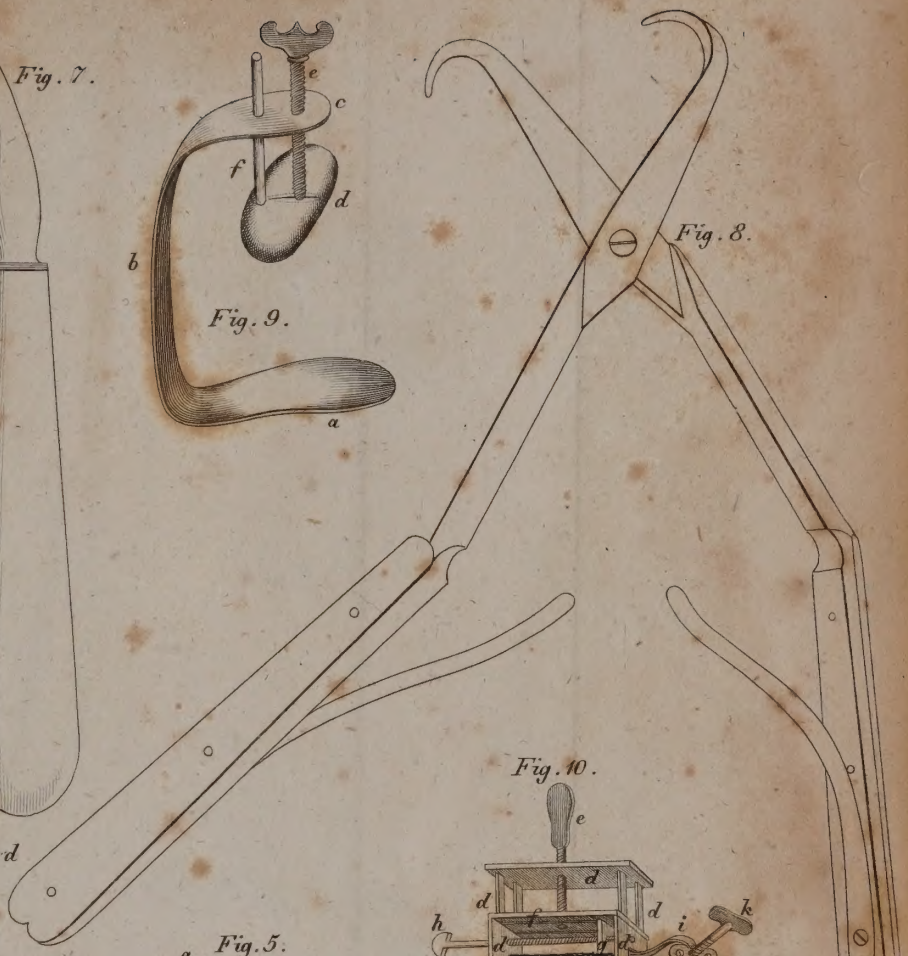

Fig. 10.

Fig. 4.

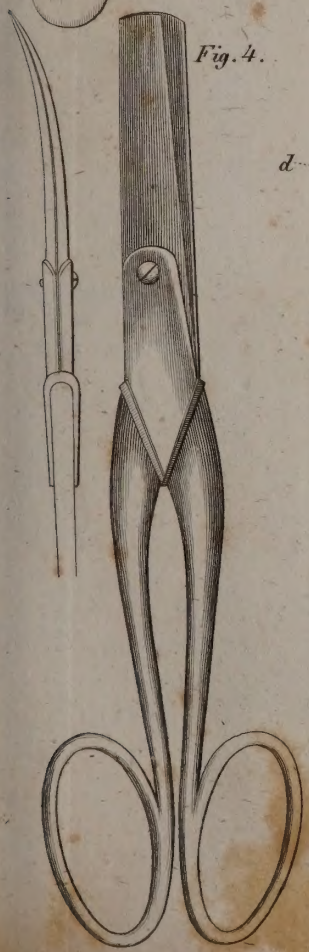

Fig. 6.

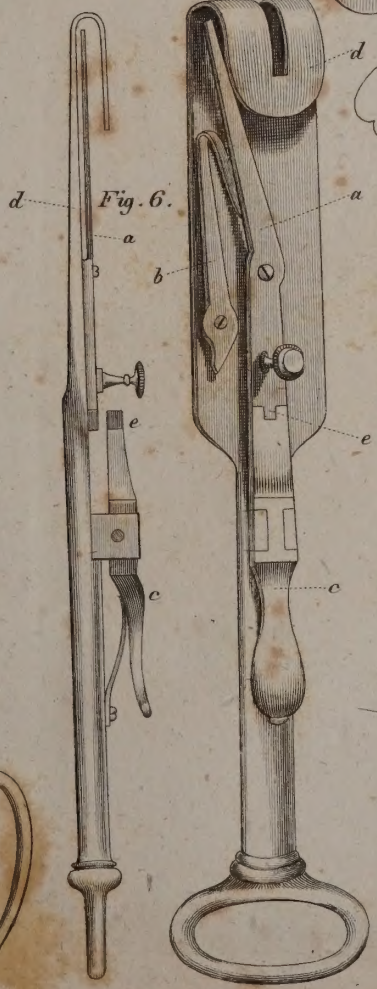

Fig. 5.

B
O
Fig. 1.
M
D
C
B
R
M
D
B
A
N
G
M
B
L
Q
P
A A
E
F
C


C E
D D
C
D

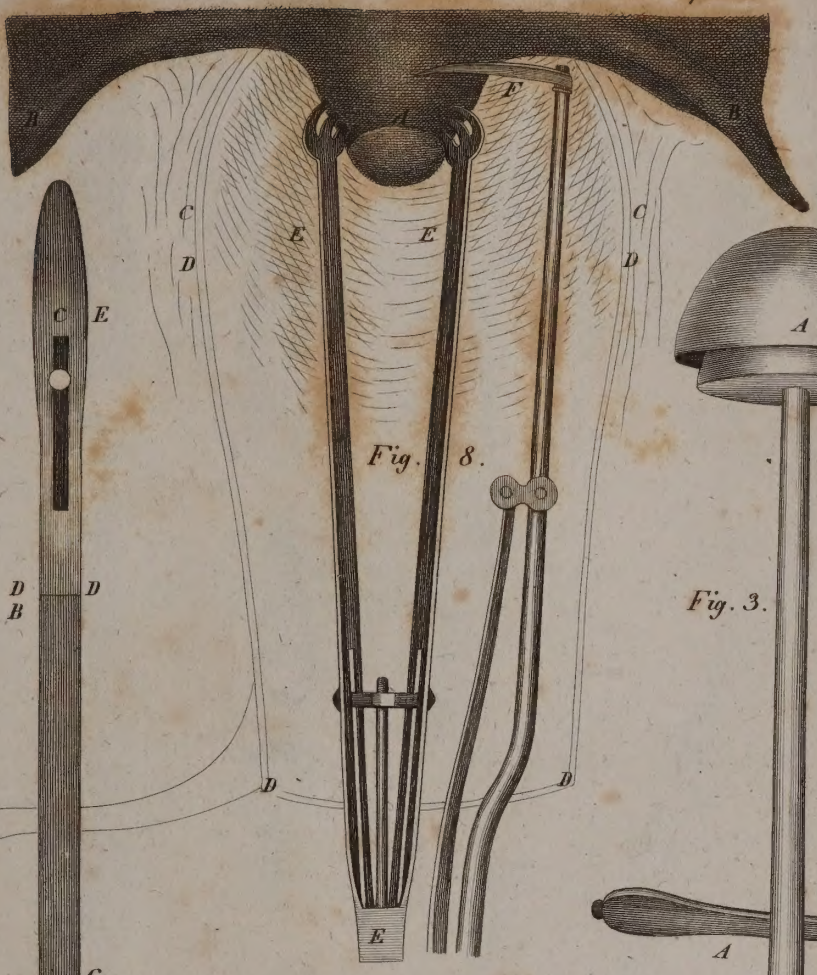
B
A
B
C
E
E
C
D
D
Fig. 8.
D
D
E

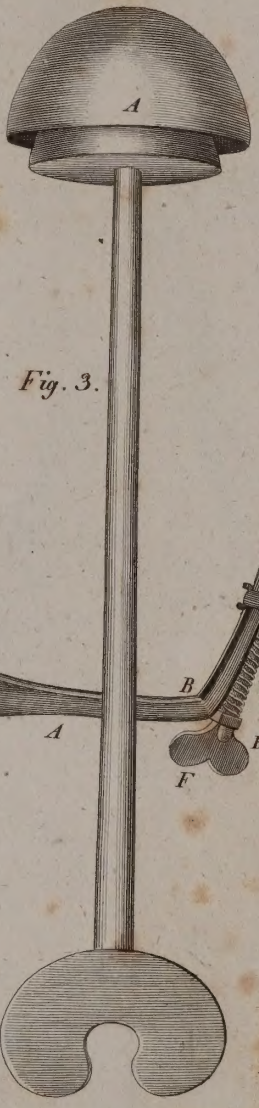
A
Fig. 3.
B
A
F


Fig. 2.
C C
G
B
B B B B B
B
D


Fig. 7.

Fig. 6.

Fig. 4.


D
B
A
F
Fig. 5.

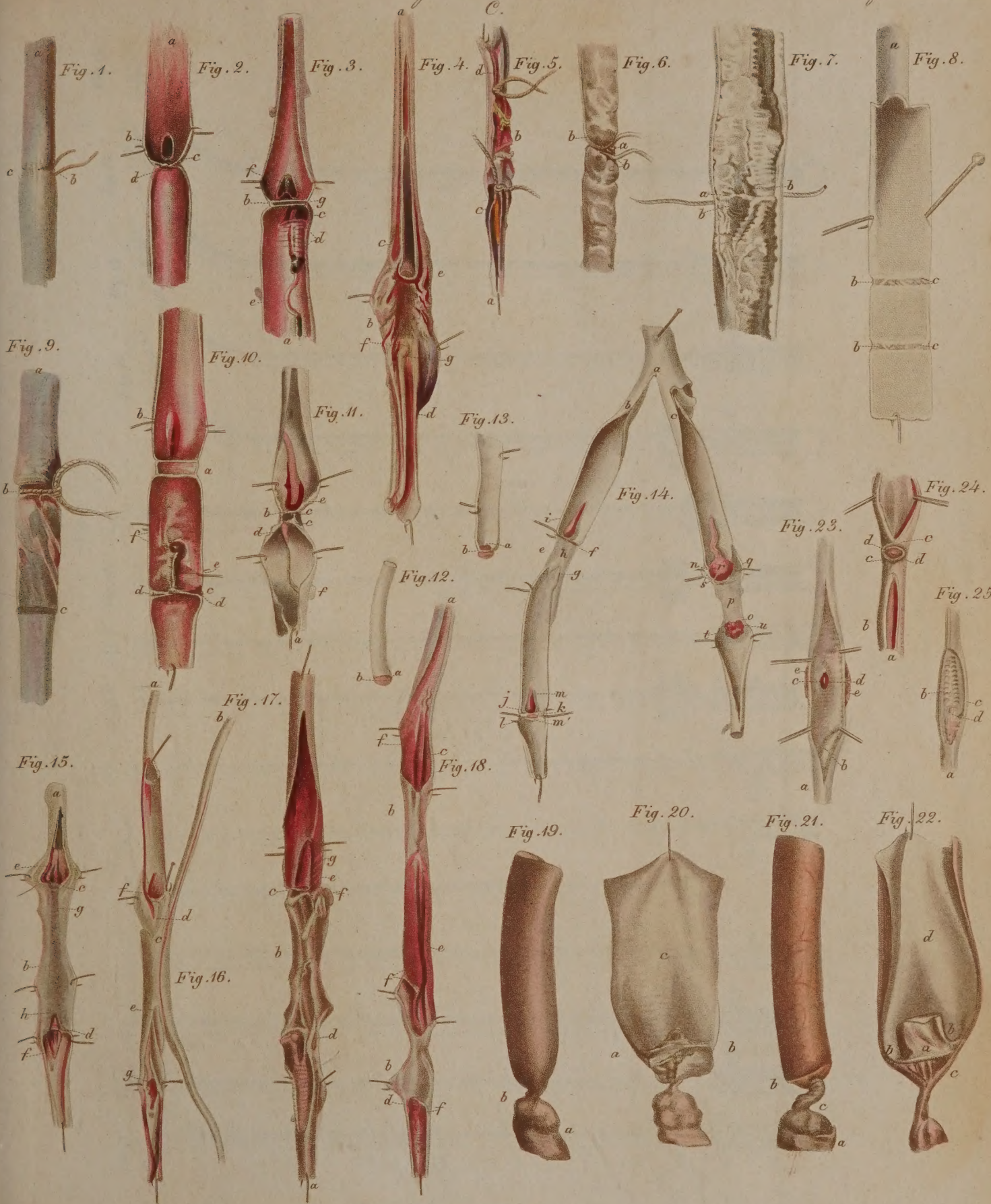
Fig. 1.
Fig. 2.
Fig. 3.
Fig. 4.
Fig. 5.
Fig. 6.
Fig. 7.
Fig. 8.
Fig. 9.
Fig. 10.
Fig. 11.
Fig. 12.
Fig. 13.
Fig. 14.
Fig. 15.
Fig. 16.
Fig. 17.
Fig. 18.
Fig. 19.
Fig. 20.
Fig. 21.
Fig. 22.
Fig. 23.
Fig. 24.
Fig. 25.

nach Manec

Stricturа urethrae

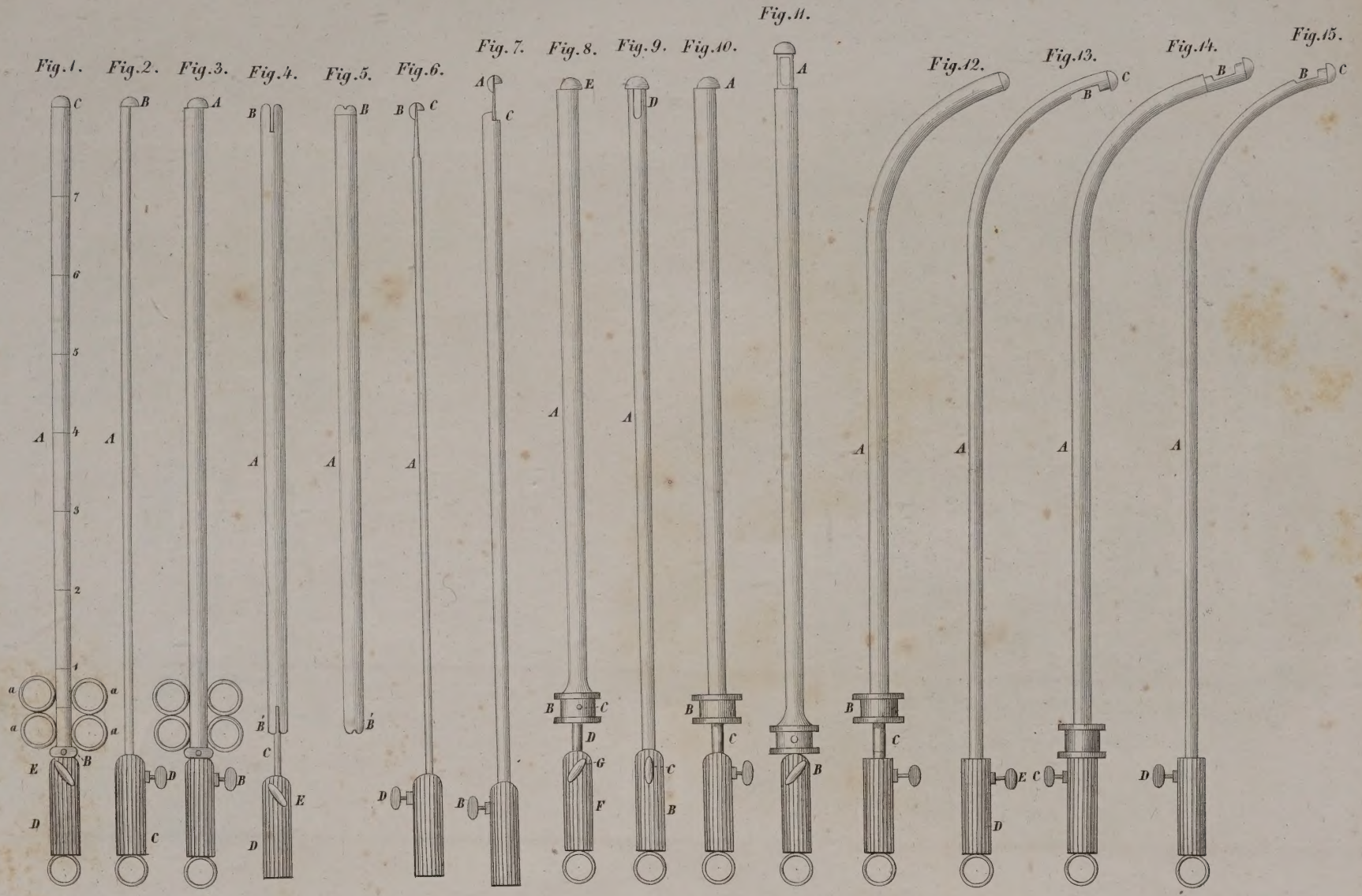

nach Amussat

Fig. 1.

Fig. 2.

nach Stevens.

Fig. 3.

Fig. 2.

Fig. 1.

Fig. 6.

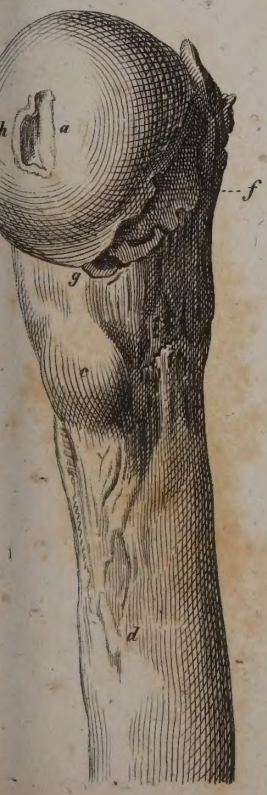

Fig. 5.

Fig. 4.

nach Sandifort.

Fig. 1.

Fig. 2.

Fig. 3.

nach A. T. Thomson.

Fig. 1.

Fig. 2.

Fig. 3.

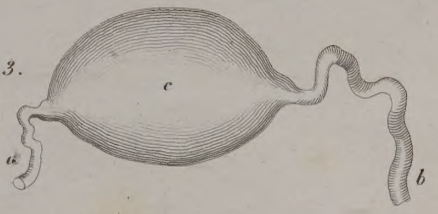

Fig. 4.

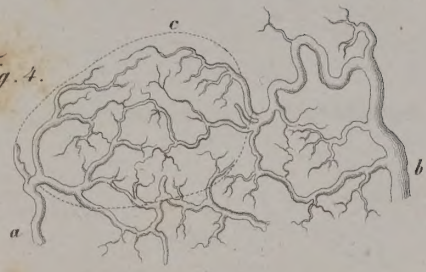

nach J. Bell.

Bronchocele.

A.

Fig. 1.

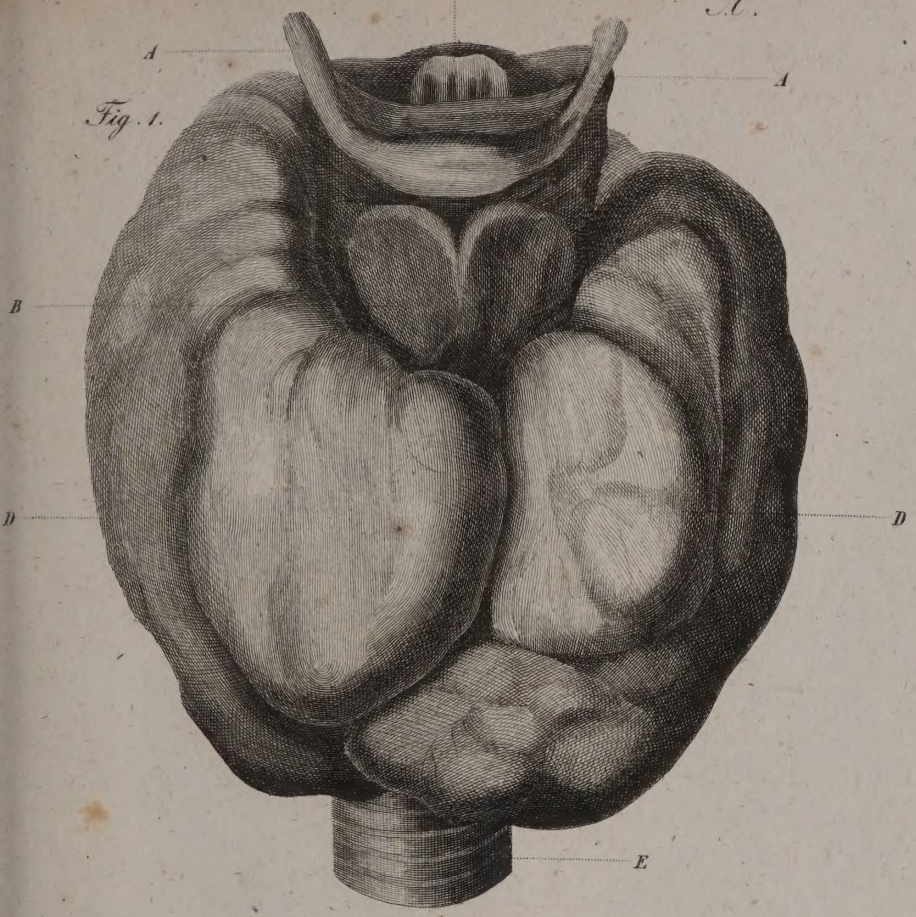

Fig. 2.

Fig. 3.

Fig. 4.

nach Baillie und Beck.

Hydrocele.

Fig. 1.

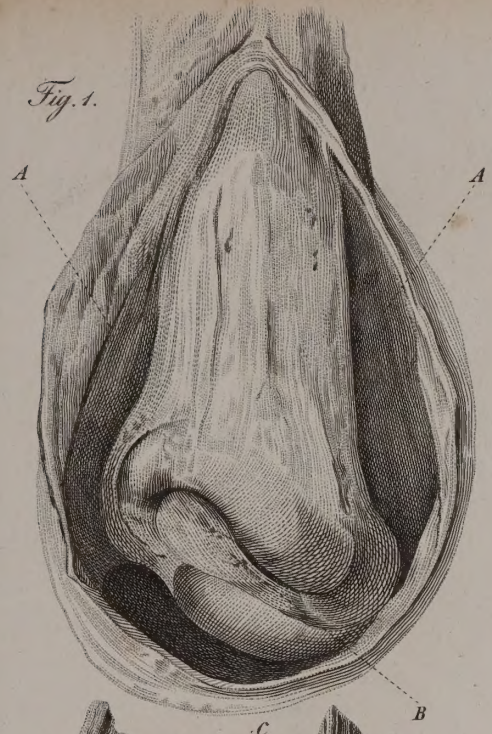

Fig. 5. (⅓n. G.)

Fig. 2.

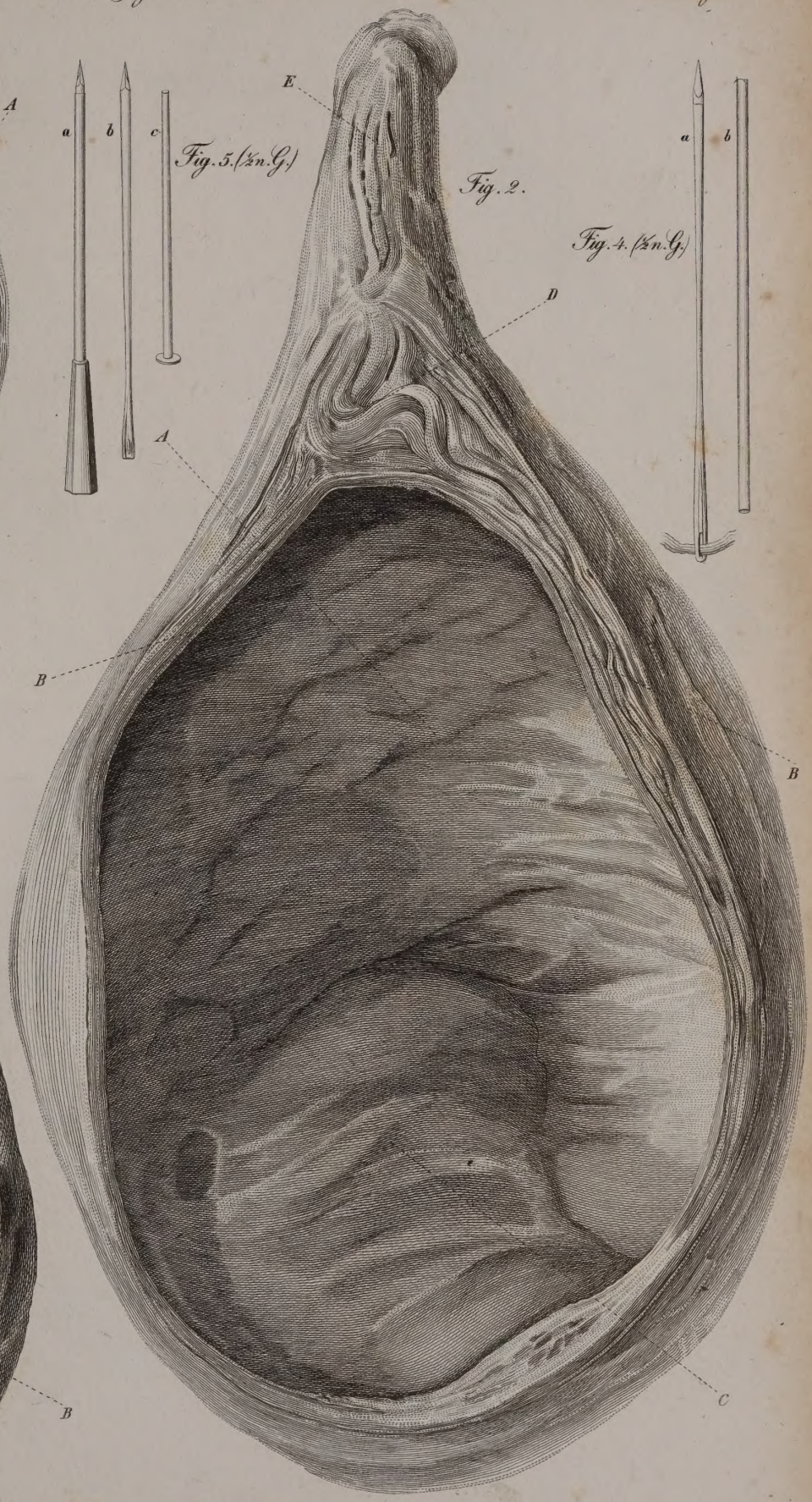

Fig. 4. (⅓n. G.)

Fig. 3.

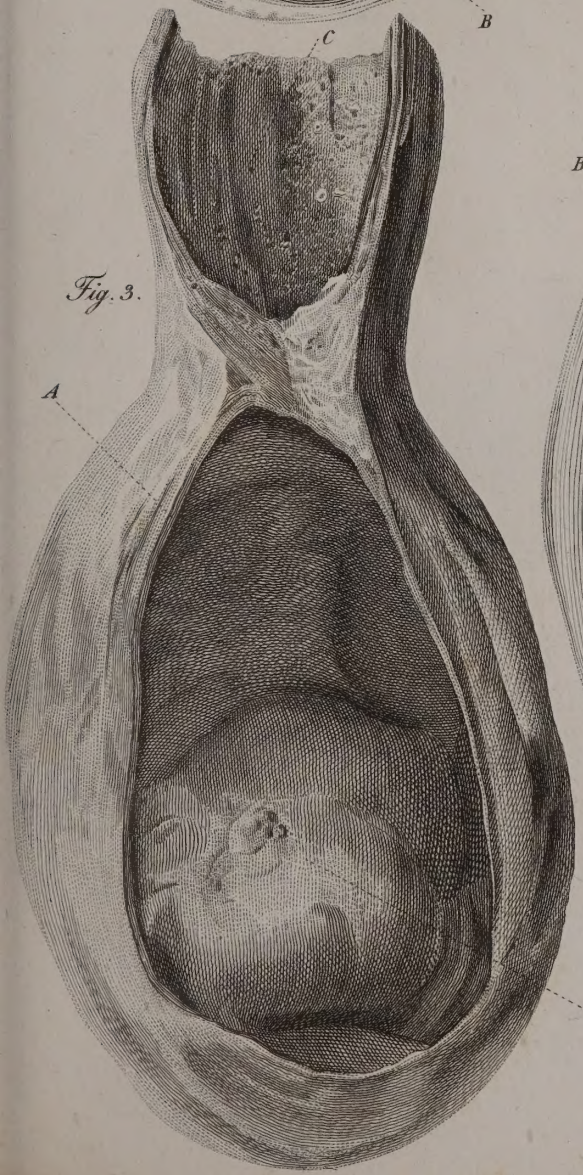

nach Baillie und Krombholtz.

Dr. Robert Froriep ad nat. pinx.

Fig. 1.

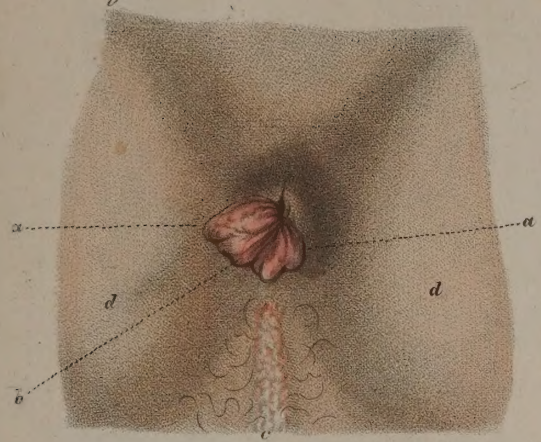

Fig. 2.

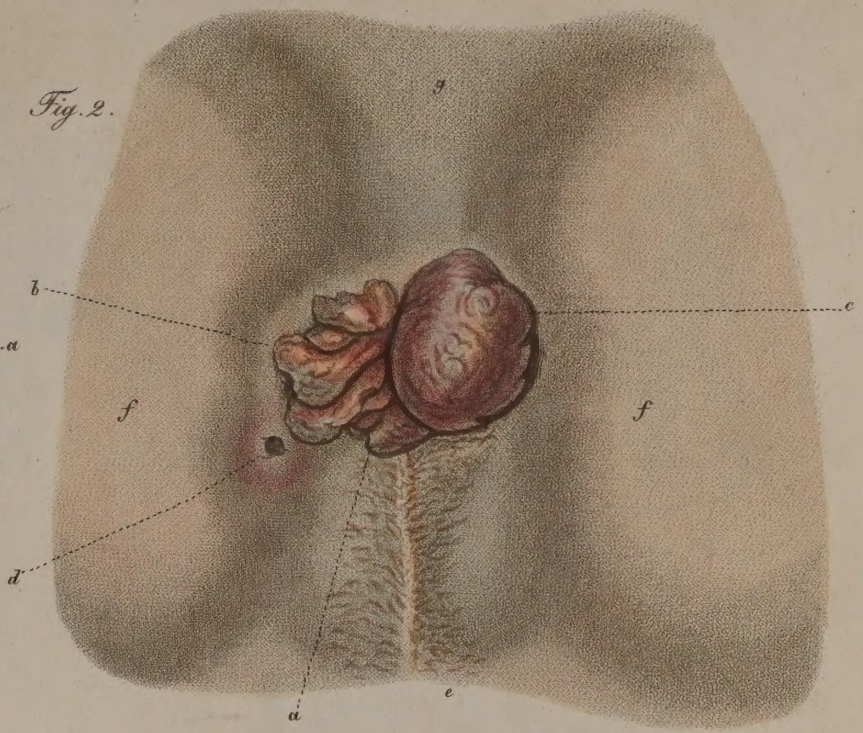

Fig. 5.

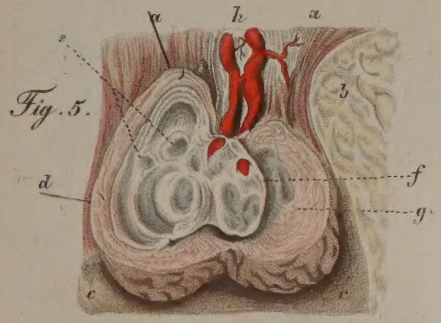

Fig. 4.

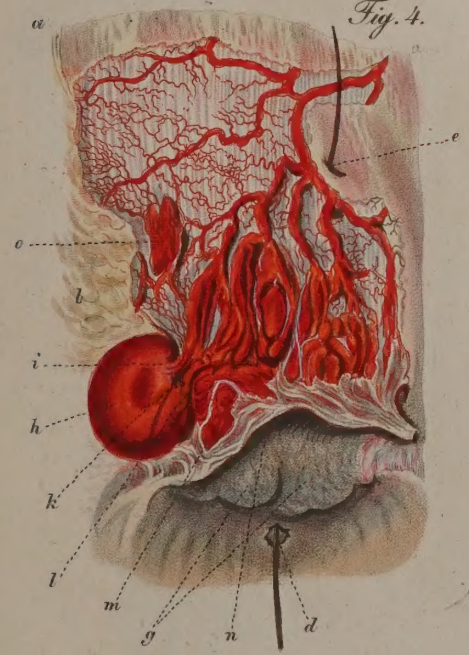

Fig. 3.

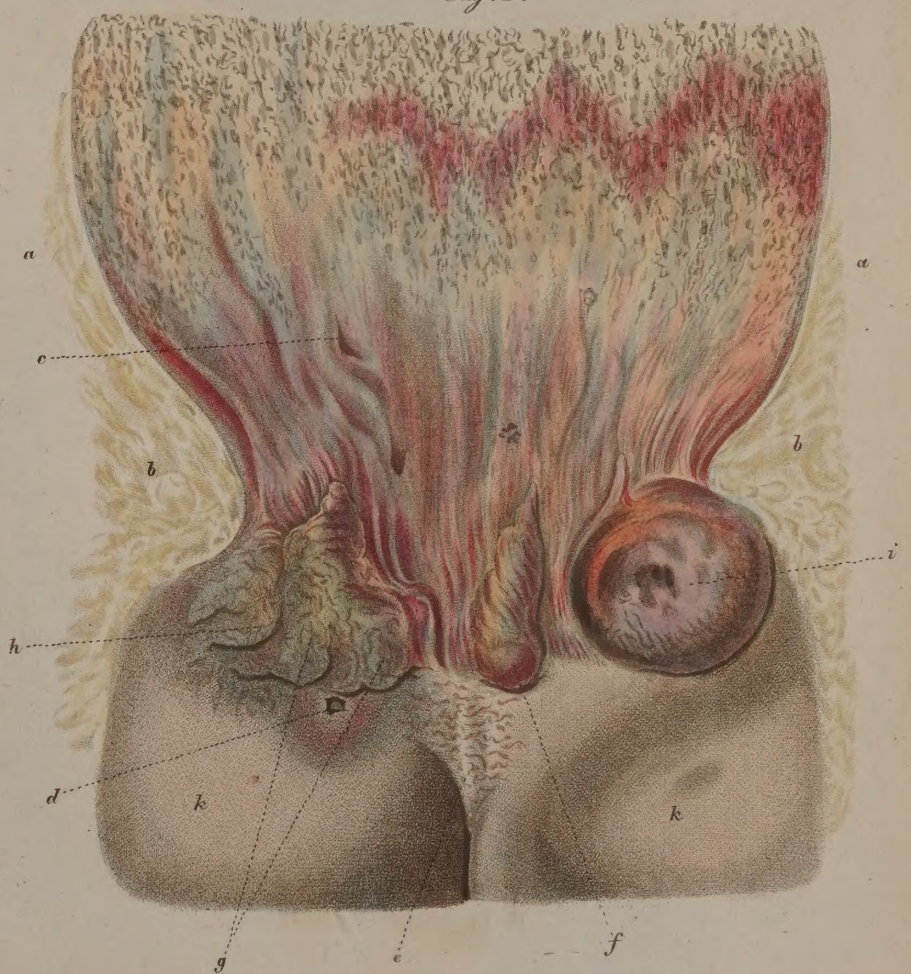

Dr. Robert Froriep ad nat. pinx.



Spinae Distorsio.
H.

Taf. CCCXV.

Fig. 1.

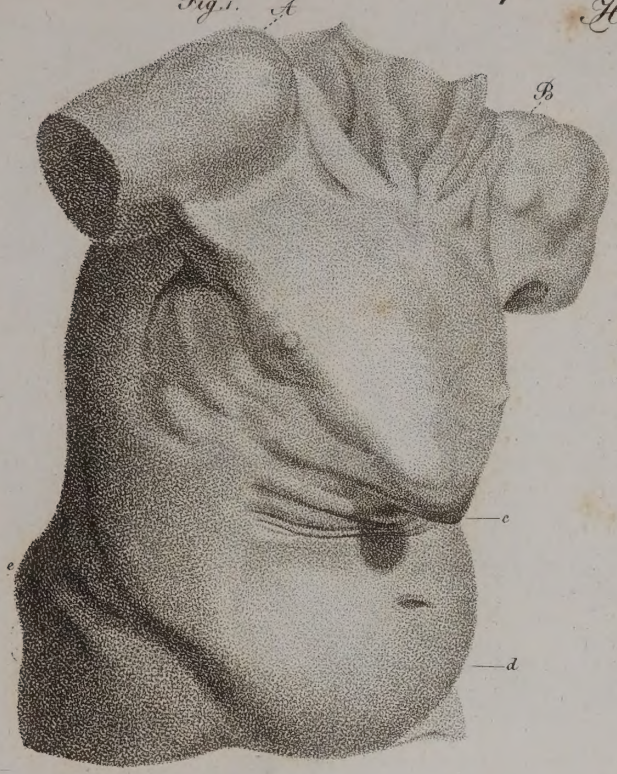

Fig. 2.

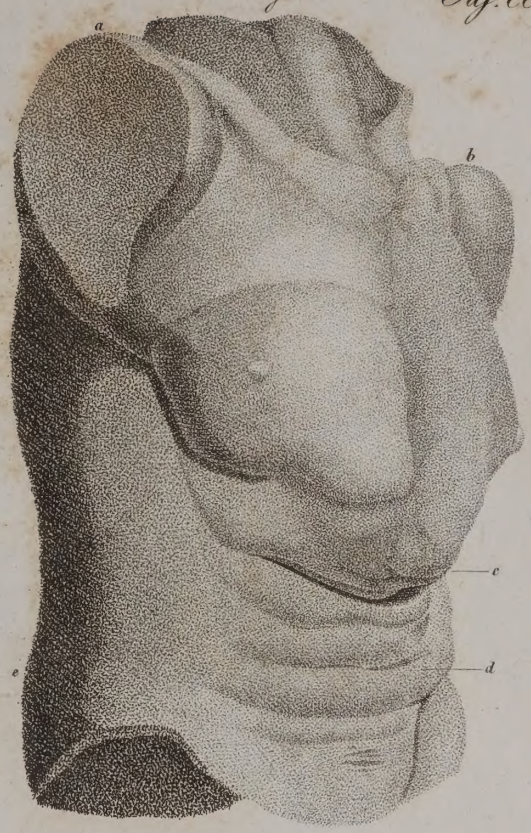

Fig. 3.

Fig. 4.

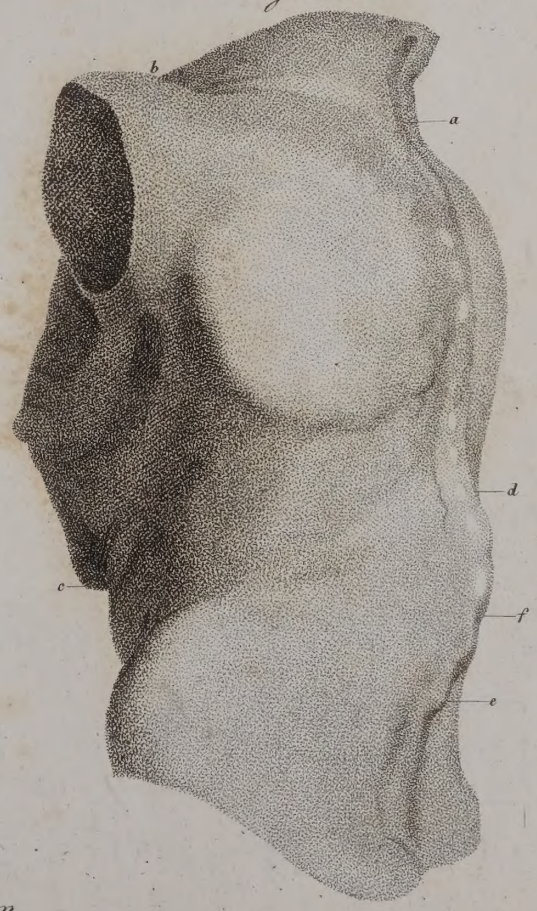

nach Harrison.

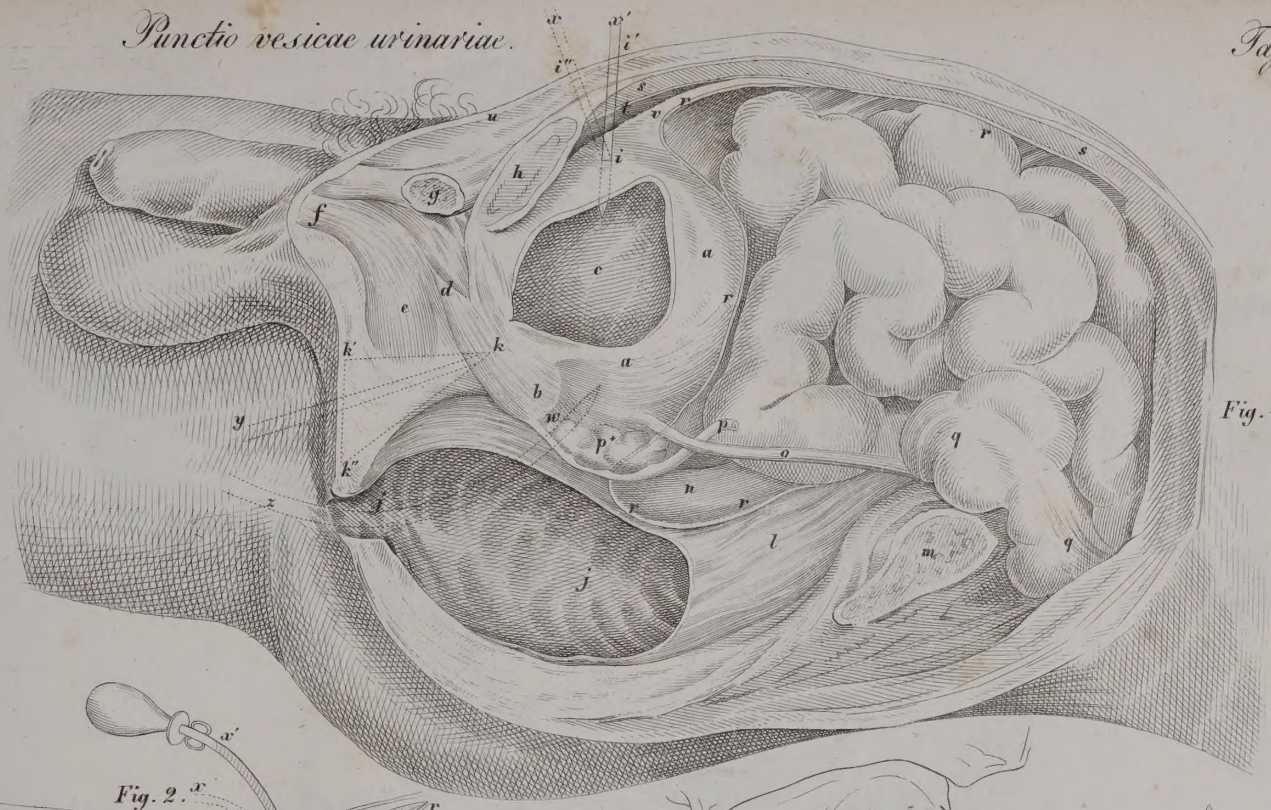

Fig. 1.

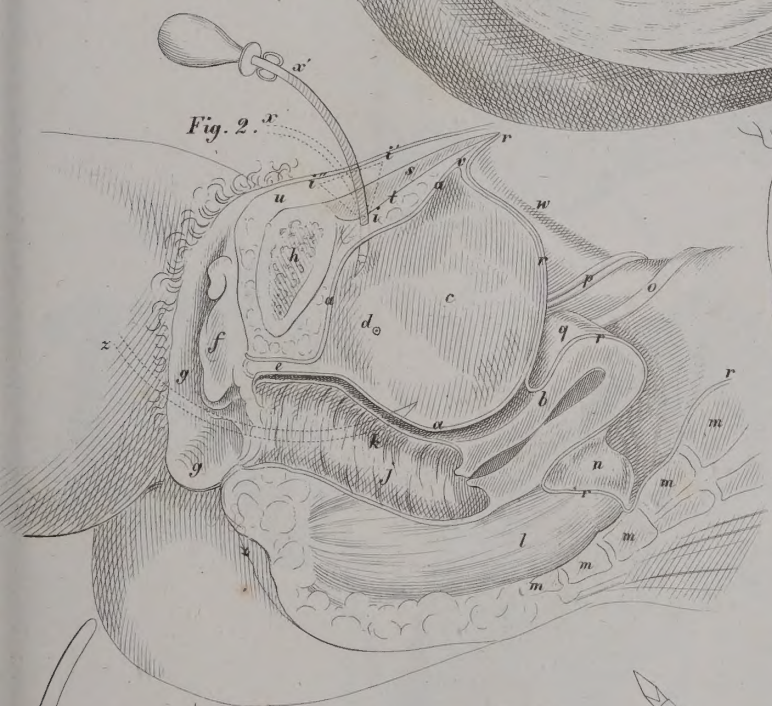

Fig. 2.

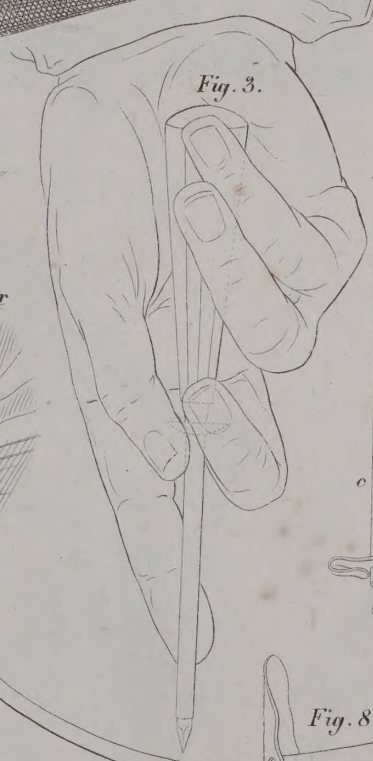

Fig. 3.

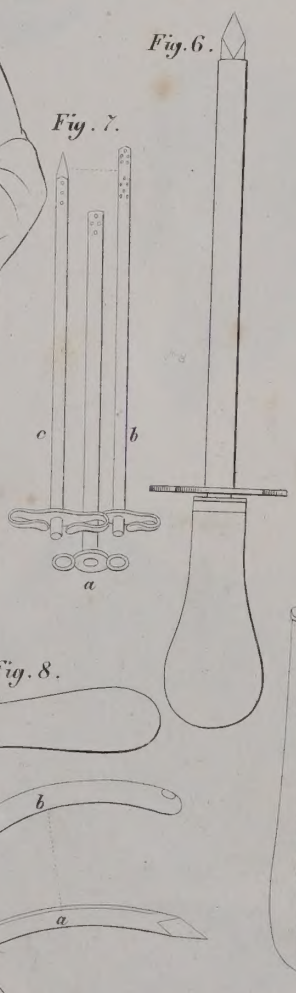

Fig. 5.

Fig. 6.

Fig. 7.

Fig. 8.

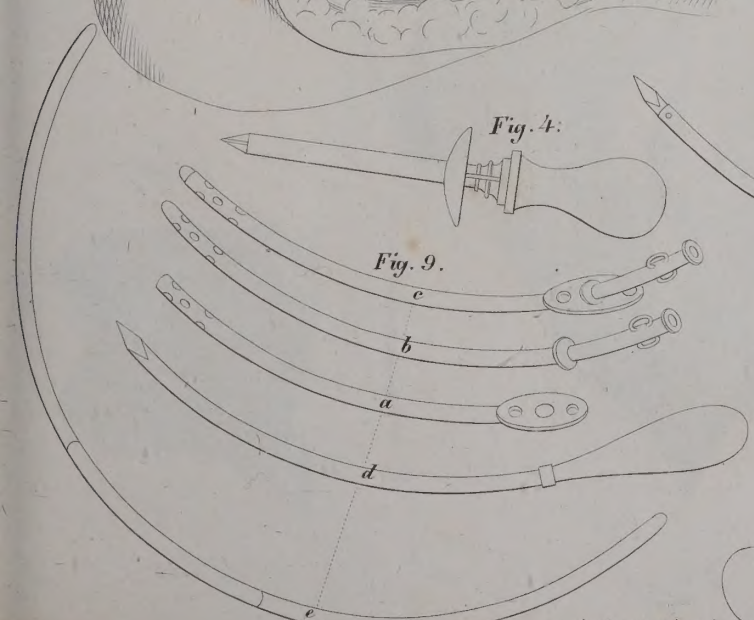

Fig. 4.

Fig. 9.

Fig. 10.

Hygroma patellae.

Fig. 1.

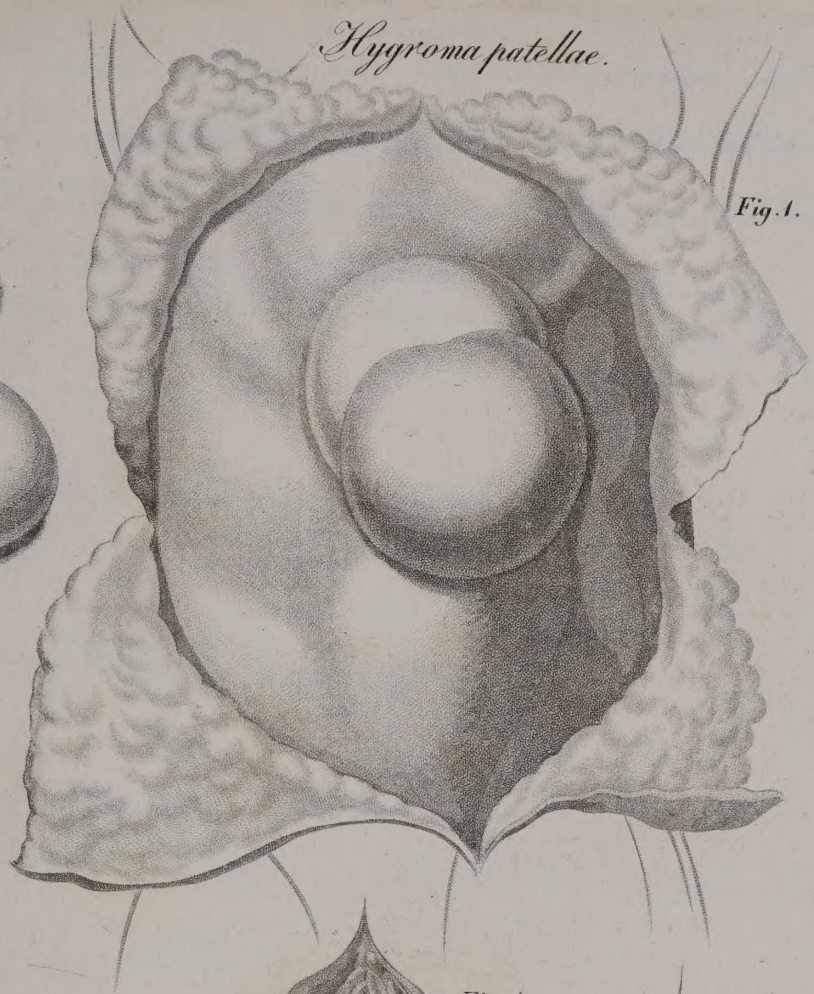

Fig. 2.

Fig. 3.

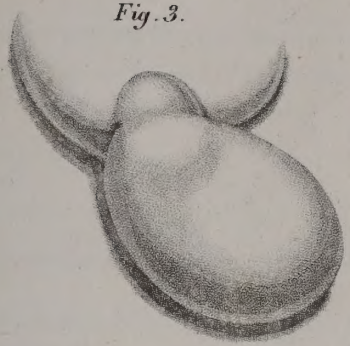

Fig. 4.

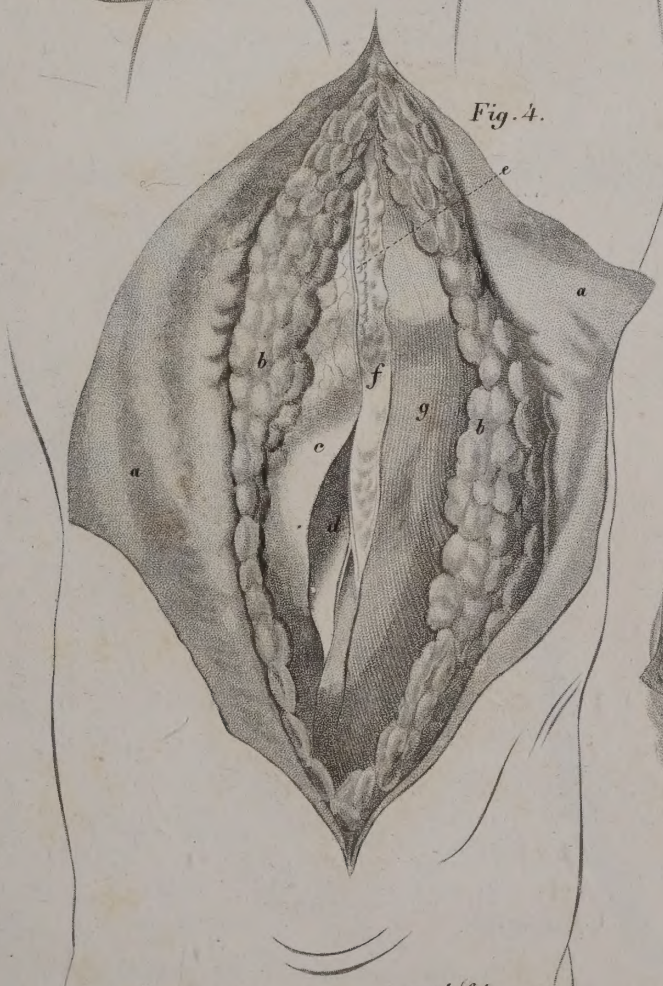

Fig. 5.

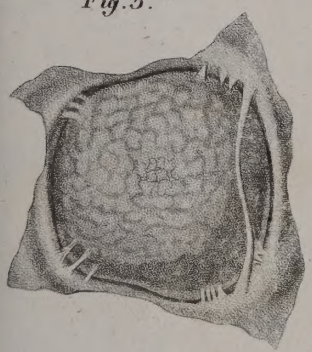

Fig. 6.

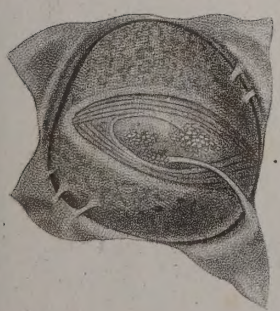

Fig. 7.

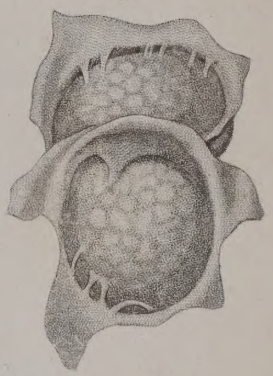

Fig. 8.

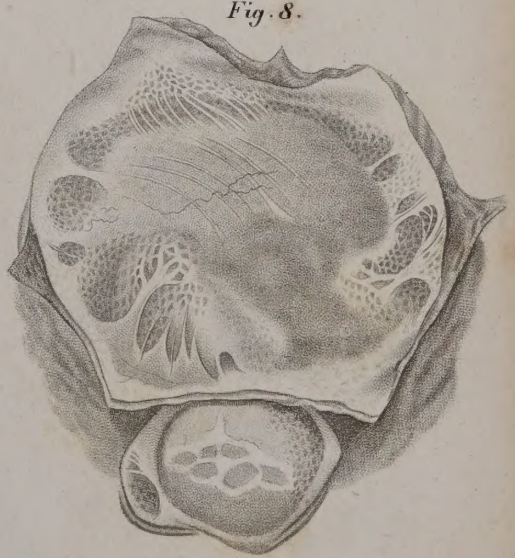

nach Schreger.

Catheterismus.

Fig. 1.

Fig. 2.

Fig. 3.

Fig. 4.

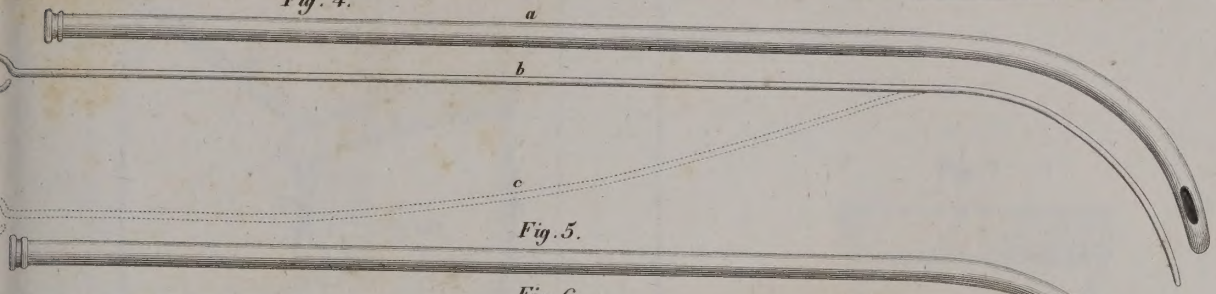

Fig. 5.

Fig. 6.

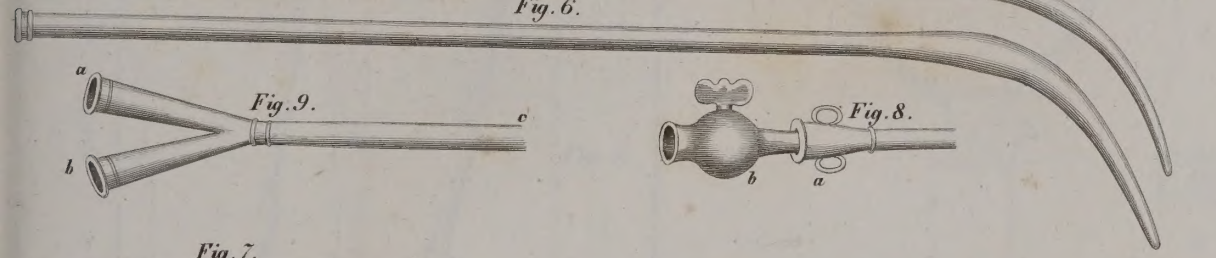

Fig. 9.

Fig. 8.

Fig. 7.

Fig. 12.

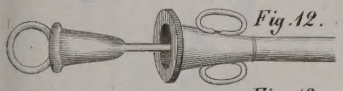

Fig. 10.

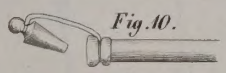



Fig. 13.

Fig. 11.

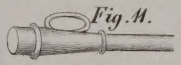

Fig. 14.

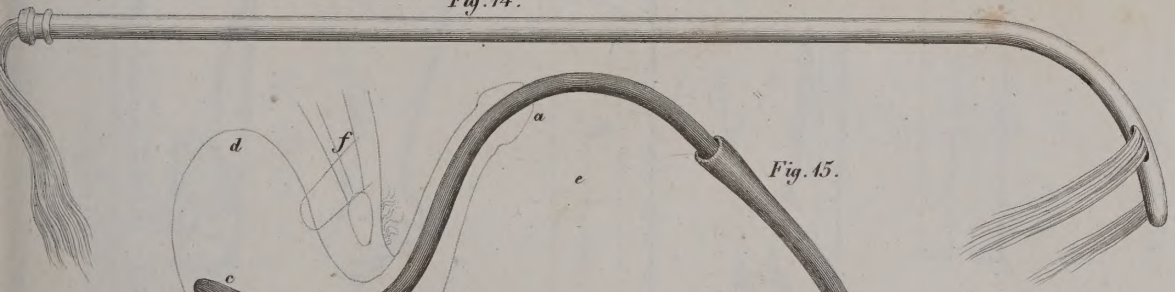

Fig. 15.



Fig. 16.

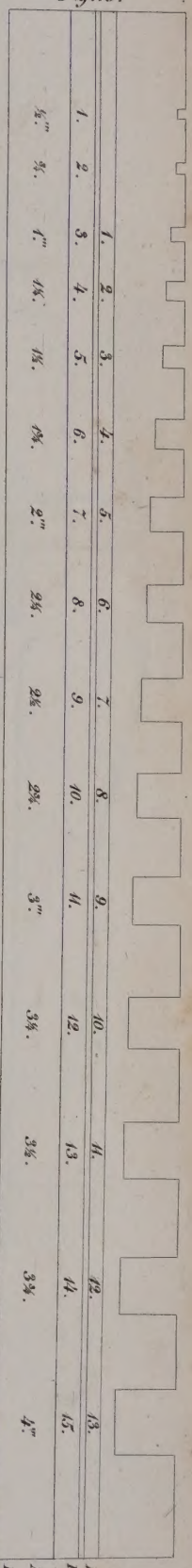

nach Segalas, Segin, Soubeirbielle und Originalzeichnungen.

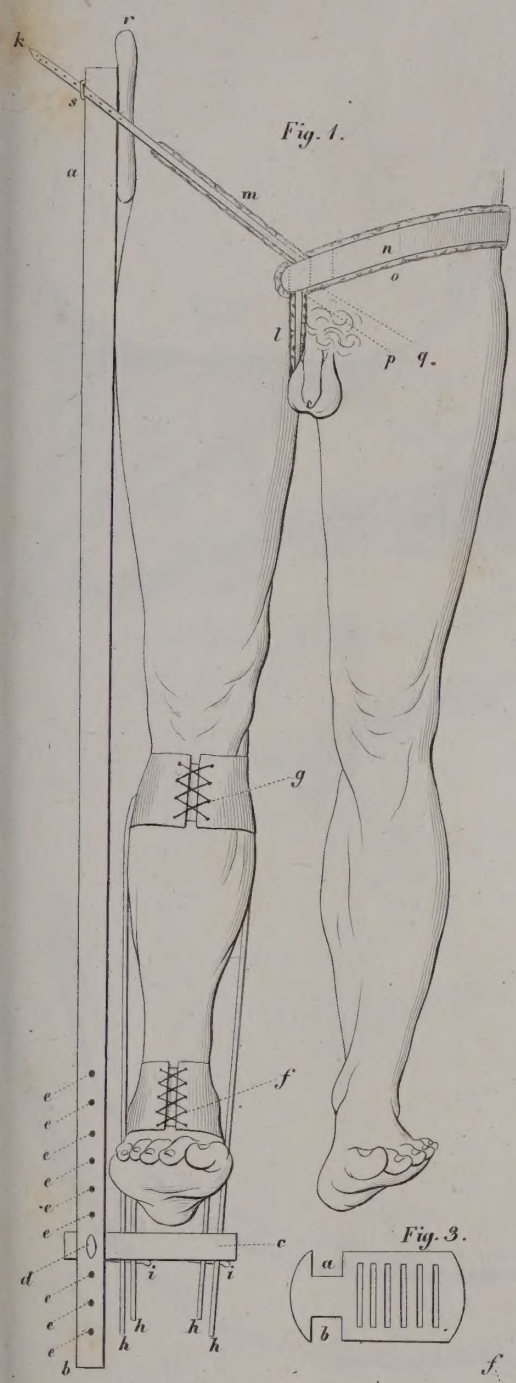

Fig. 1.



Fig. 2.

Fig. 3.



Fig. 4.

Fig. 5.

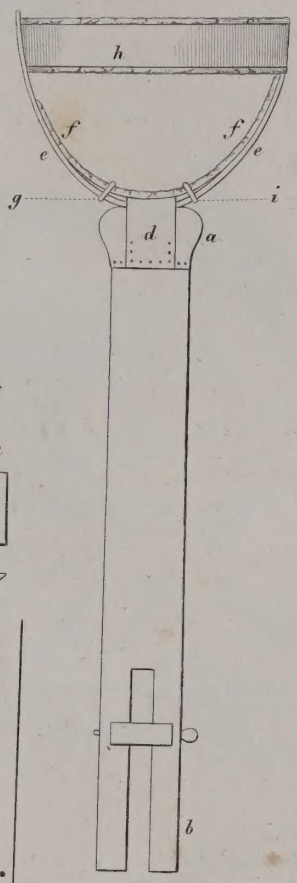

Fig. 7.

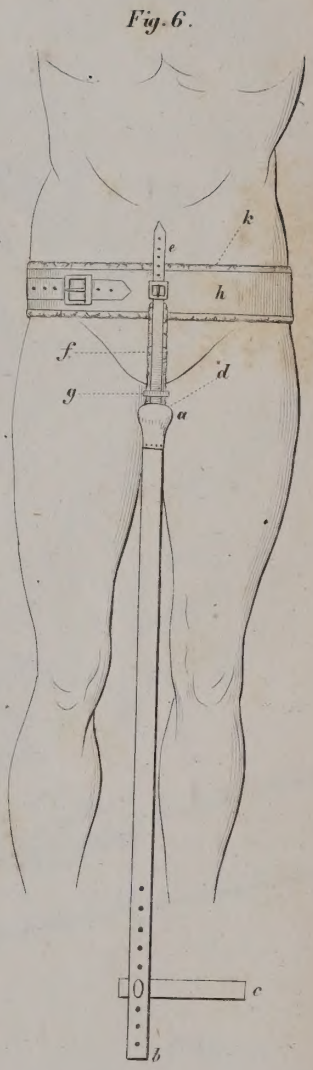

Fig. 6.

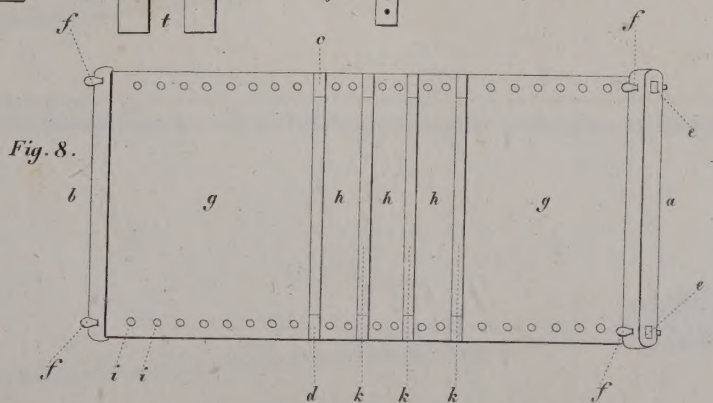

Fig. 8.

r Weckert delin.

Oesophagotomie.

B.

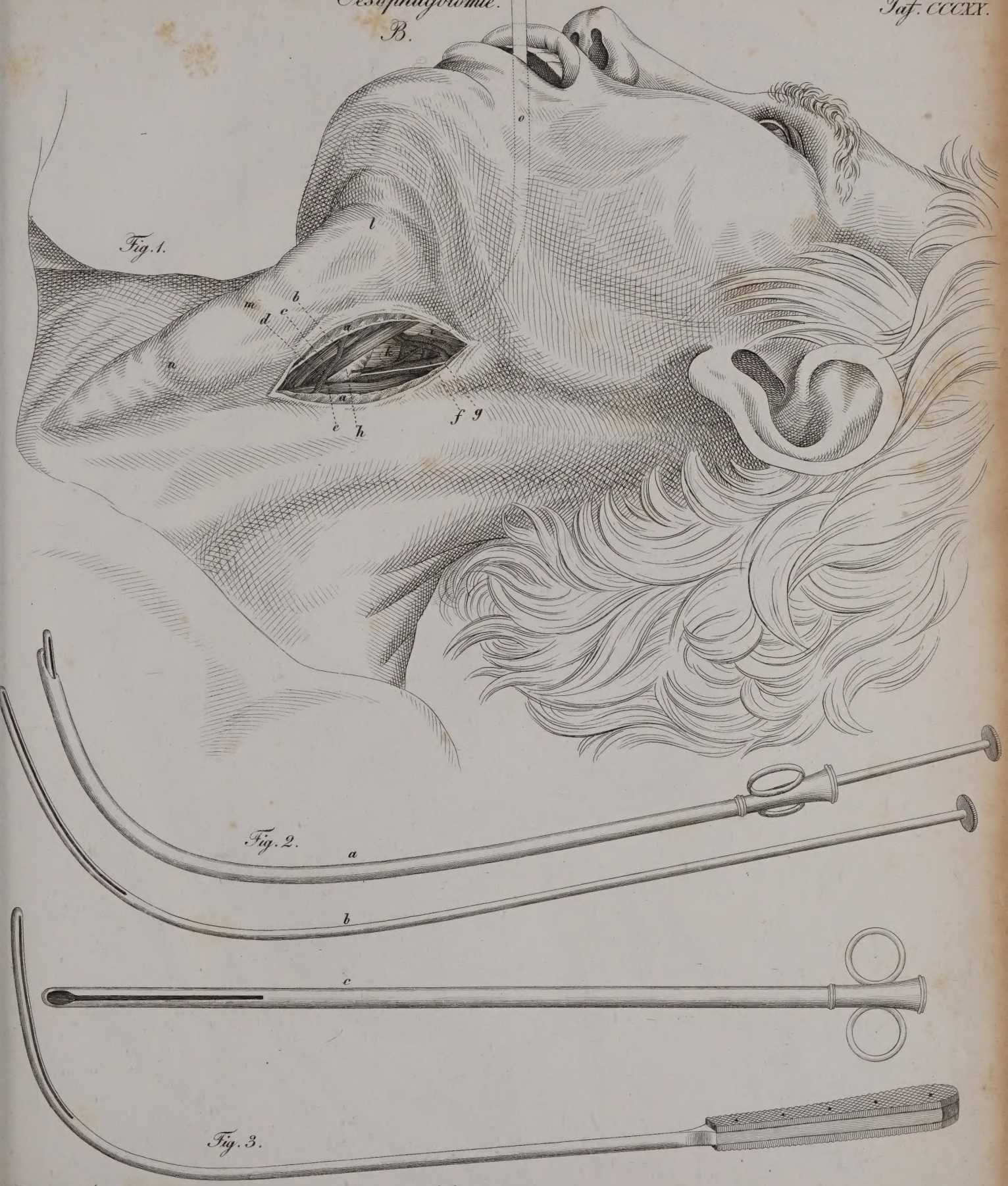

Dr. Robert Froriep del. nach Originalzeichnungen.

Fig. 1.

Fig. 2.

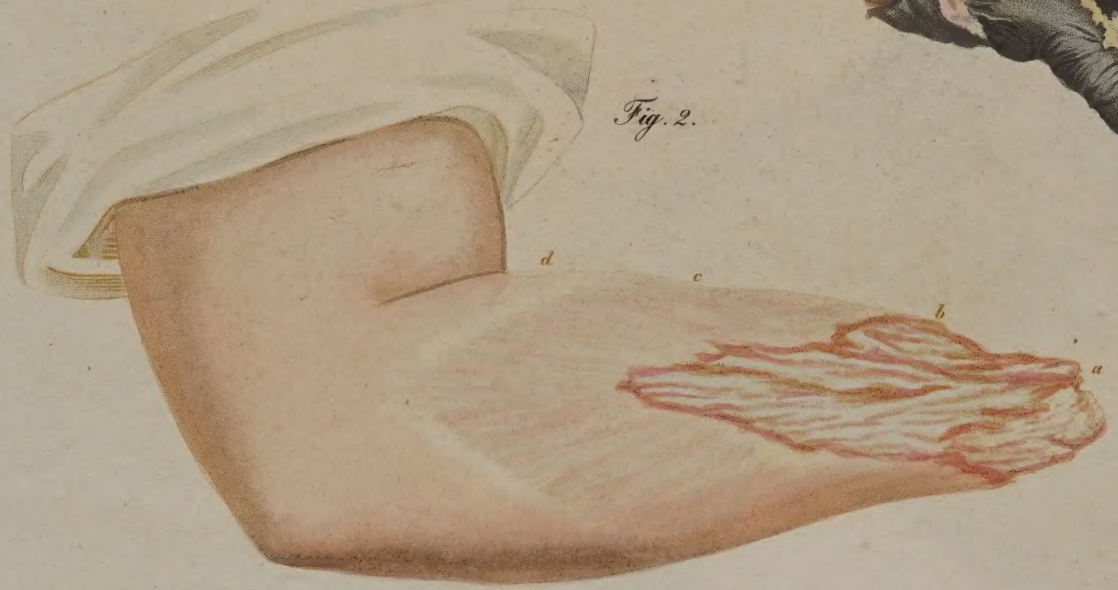

Dr. Robert Froriep ad nat. pinx.



Strictura urethrae.

Taf. CCCXXV.

Fig. 1.

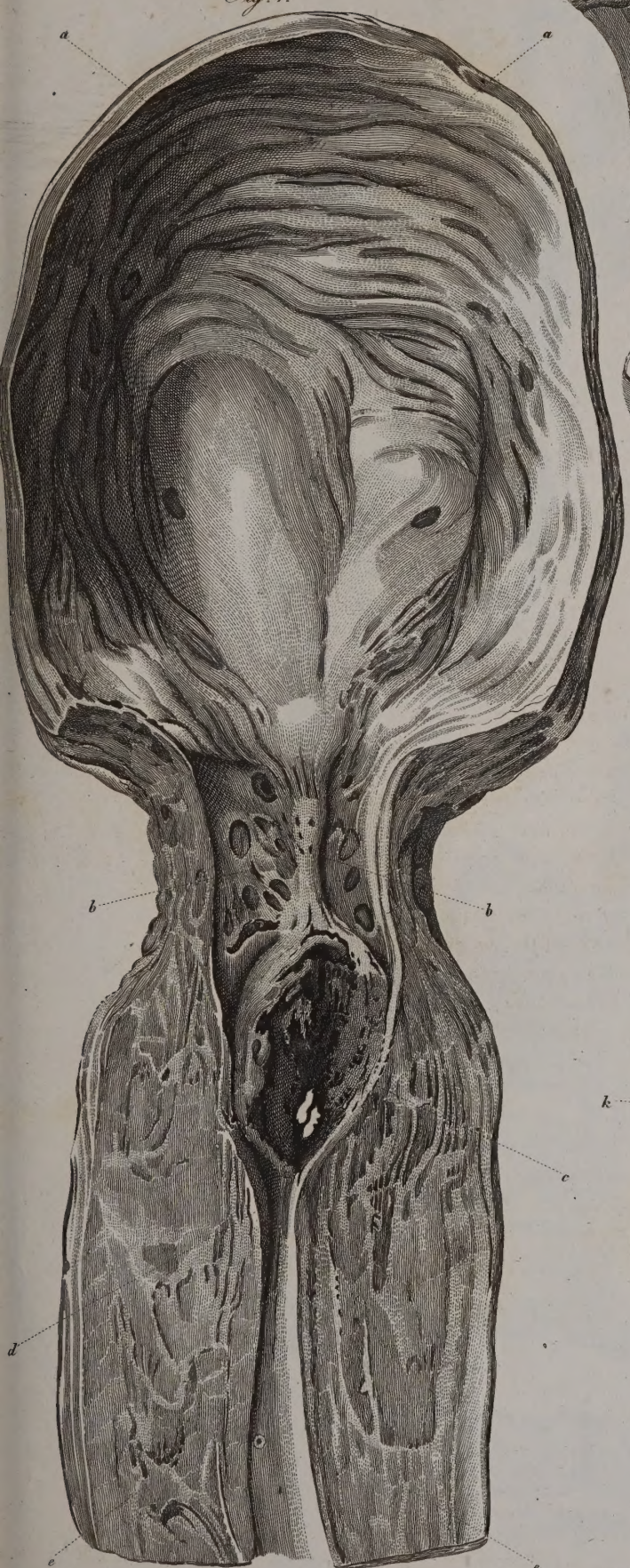

Fig. 2.

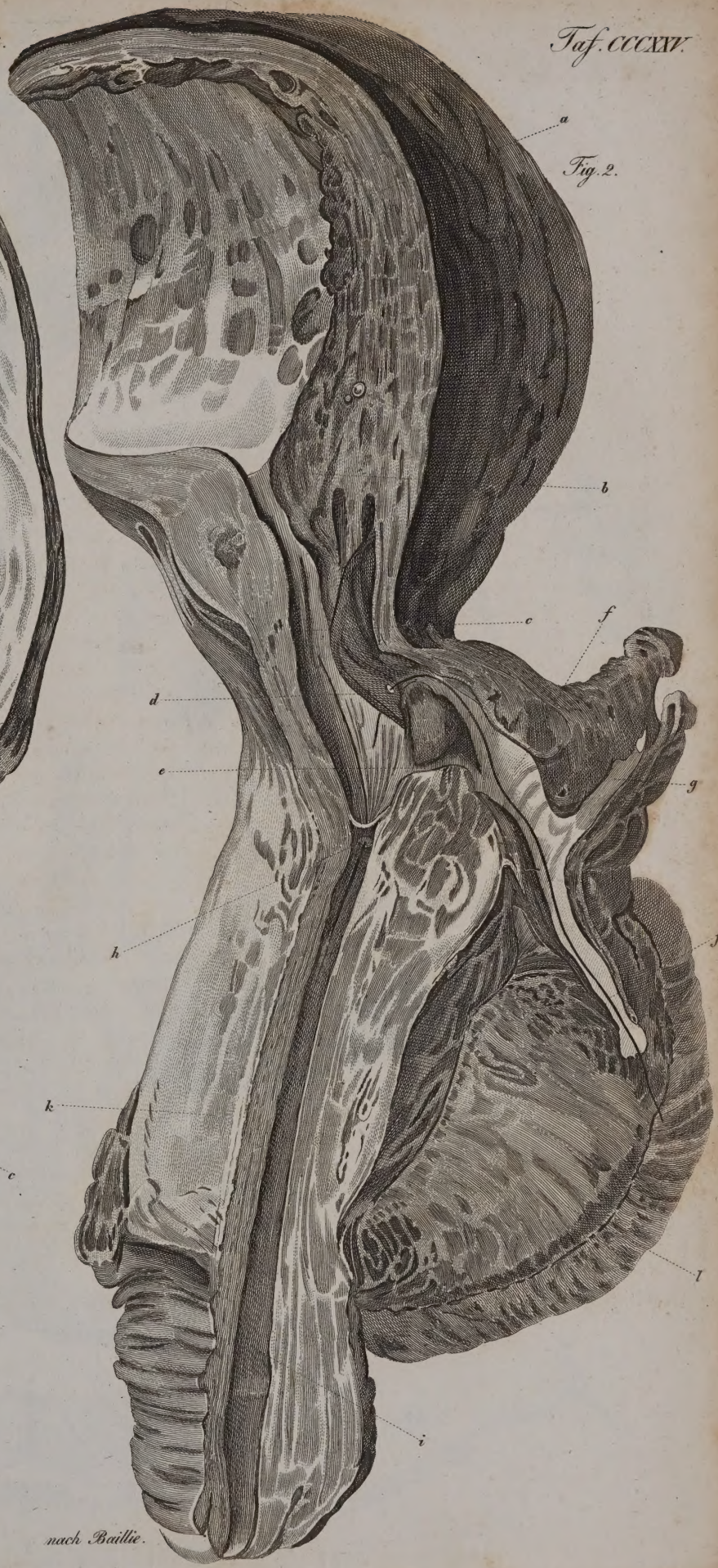

nach Baillie.

Excisio articulorum.

B.

Fig. 1.

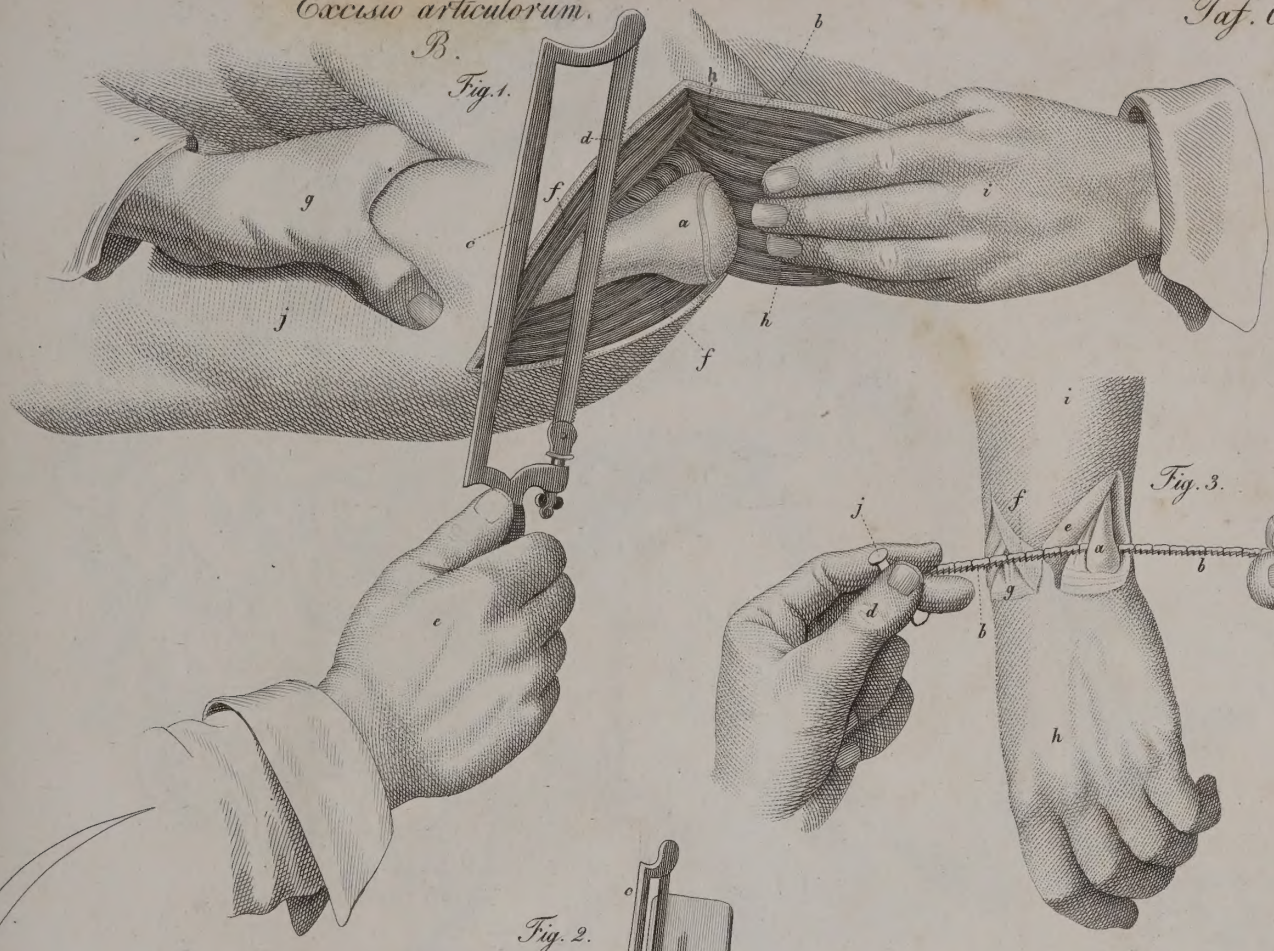

Fig. 3.

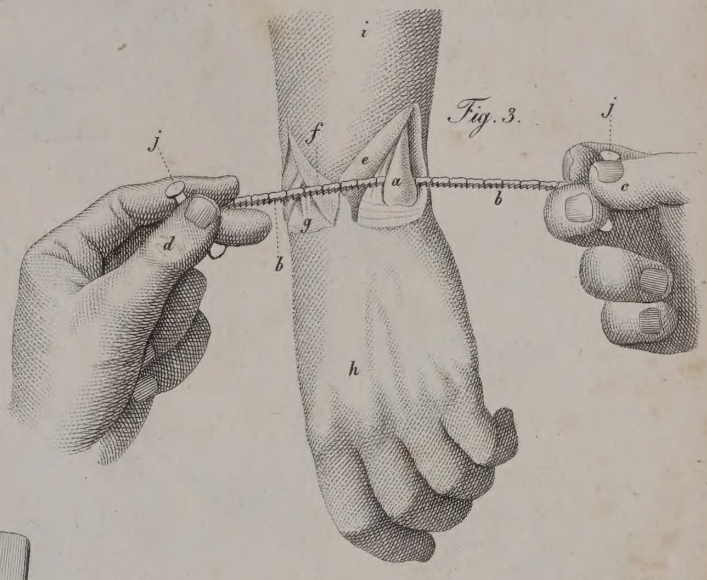

Fig. 2.

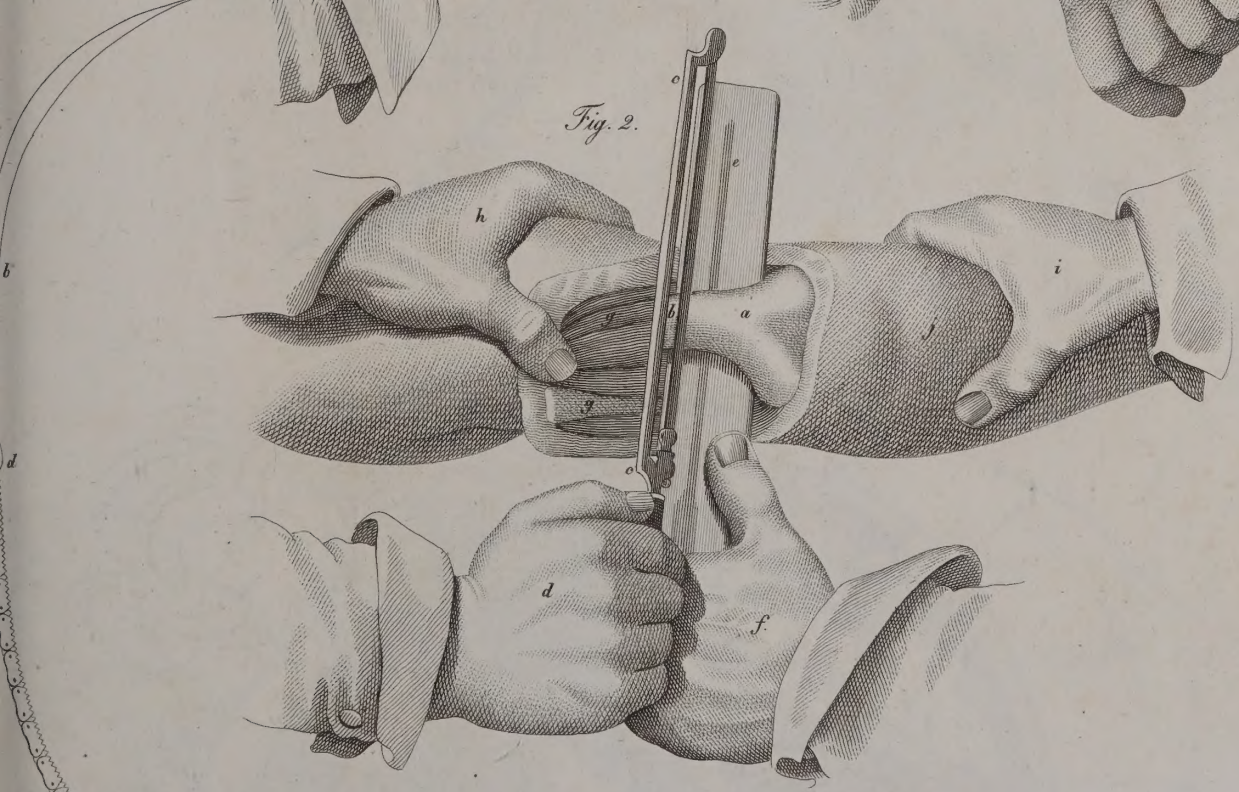

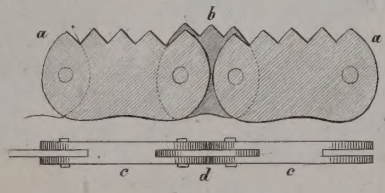

Fig. 5.

Fig. 4.

Fig. 1.

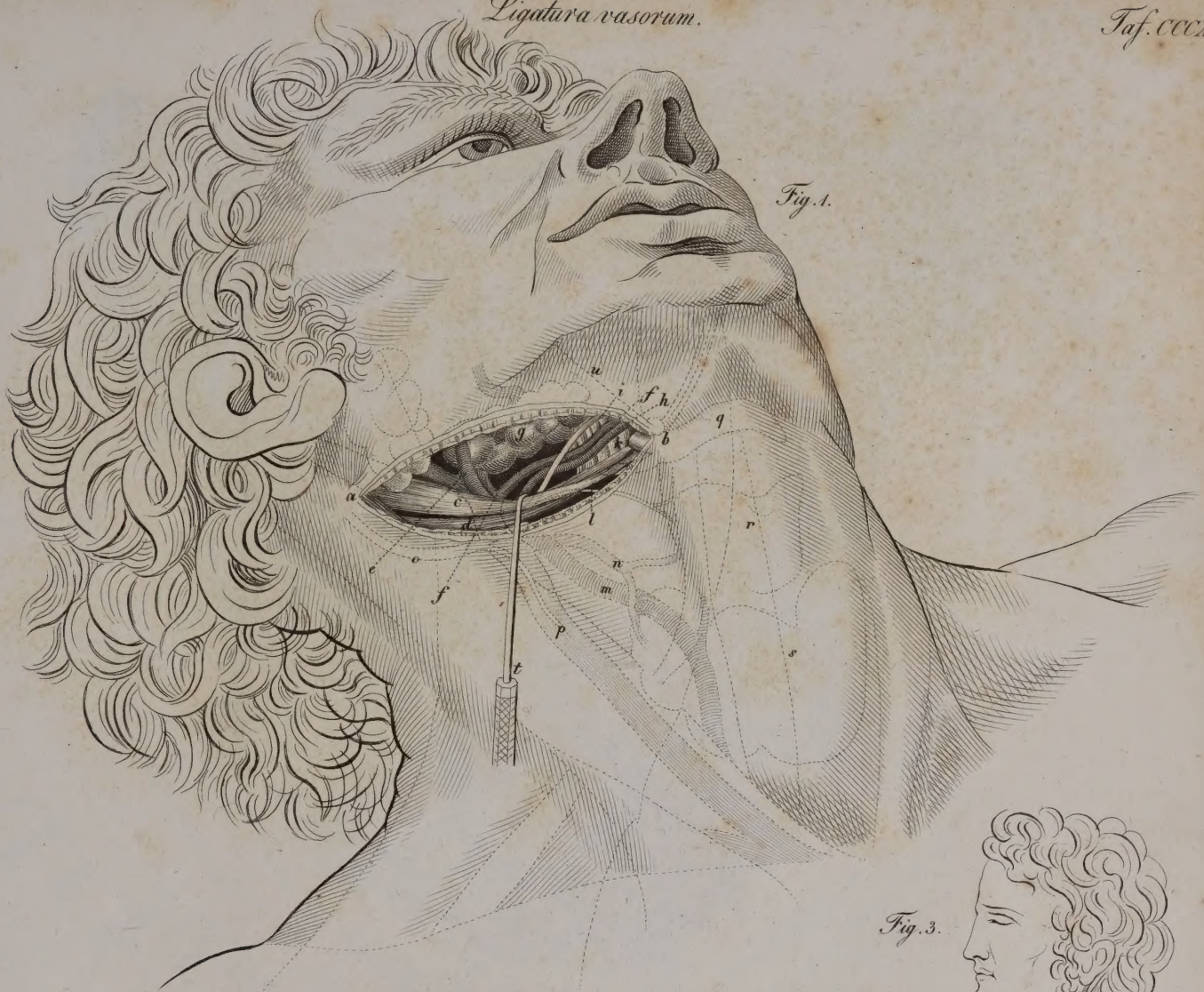

Fig. 3.

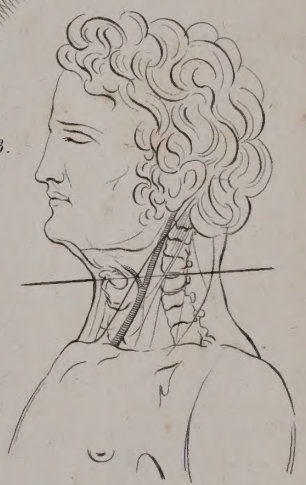

Fig. 2.

Dr. Robert Froriep del.

Fig. 1.

Fig. 2.

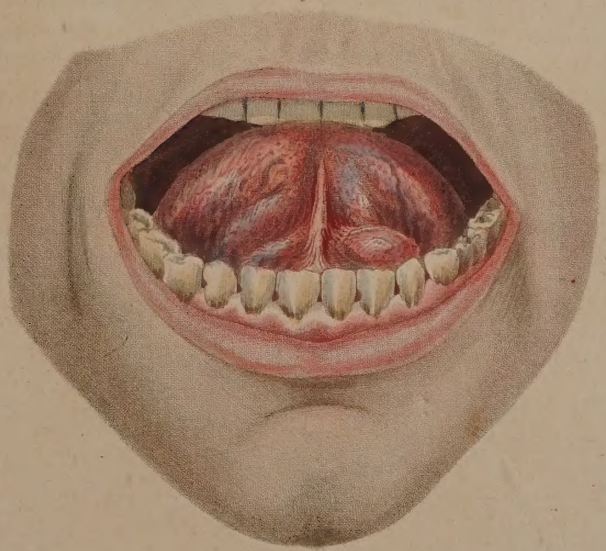

Fig. 3.

Fig. 4.

Robert Froriep ad nat. pinx.

Structura Ani.





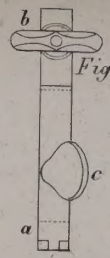

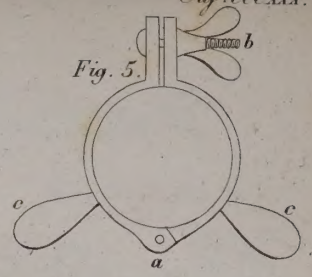

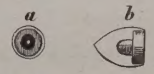



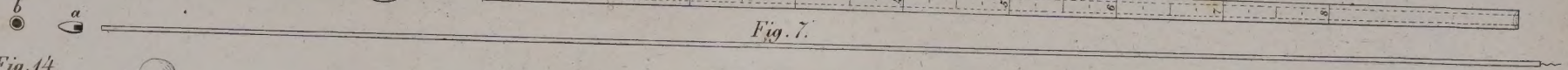

Fig. 14.



Fig. 15.

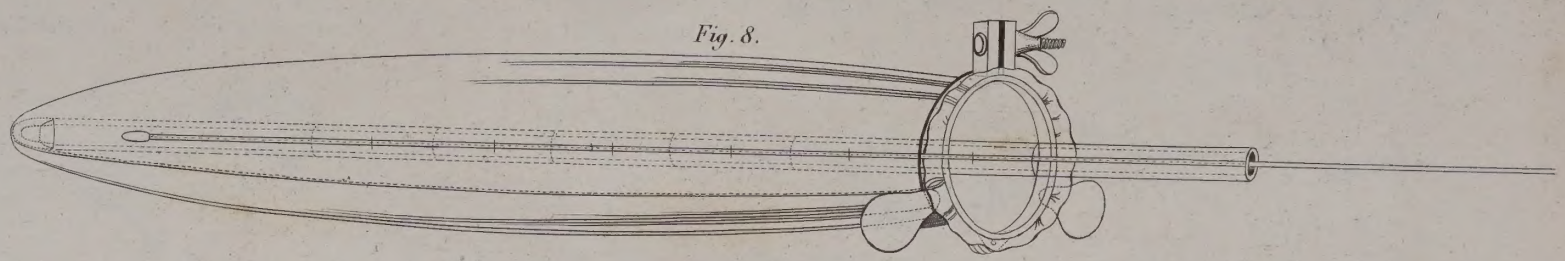





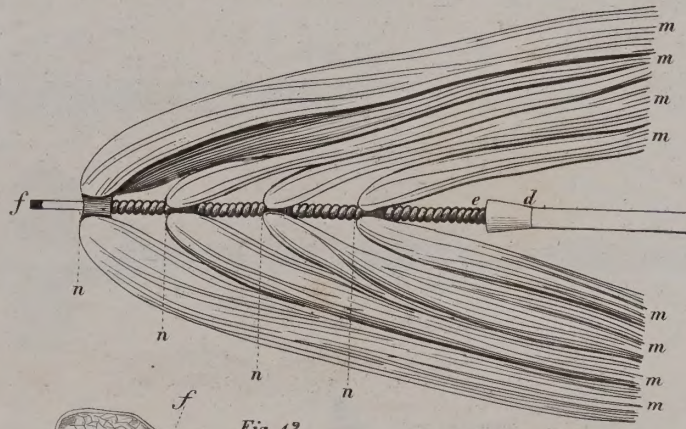



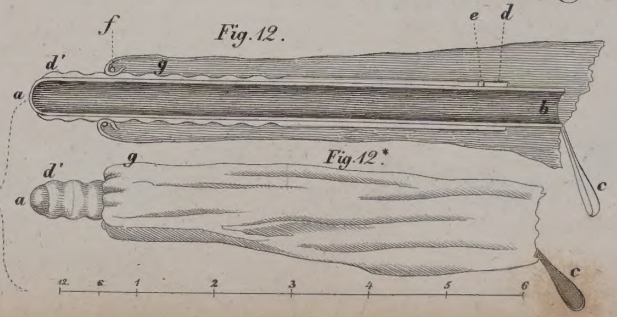

nach Costallat und Originalzeichnungen.

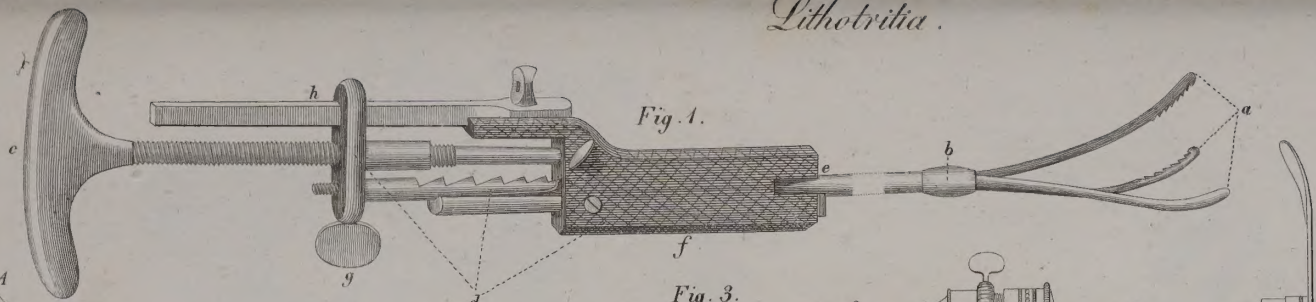

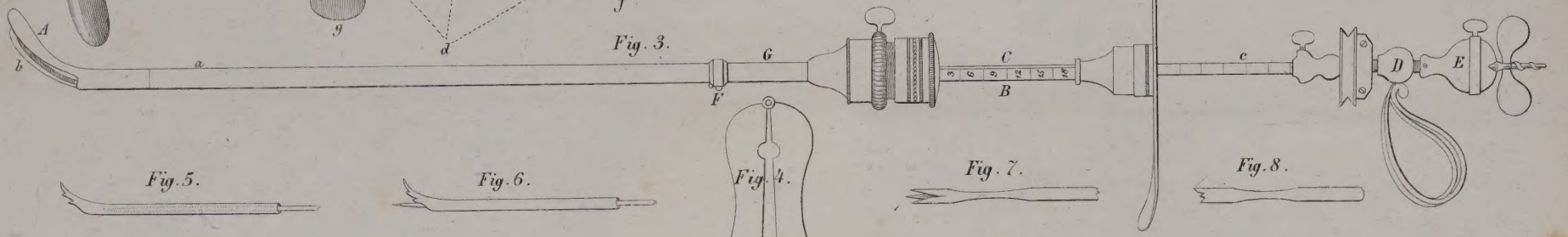

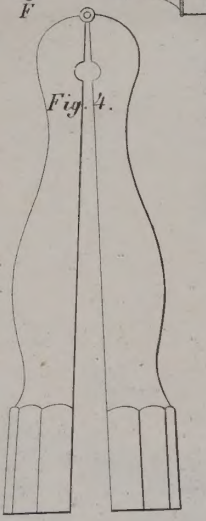

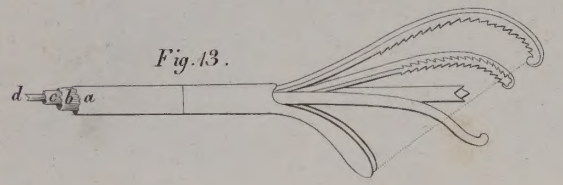

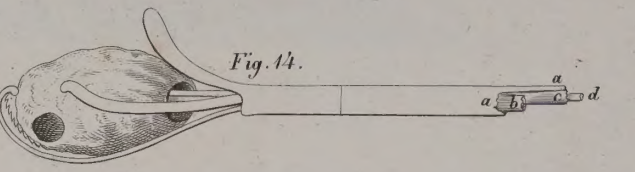



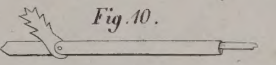











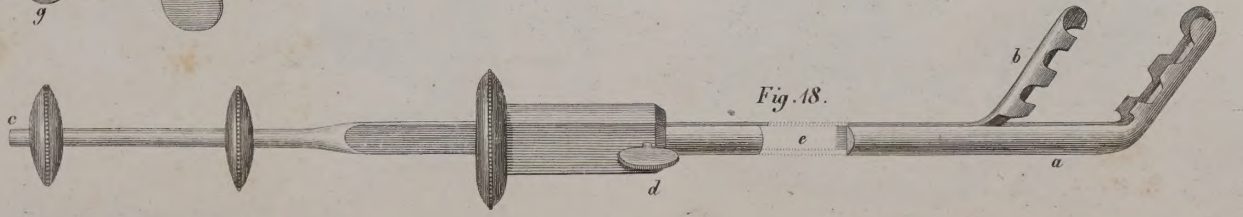

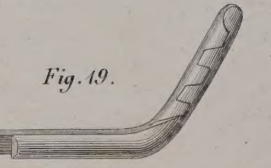

nach Benvenuti u. Velpeau.

Resectio nervorum.

Fig. 1.

Fig. 2.

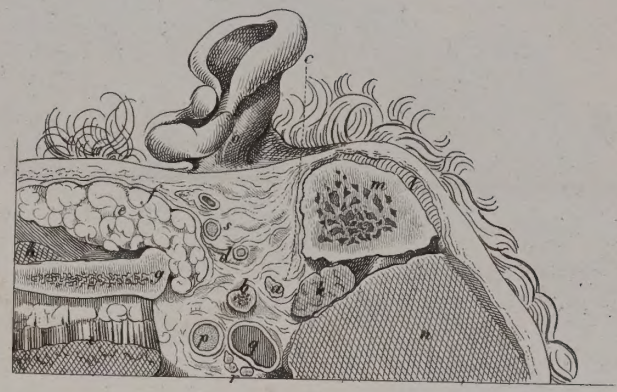

Fig. 3.

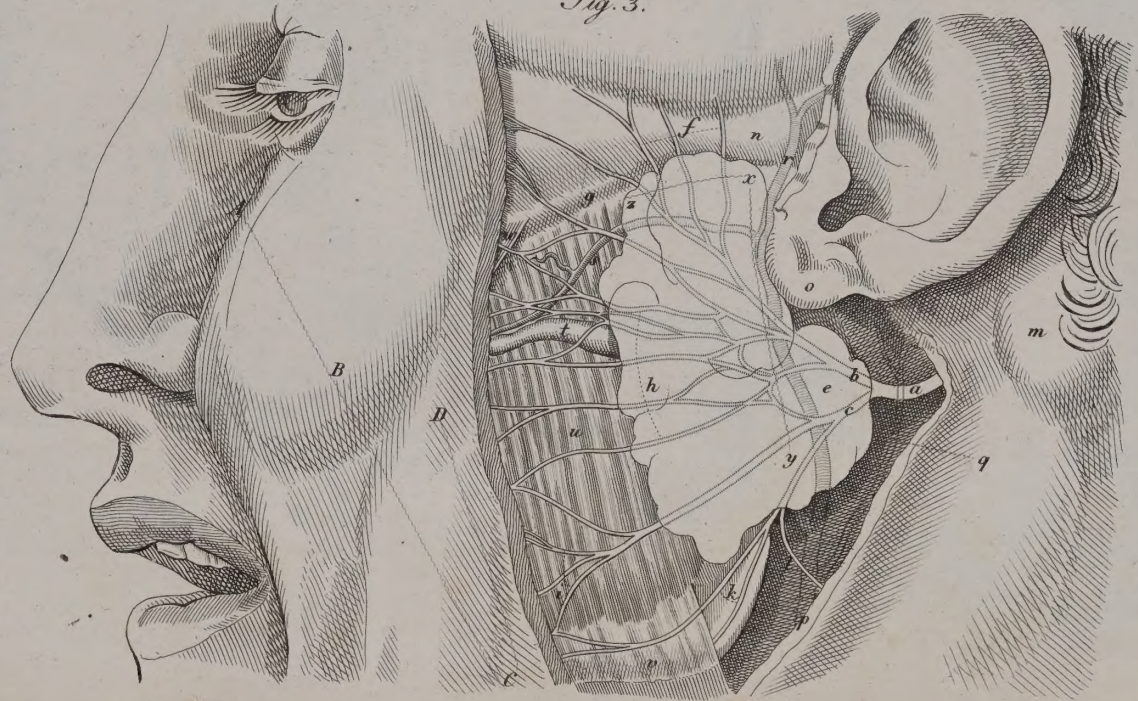

Dr. Robert Froriep ad nat. del.

Atresia oris. *Taf. CCCXXXIII. CCCXXXIV.*

F. Robert Froriep ad. nat. pinx.

Staphyloraphia.

Fig. 1.

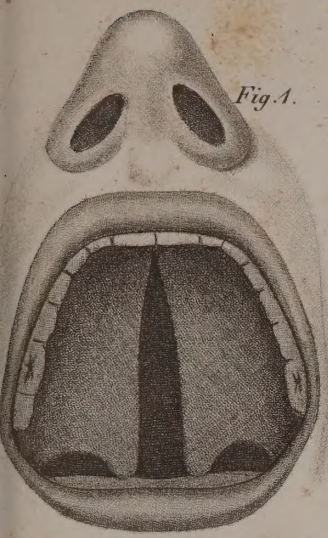

Fig. 2.

Fig. 3.

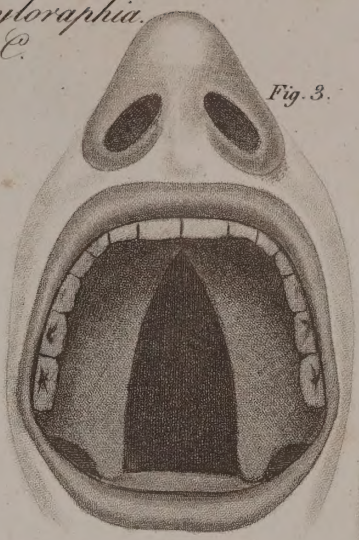

Fig. 4.

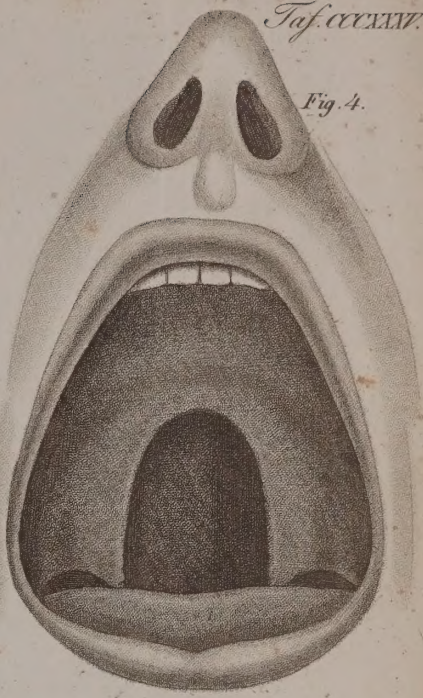

Fig. 5.

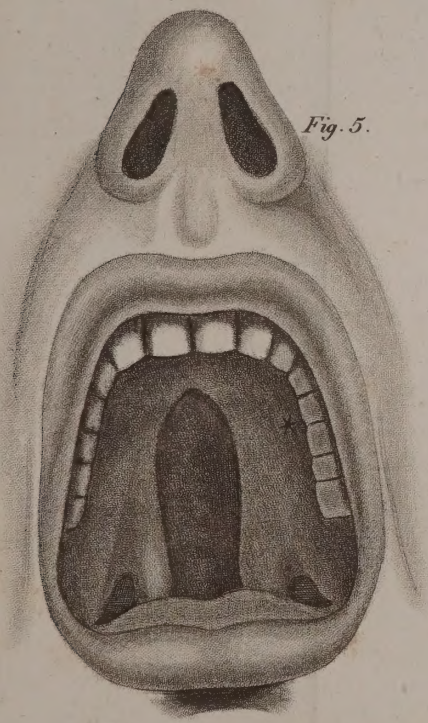

Fig. 6.

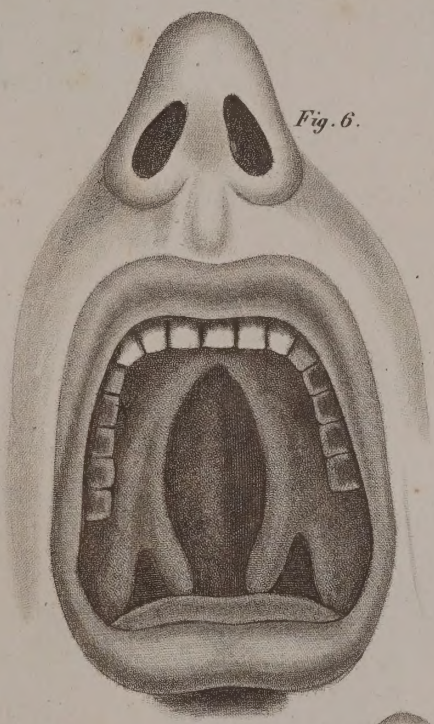

Fig. 7.

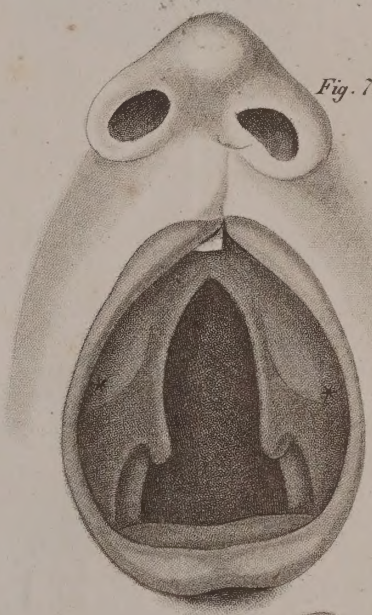

Fig. 8.

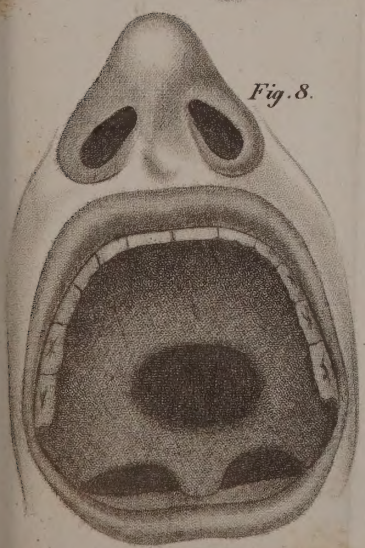

Fig. 9.

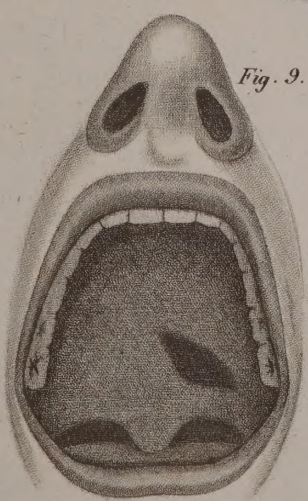

Fig. 10.

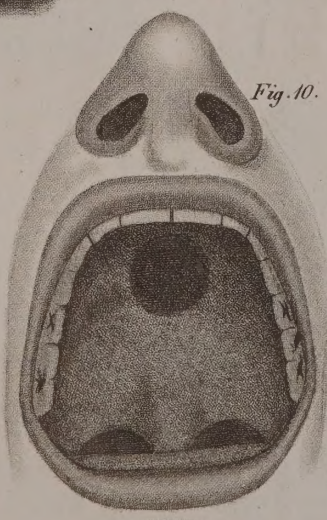

Fig. 11.

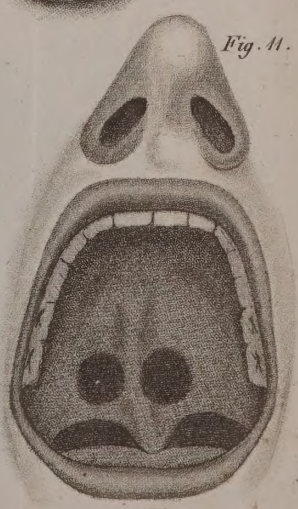

nach Originalzeichnungen.

Staphyloraphia.

D.

Fig. 1.

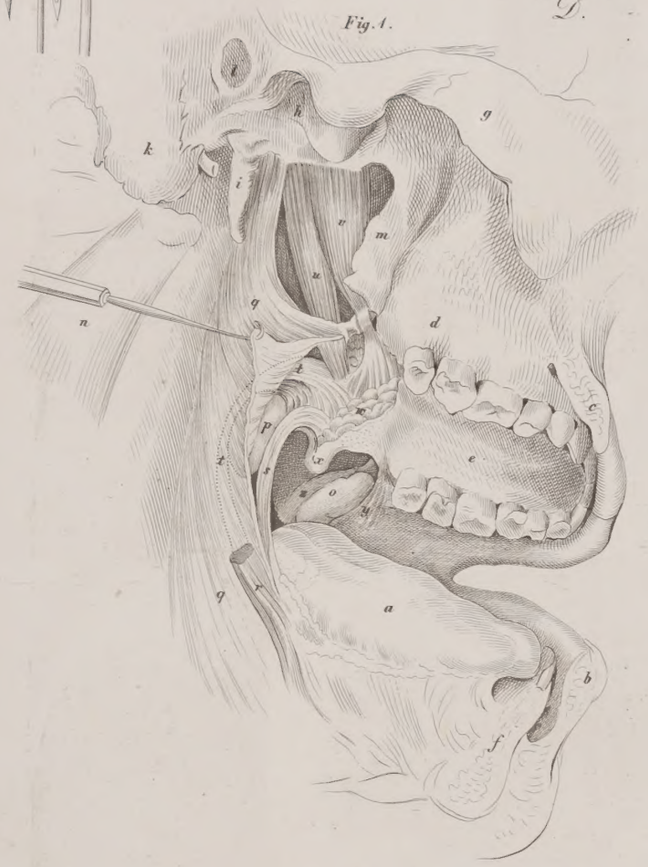

Fig. 2.

Fig. 3.



Fig. 4.

Fig. 5.

Fig. 6.

Fig. 7.

Fig. 8. Fig. 9.



Fig. 10.

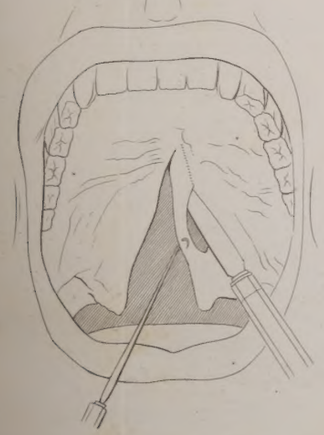

Fig. 11.

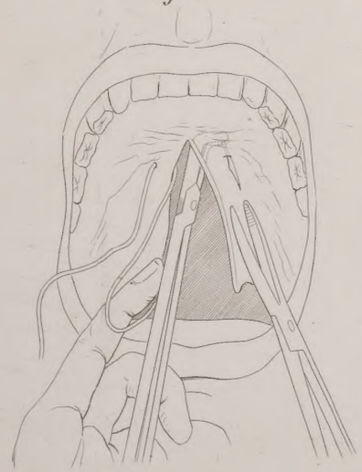

Fig. 12.

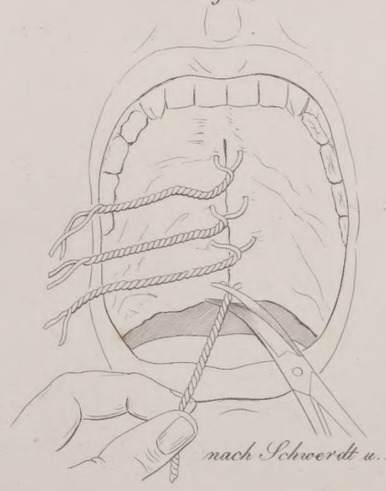

Fig. 14.

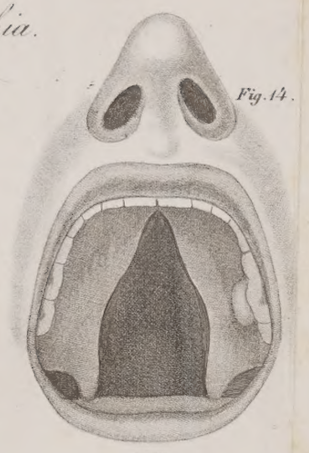

Fig. 17.

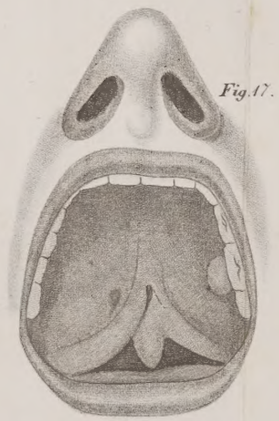

Fig. 15.

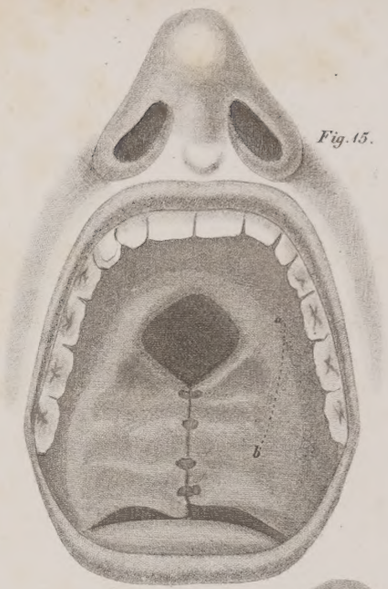

Taf. CCCXXXVI. CCCXXXVII.

Fig. 16.

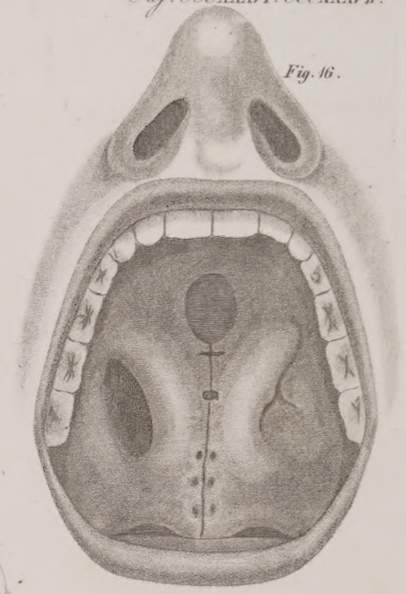

Fig. 18.

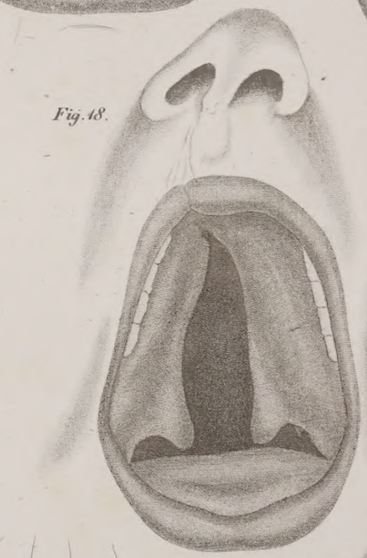

Fig. 19.

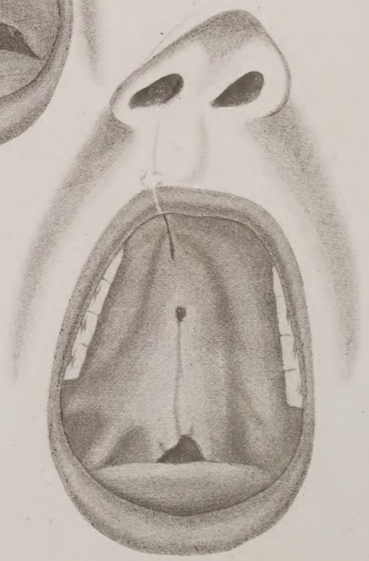

Fig. 13.

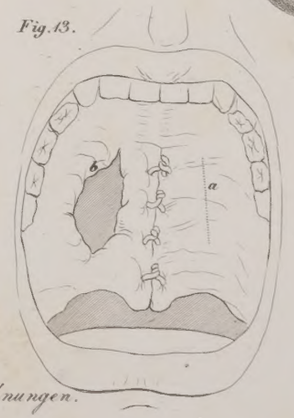

nach Schwerdt u. nach Originalzeichnungen.

Rhinoplastice.
C.

Fig. 1.

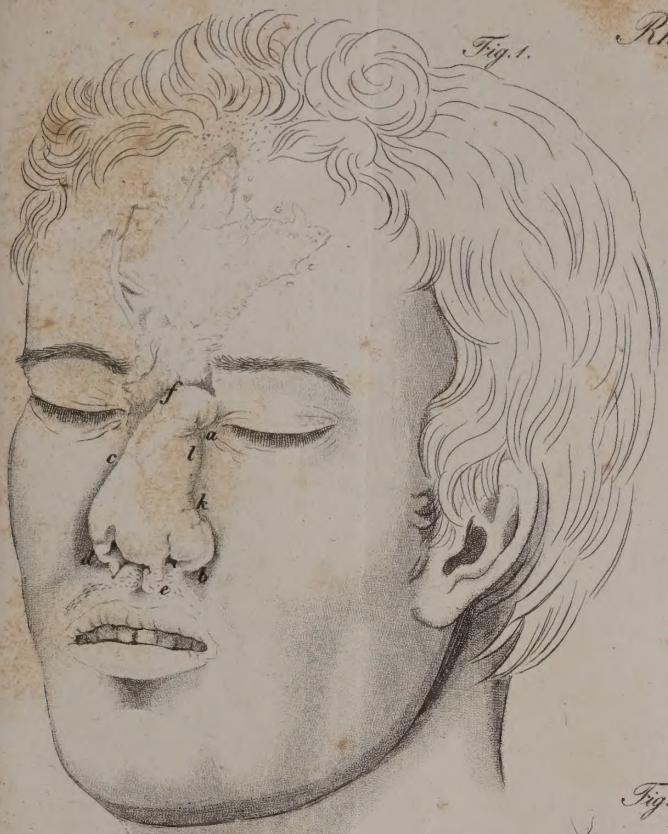

Fig. 2.

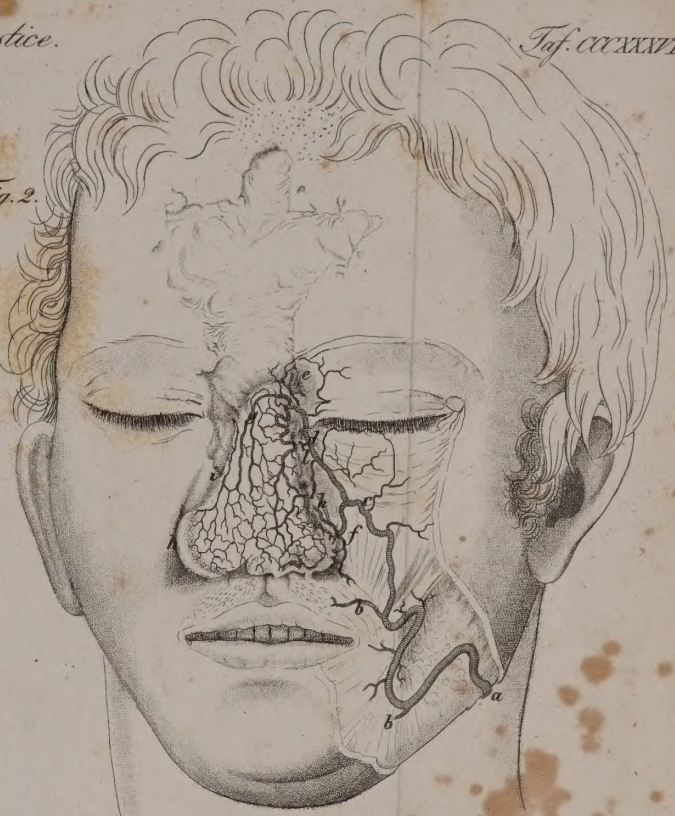

Fig. 3.

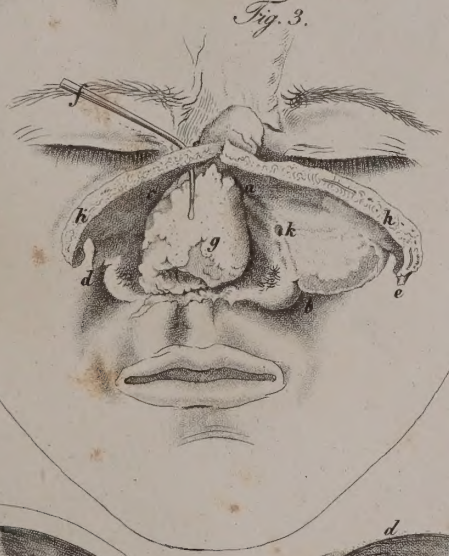

Fig. 6.

Fig. 4.

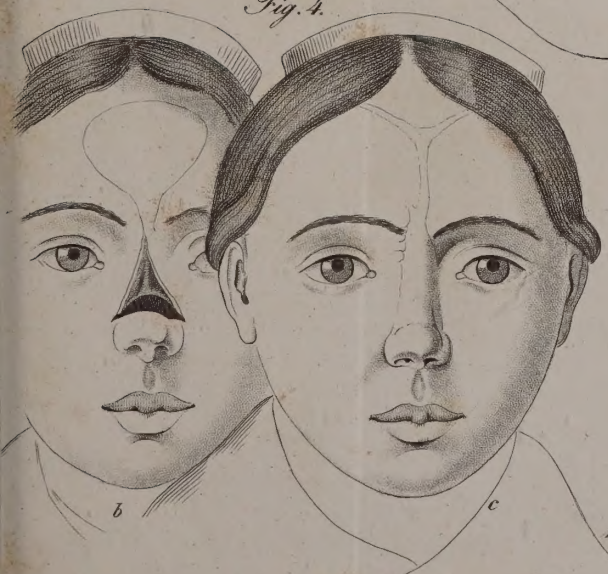



Fig. 5.

nach Originalzeichnungen.

Exostocis.
A.

Fig. 1.

Fig. 2.

Fig. 5.

Fig. 4.

Fig. 6.

Fig. 3

Dr. Robert Froriep ad nat. pinx.

Fig. 1.

Inversio vesicae urinariae.

Taf. CCCXL.

A.

Fig. 3.

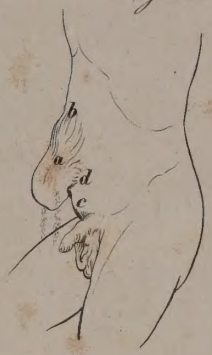

Fig. 2.

Fig. 4.

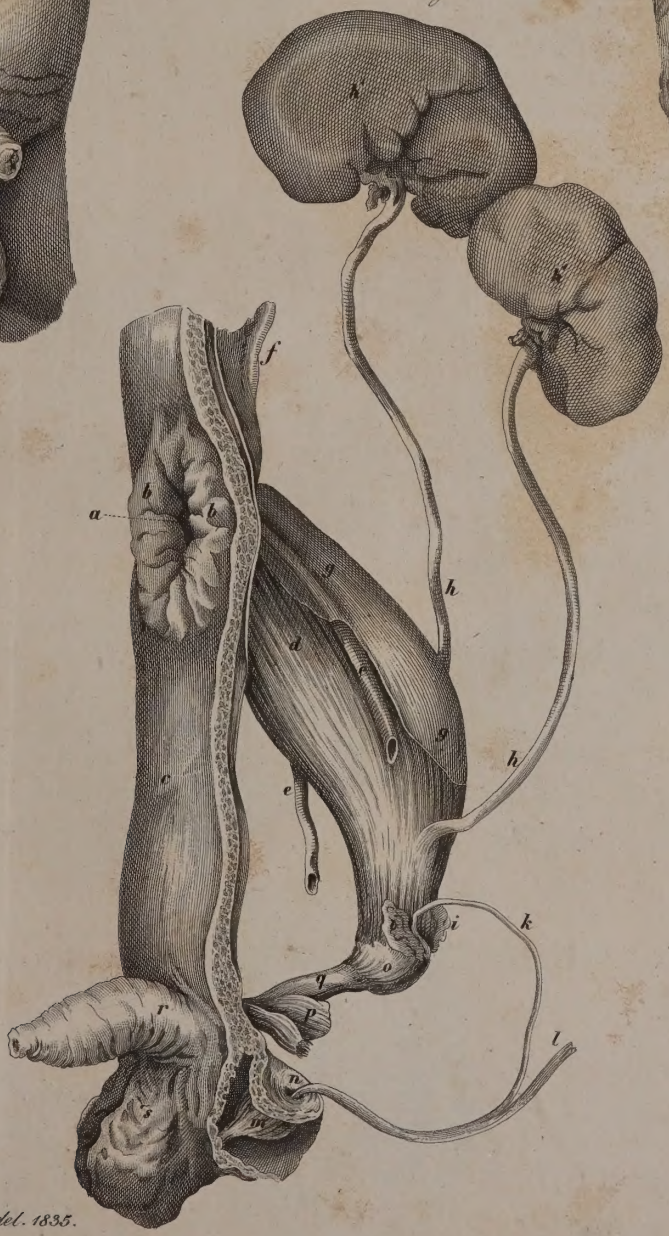

Dr. Robert Froriep ad nat. del. 1835.

B.

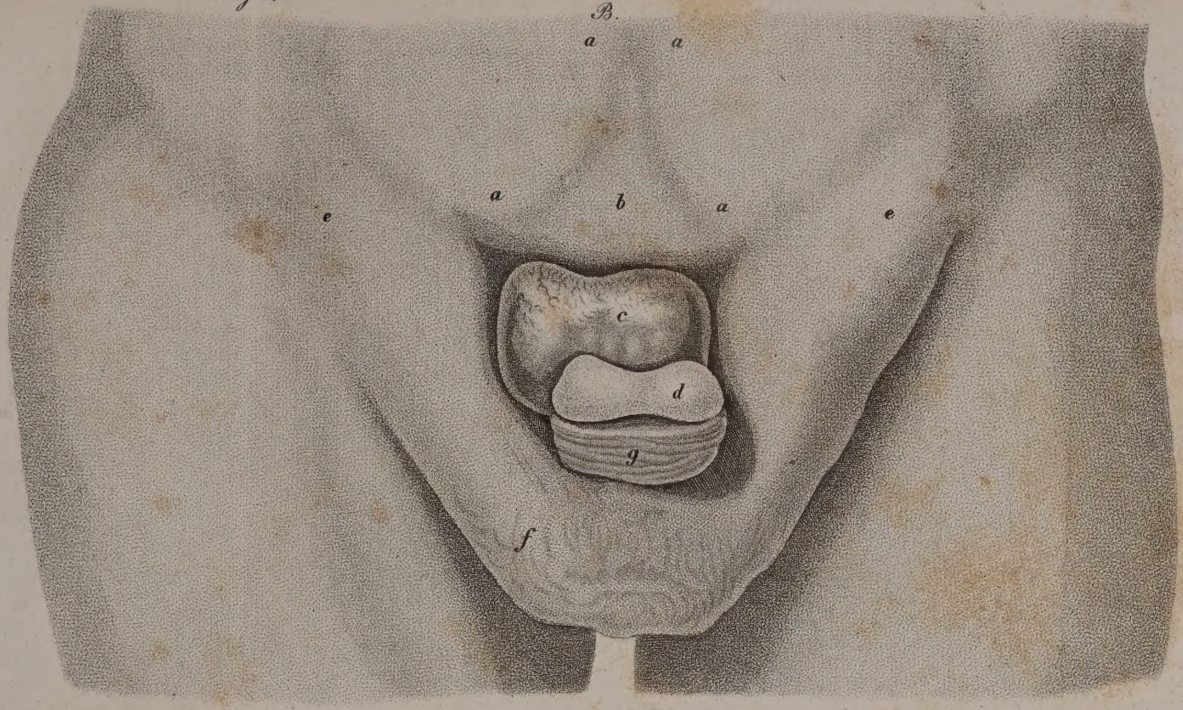

Fig. 2.

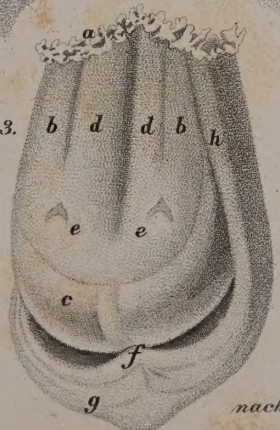

Fig. 3.

nach Originalzeichnungen.

Fig. 1.

Fig. 2.

Fig. 3.



Fig. 4.

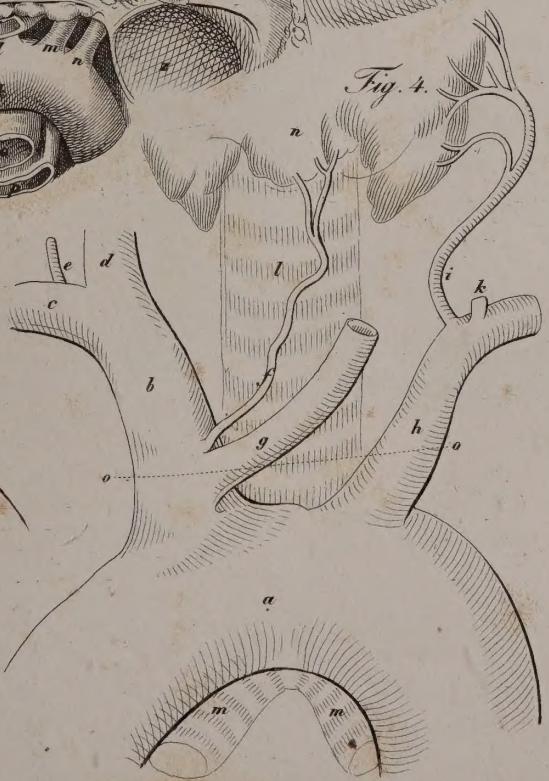

Fig. 5.

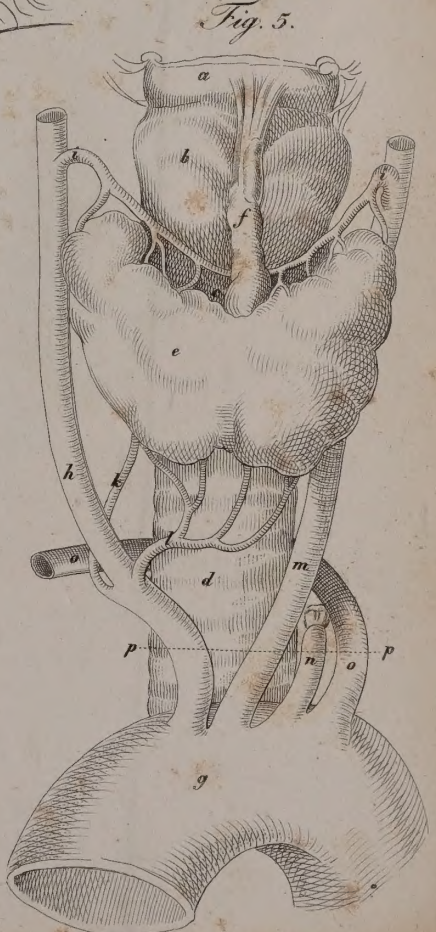

Dr. Robert Froriep ad nat. del.

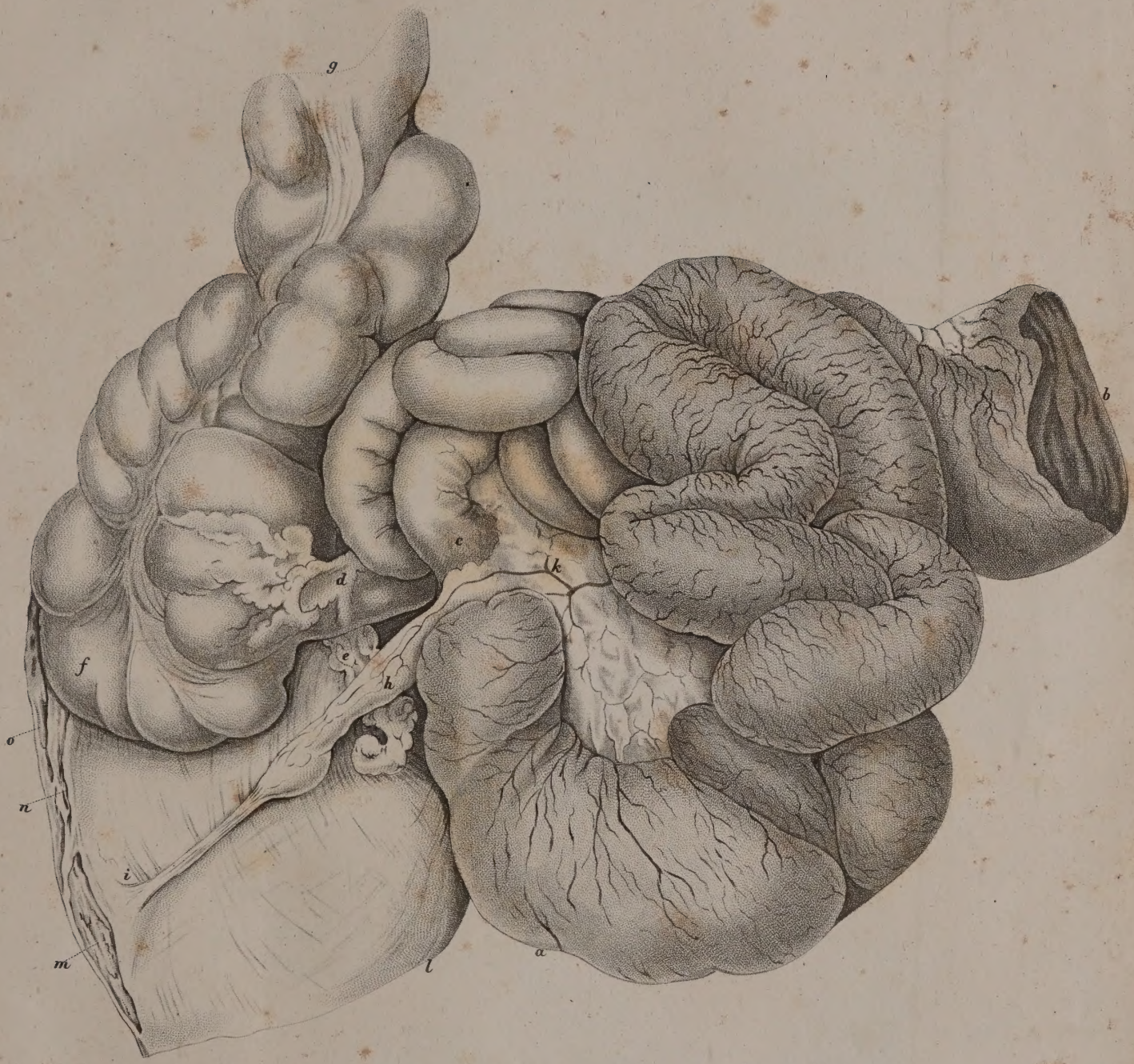
g
b
c
k
d
e
f
h
o
n
i
m
l
a

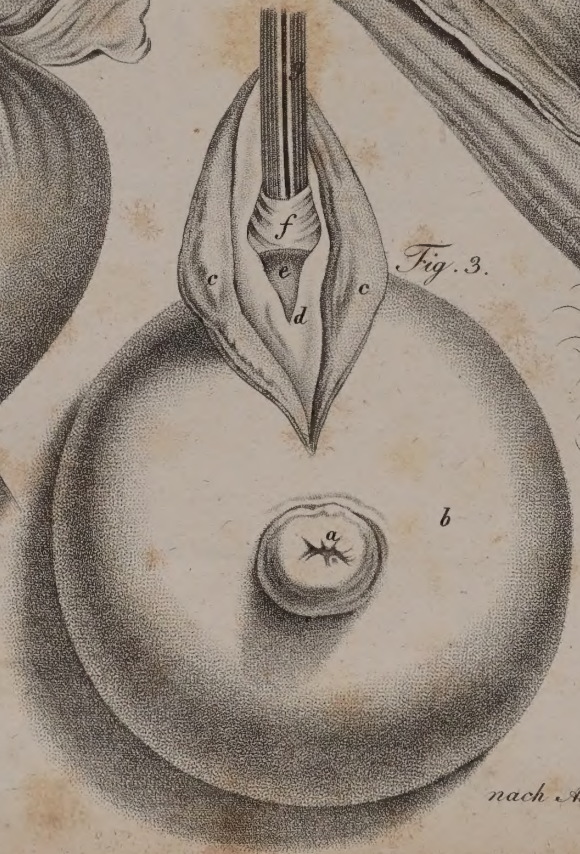

Fig. 3.

Fig. 4.

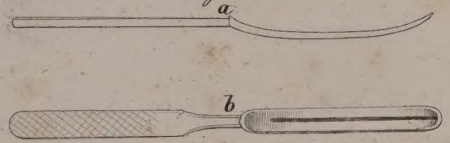

nach Aston Key.

Fractura

Taf. CCCXLV.

Fig. 15.

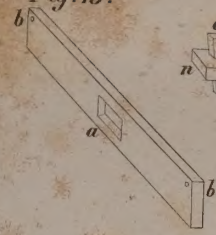

Fig. 14.



Fig. 16.

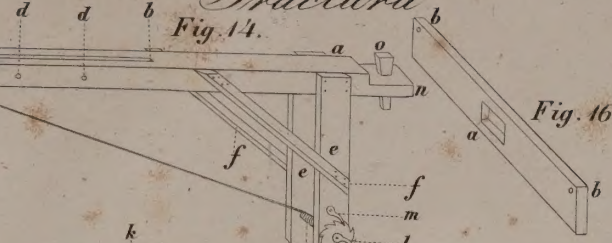

Fig. 13.

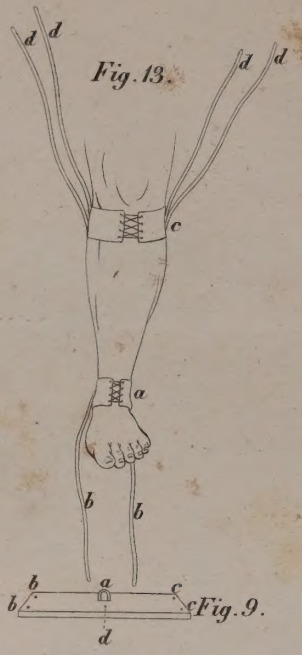

Fig. 2.

Fig. 1.

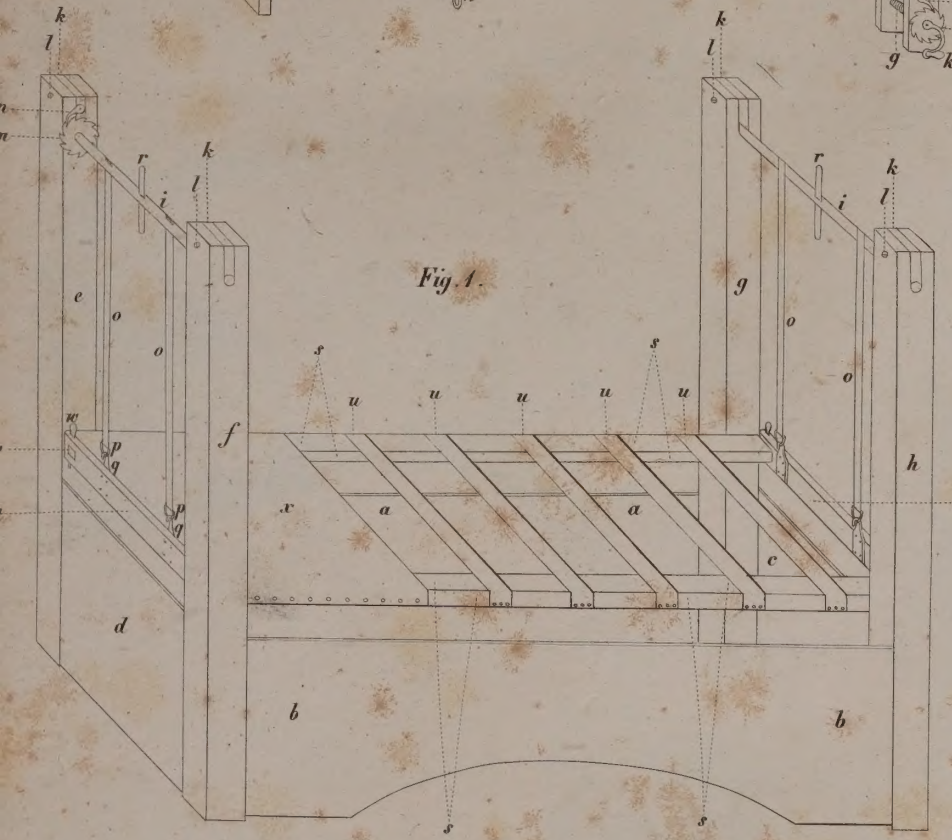

Fig. 9.

Fig. 10.

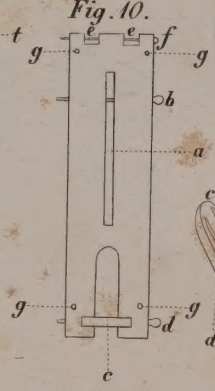

Fig. 7.

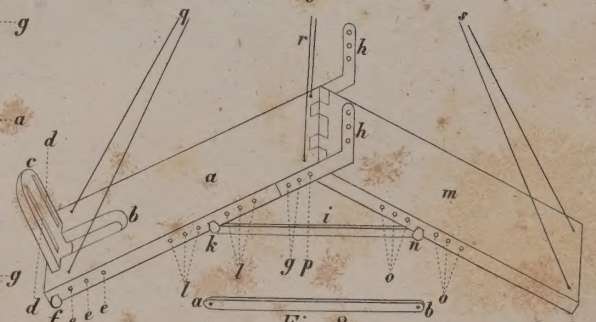

Fig. 8.

Fig. 12.

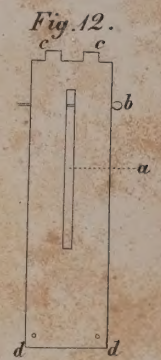

Fig. 3.

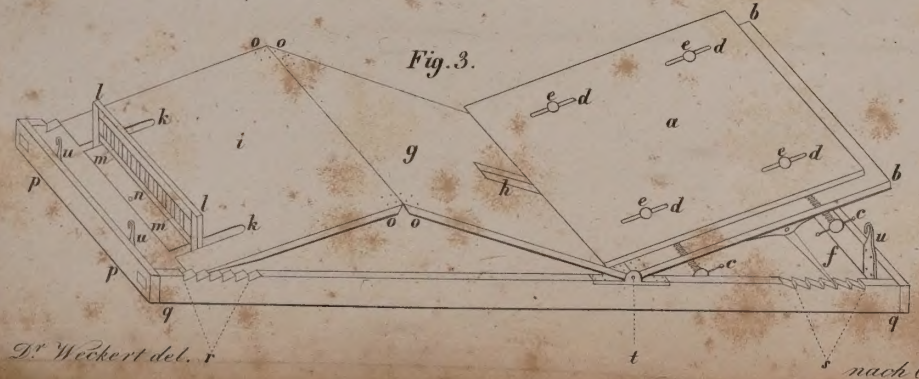

Fig. 11.

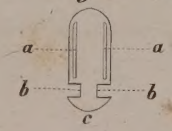

Fig. 5.



Fig. 4.

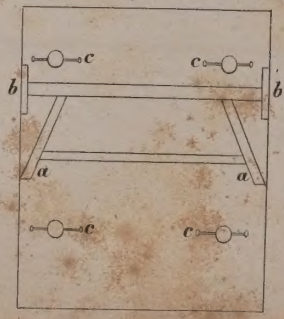

Fig. 6.

Contractura.

A

Fig. 1.

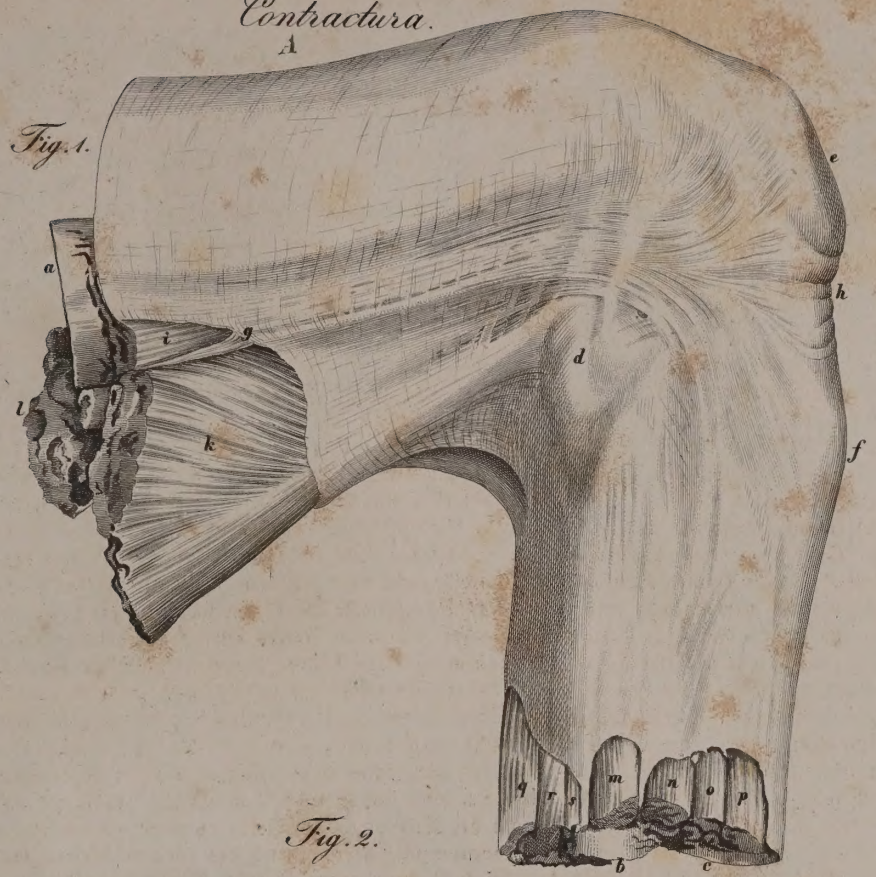

Fig. 2.

Dr. Robert Froriep ad nat. del.

Fig. 1. *Prostatae morbi.* Fig. 2. A. Taf. CCCXLVII.

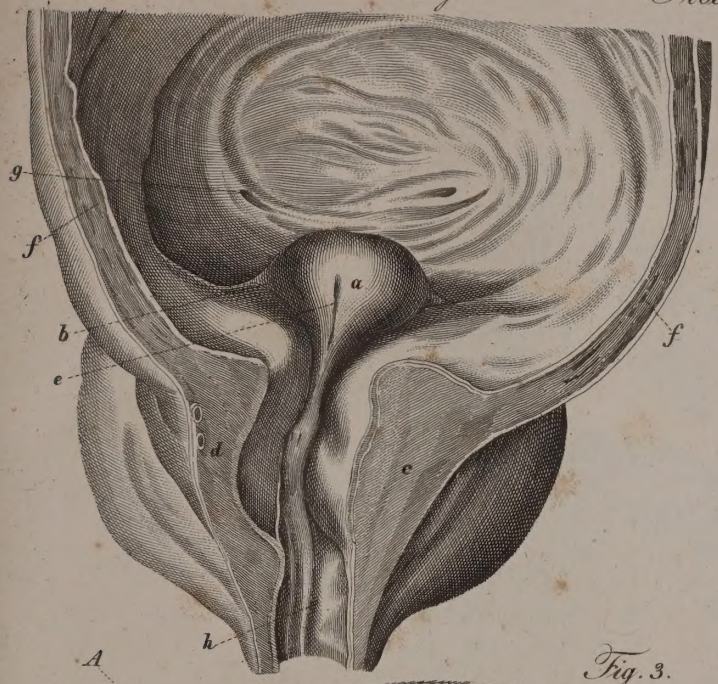

Fig. 2. B.

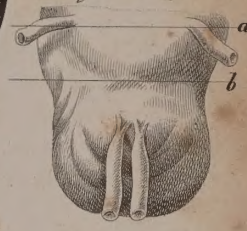

Fig. 3.

Fig. 4.

nach Home, Guthrie u. Baillie.

Fig. 1.

Fig. 2.

Fig. 2.

Dr. Robert Fiorieff ad nat. pinx.

Fig. 1.

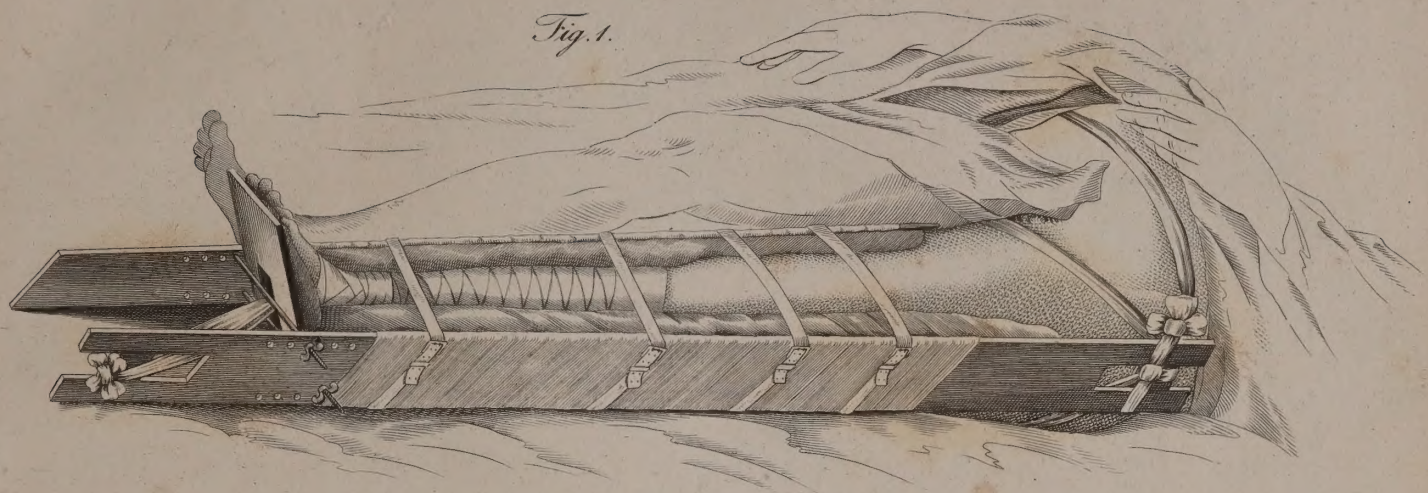

Fig. 2.

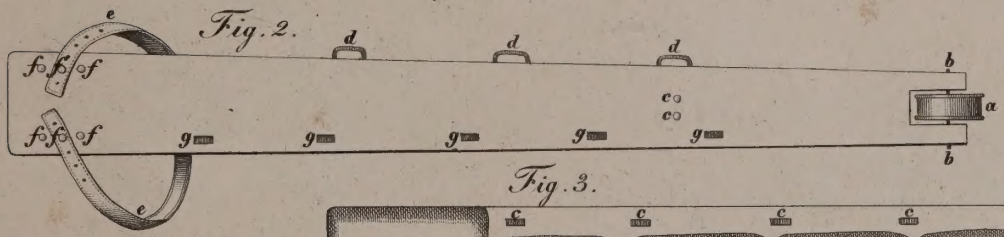

Fig. 3.

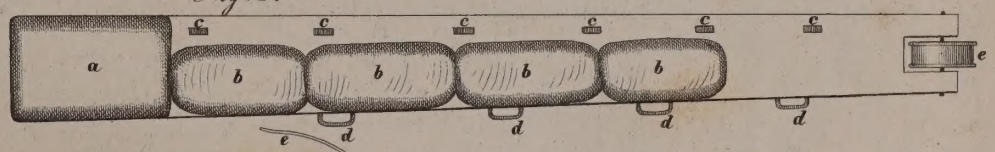

Fig. 4.

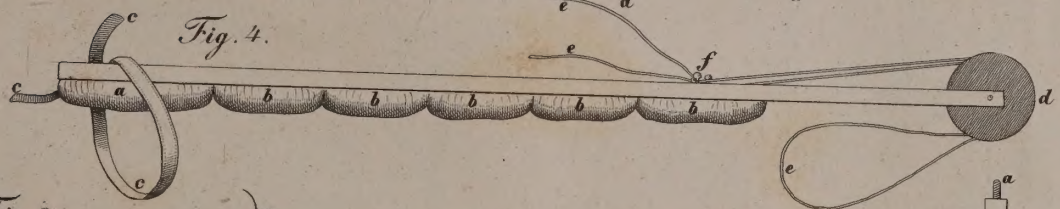

Fig. 5.

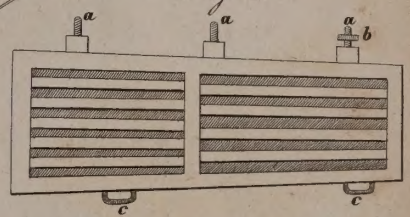

Fig. 6.

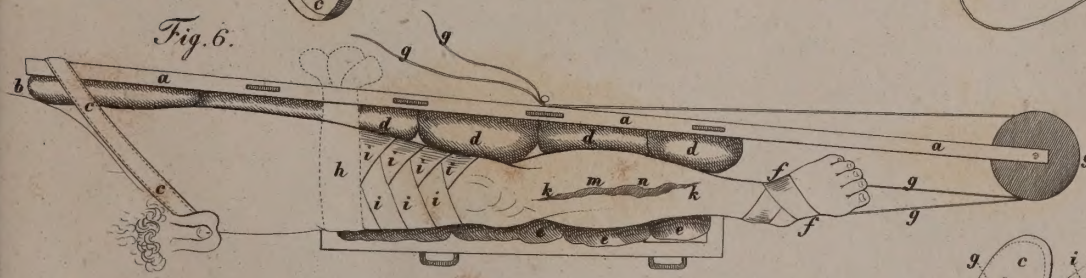

Fig. 8.

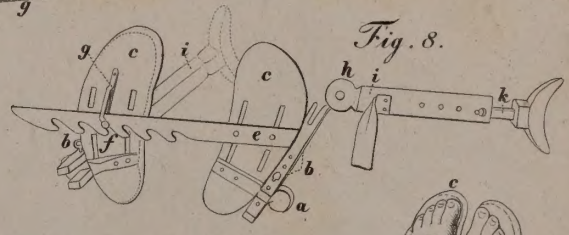

Fig. 7.

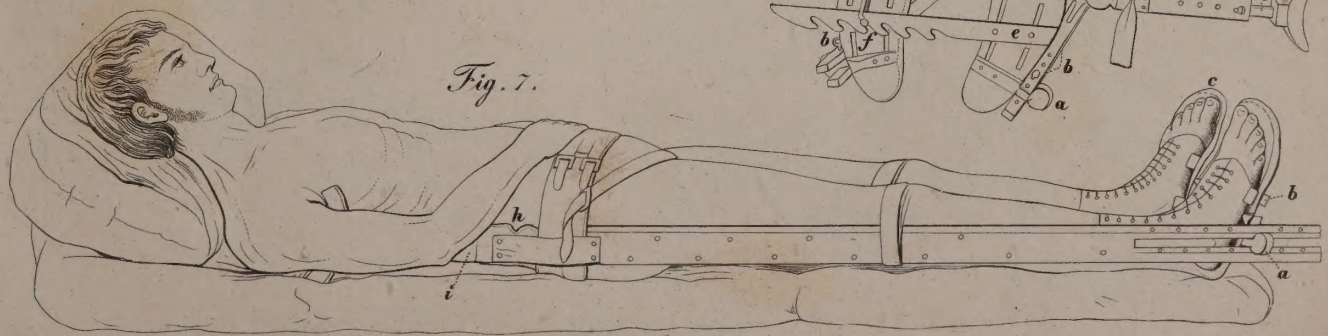

nach Houston, Schürmayer und Szerlecki.

Fig. 1.

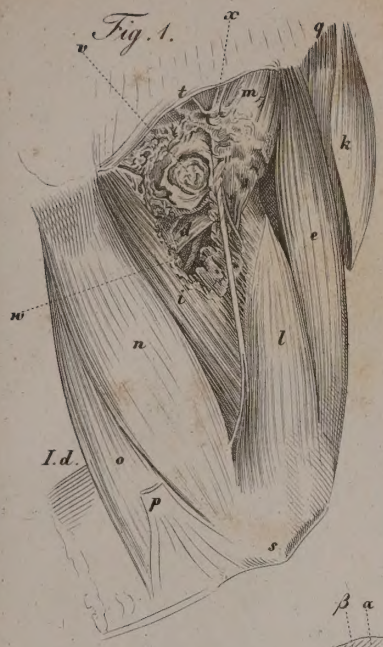

Fig. 2.

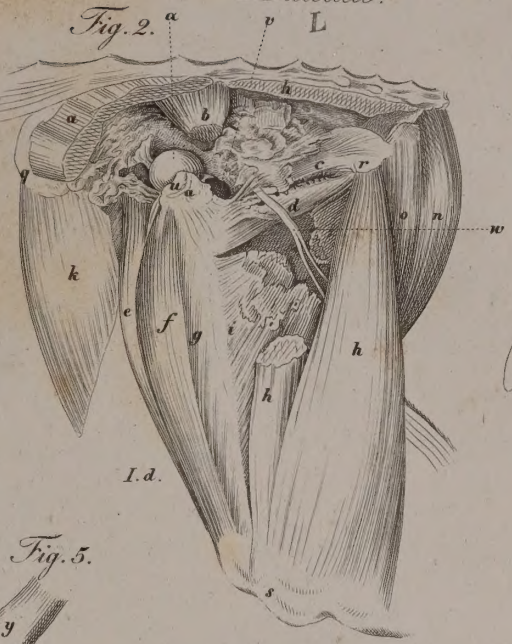

Fig. 3.

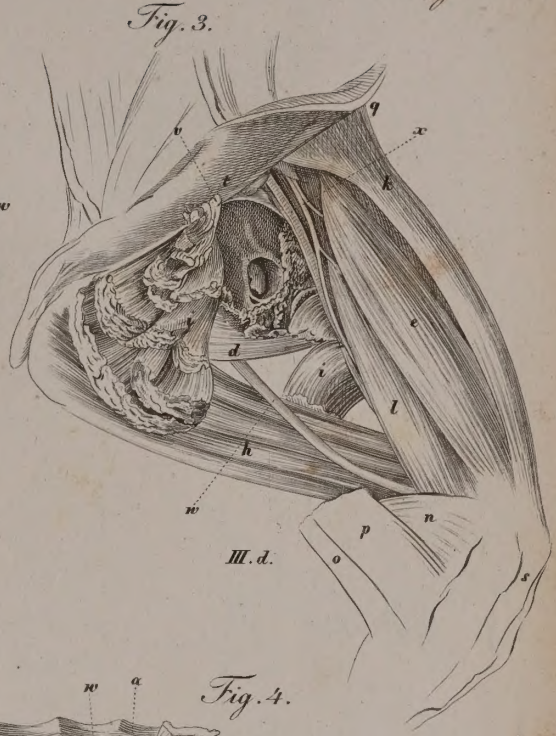

Fig. 5.

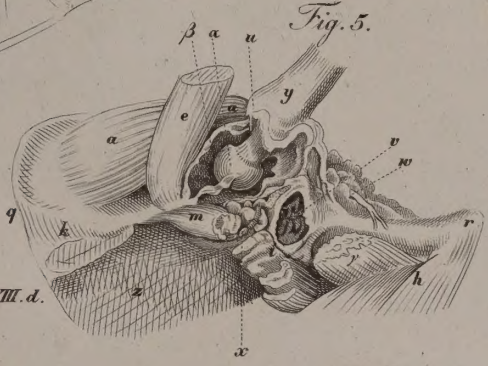

Fig. 4.

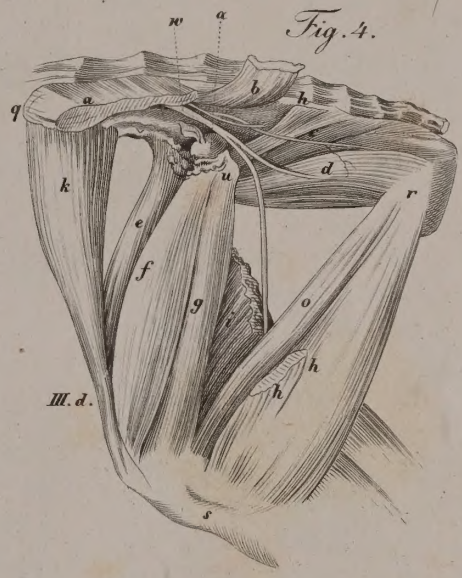

Fig. 6.

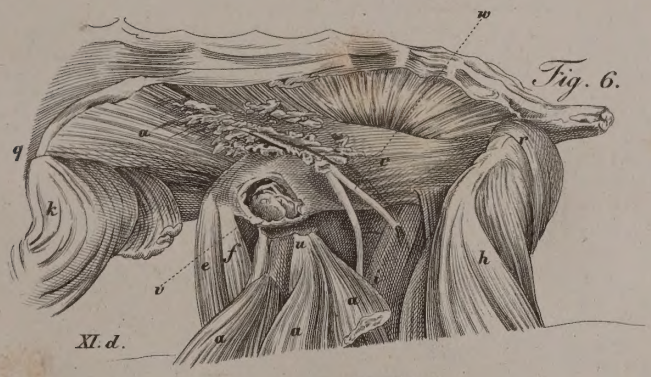

Fig. 7.

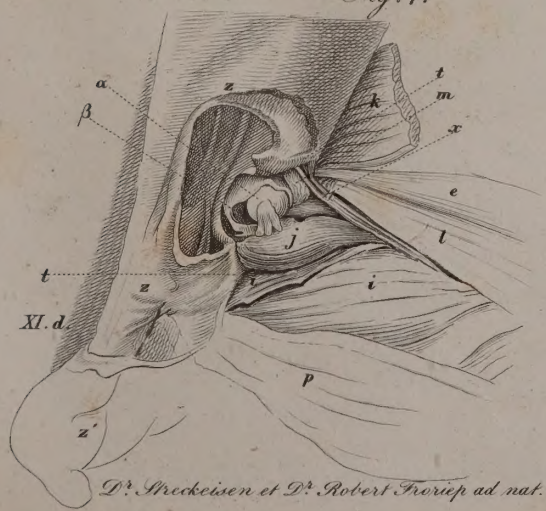

Fig. 8.

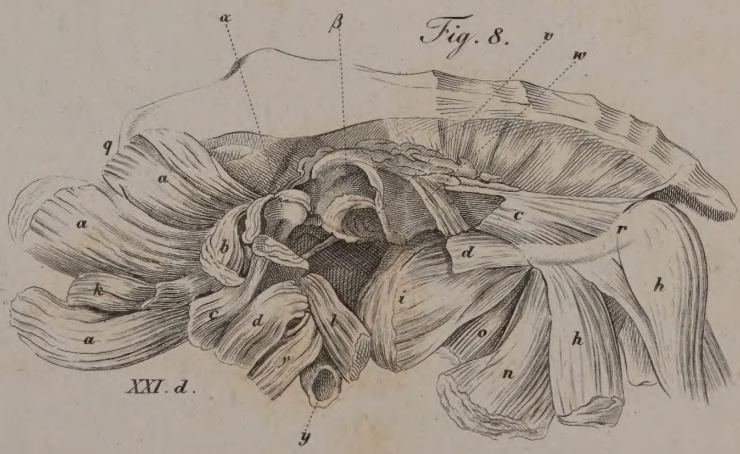

D^r. Streckeisen et D^r. Robert Froriep ad. nat. del.

nach De Wette.

Fig. 1.

Fig. 3.

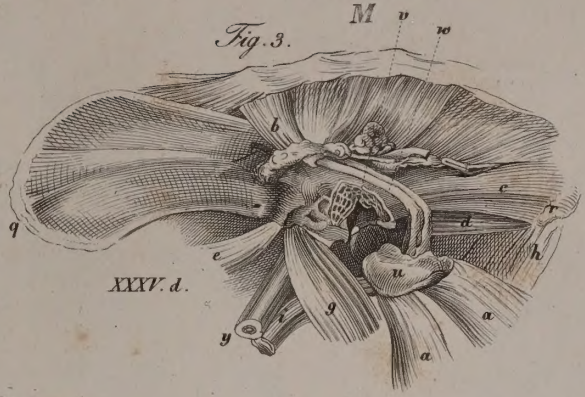

Fig. 4.

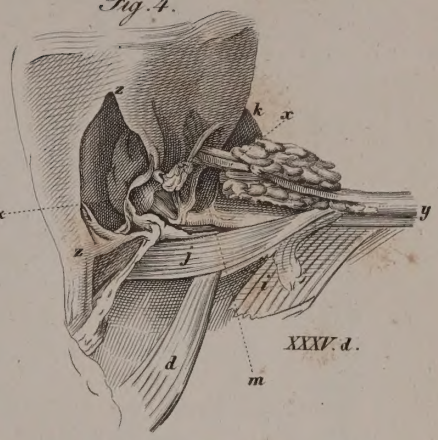

Fig. 2.

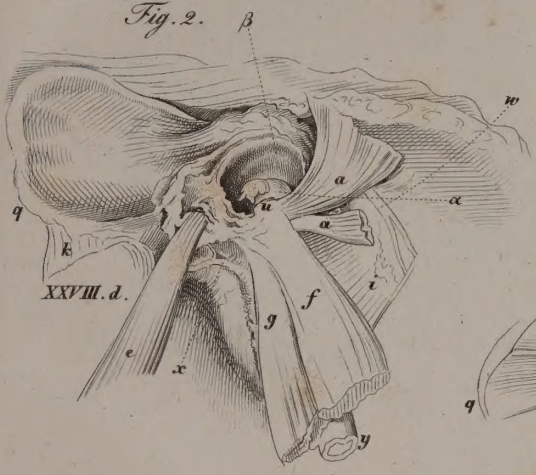

Fig. 5.

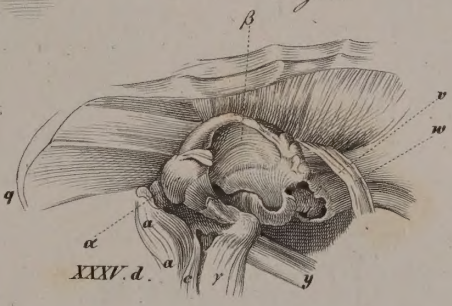

Fig. 6.

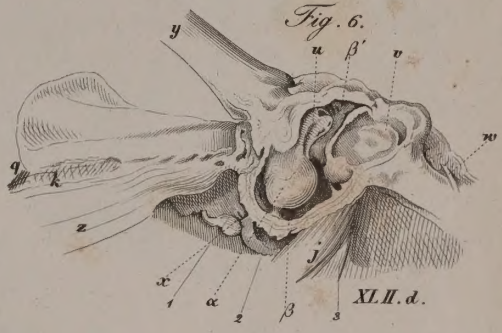

Fig. 7.

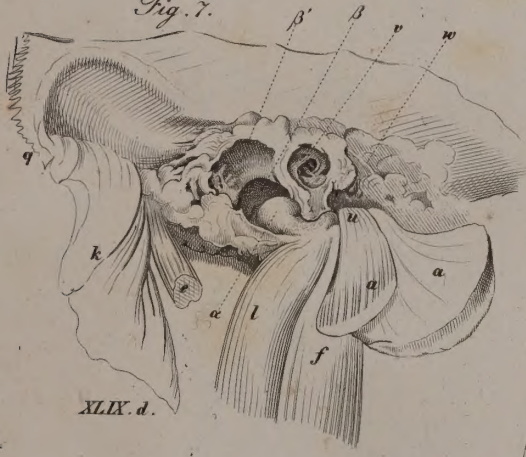

Fig. 9.

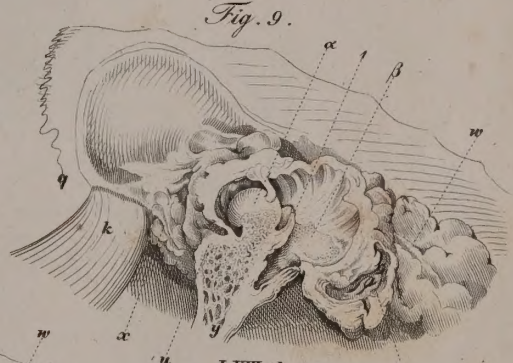

Fig. 8.

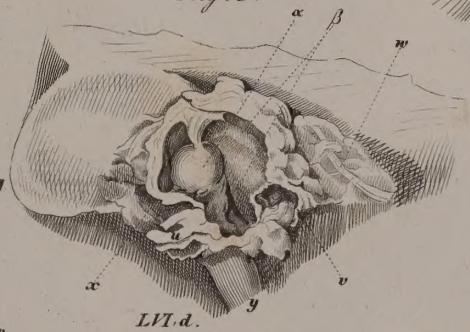

Fig. 10.

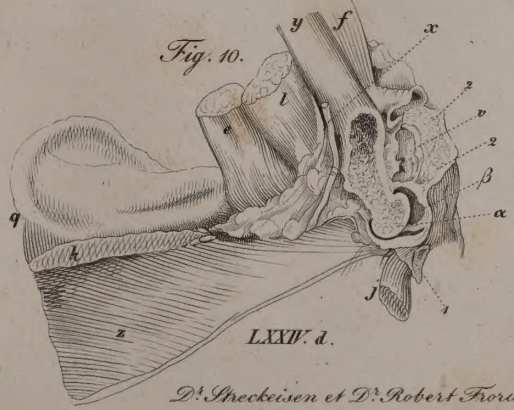

Fig. 11.

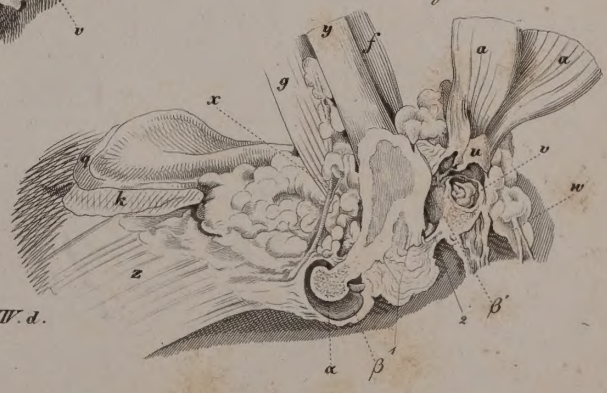

Dr. Streckeisen et Dr. Robert Froriep ad. nat. del.

nach De Wette.

Induratio tunicae vaginalis testis.

Fig. 1.

Fig. 2.

Fig. 3.

Dr. Robert Fuerigs ad nat. pinx.

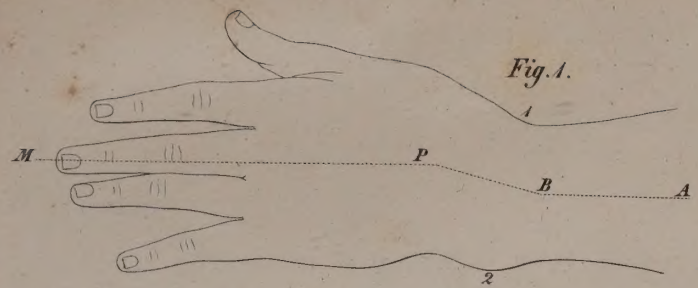

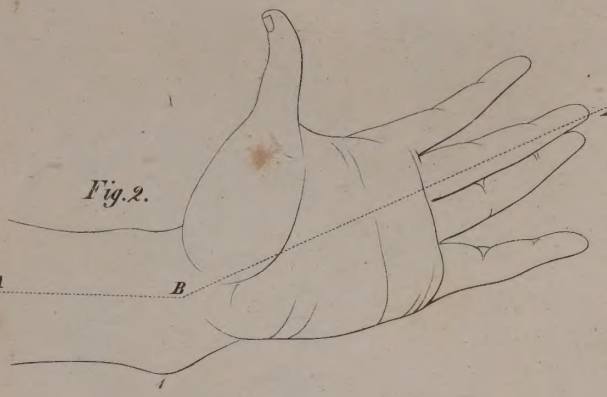

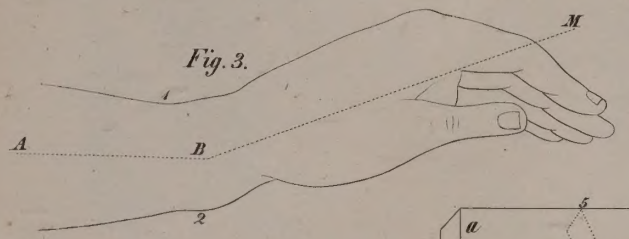

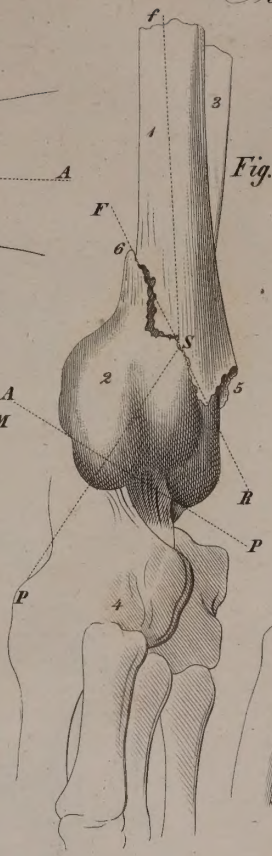

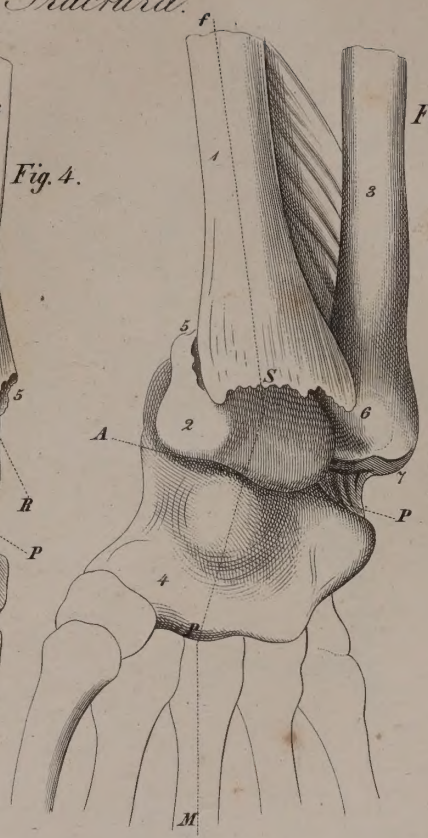

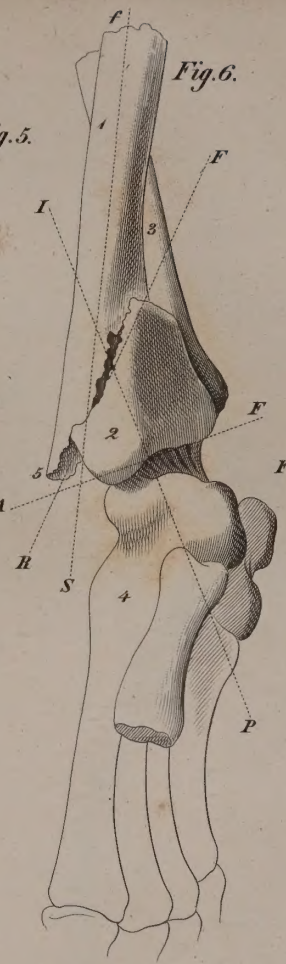







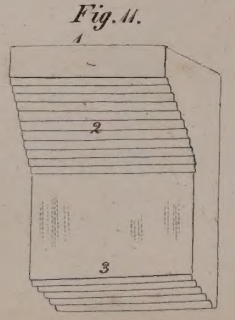

nach Goyrand.

Fig. 1.

Fig. 2.

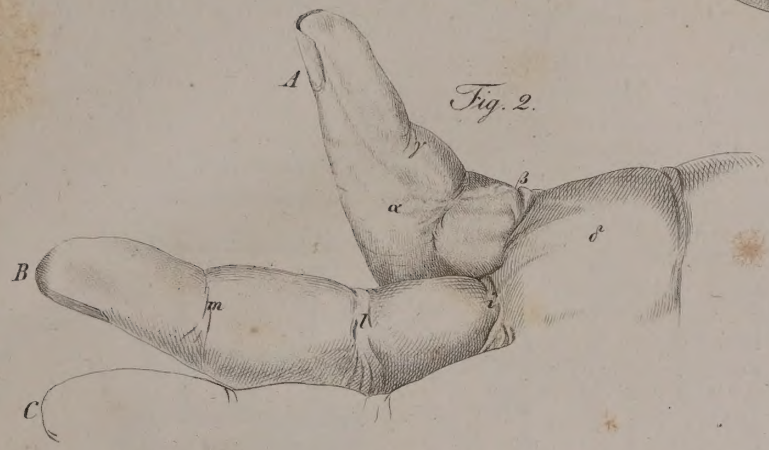

Fig. 4.

Fig. 3.

Fig. 5.

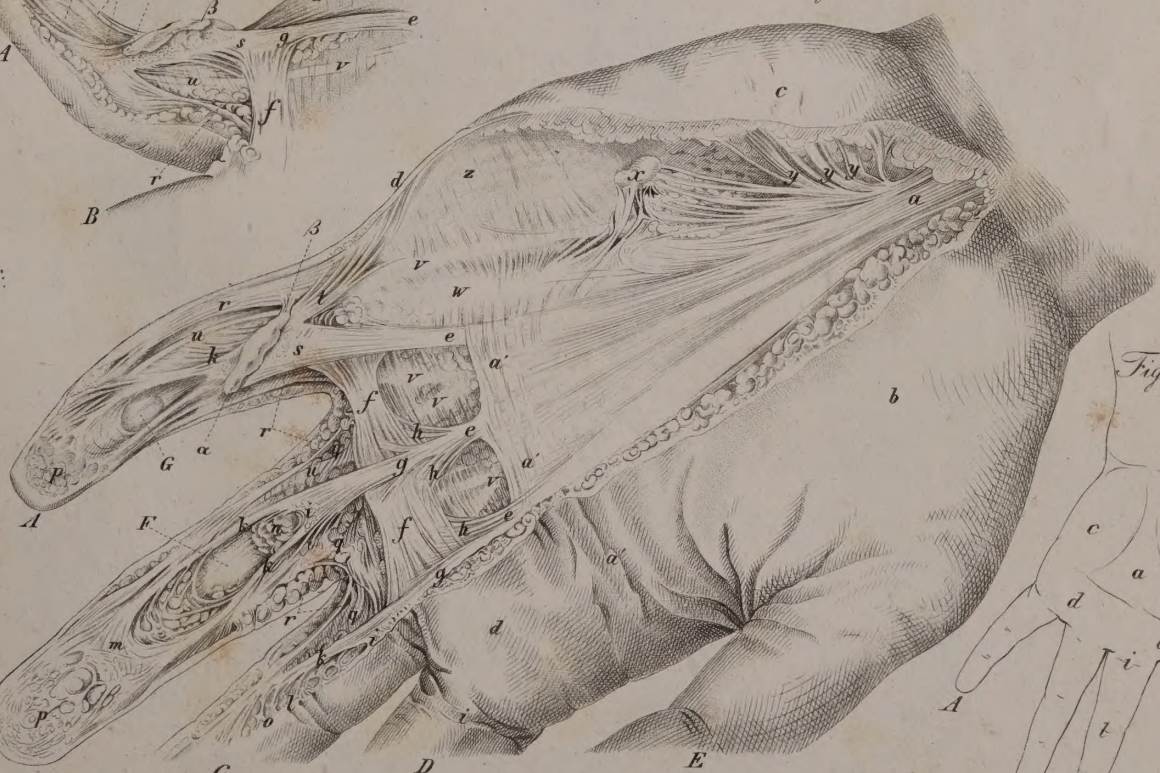

Fig. 7.

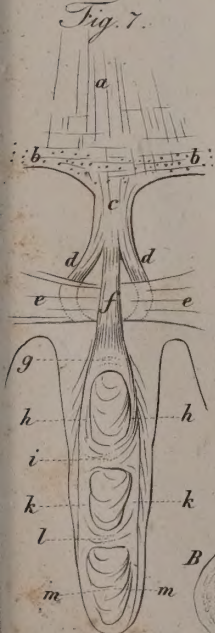

Fig. 6.

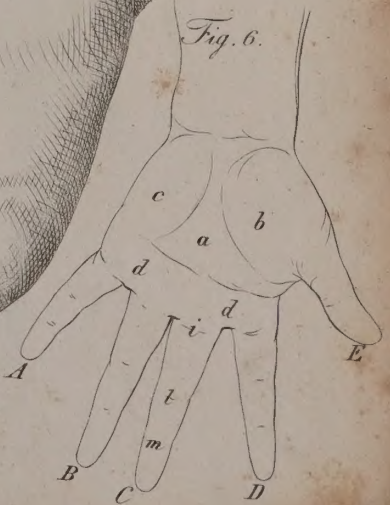

Dr Robert Fioriep ad nat. del.

Uteri injectio.

A.

Fig. 1.



Fig. 2.

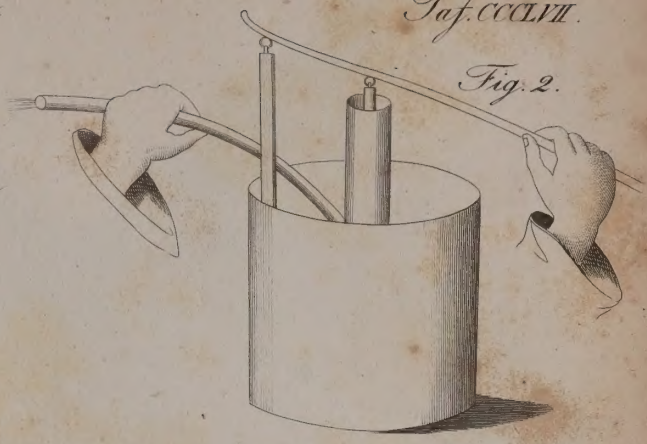

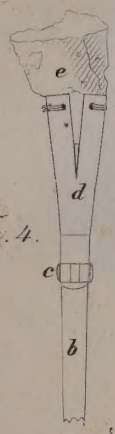

Fig. 4.

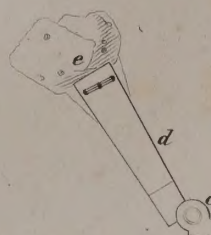

Fig. 3.

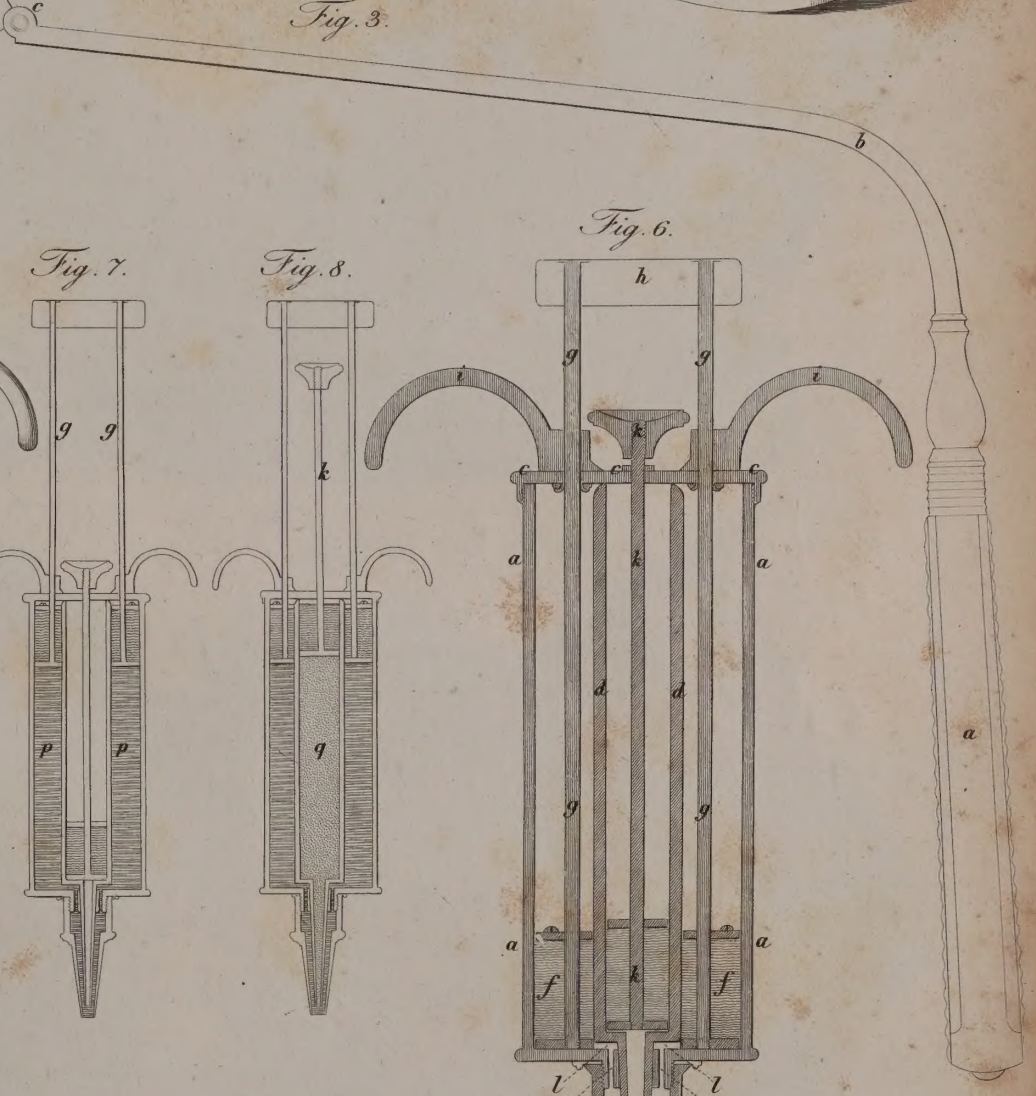

Fig. 5.



Fig. 7.

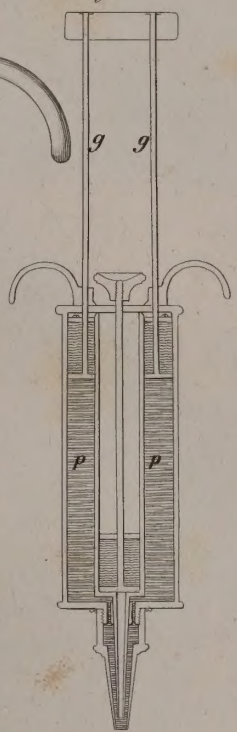

Fig. 8.

Fig. 6.

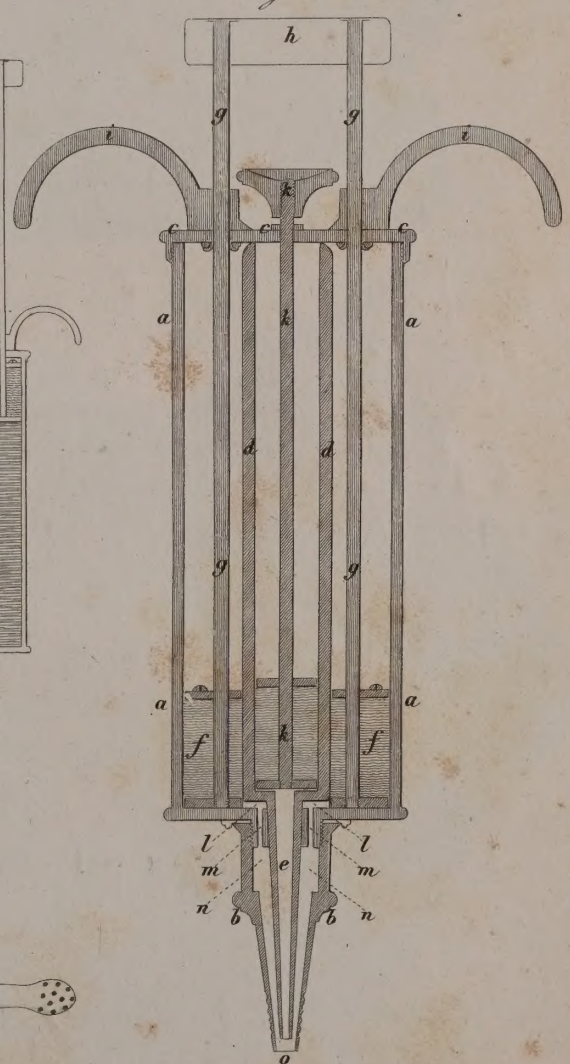

Fig. 9.

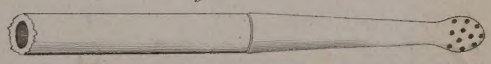

nach Lair und Originalzeichnungen

Lithotomia.
T.

Taf. CCCLVIII.

Fig. 1.

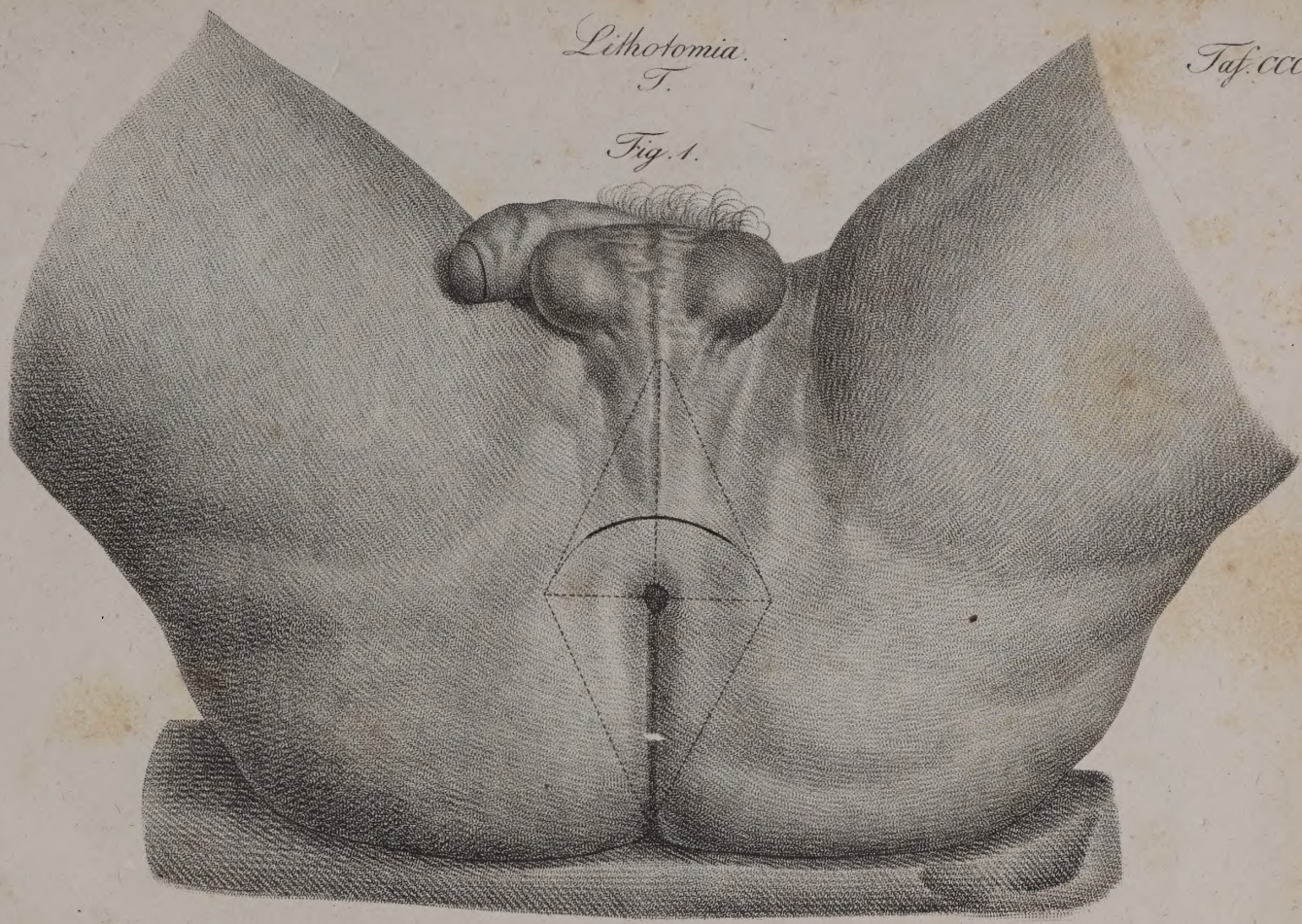

Fig. 2.

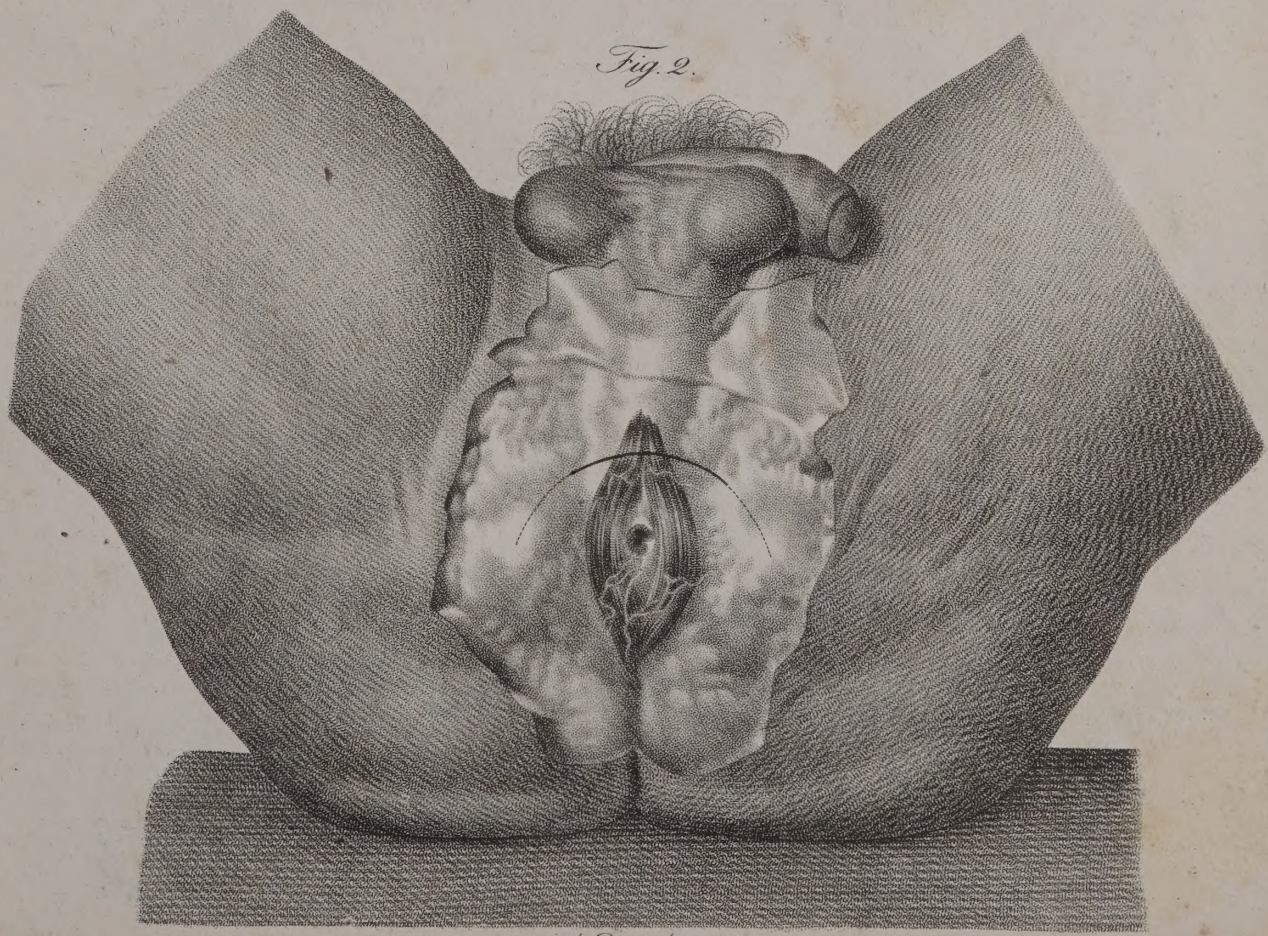

nach Dupuytren.

Lithotomia.

Taf. CCCLIX.

Fig. 1. U.

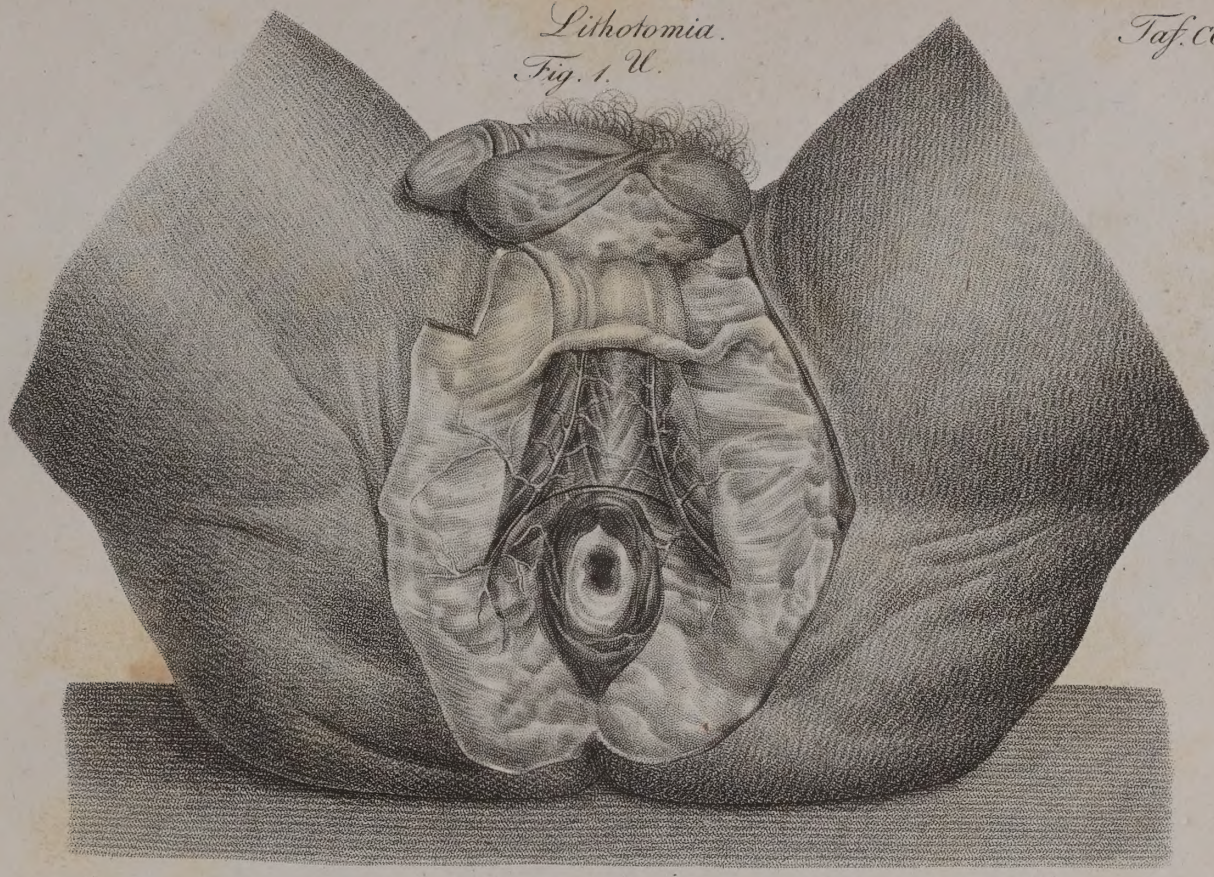

Fig. 2.

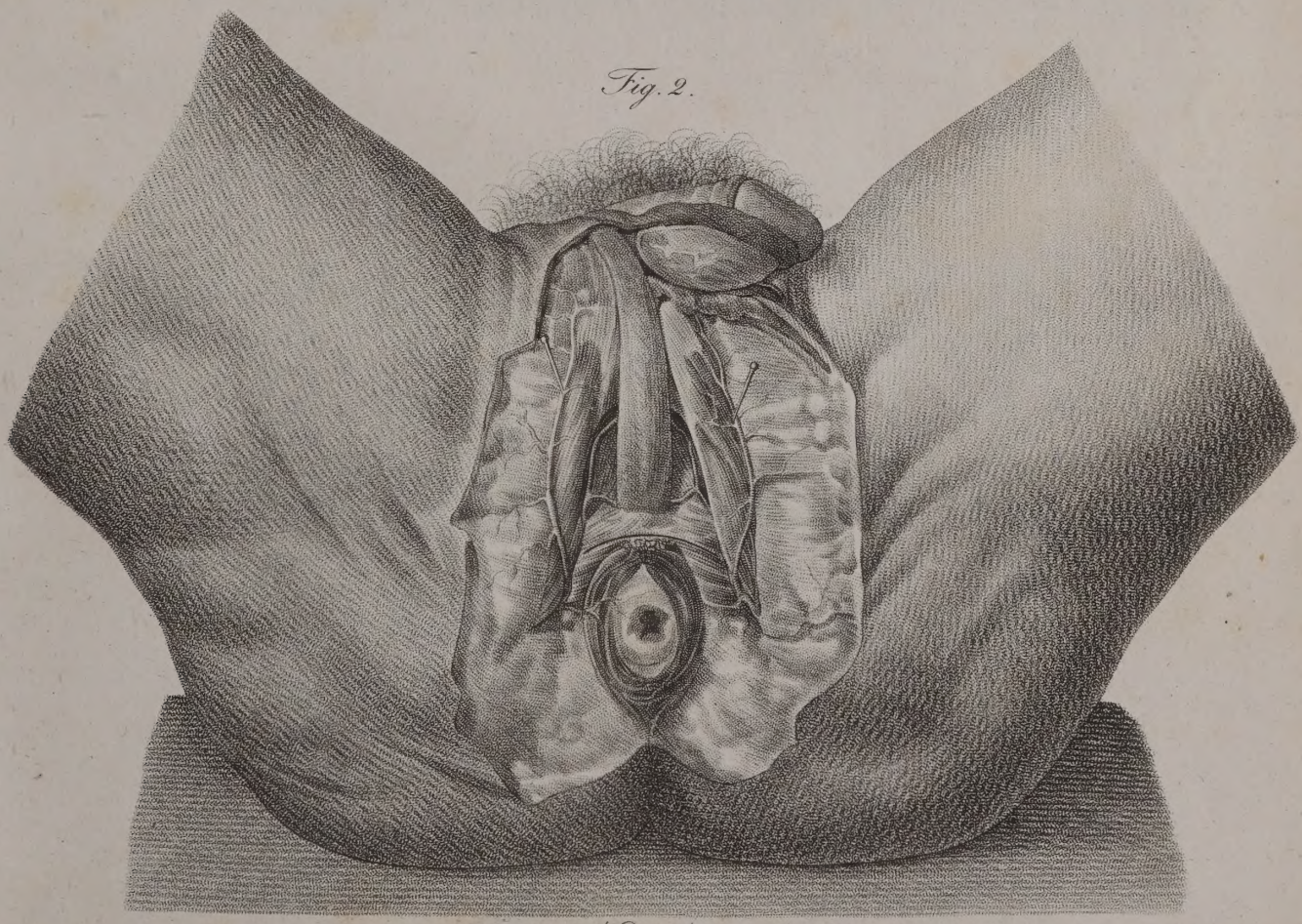

nach Dupuytren.

Lithotomia.
V.

Taf. CCCLX.

Fig. 1.

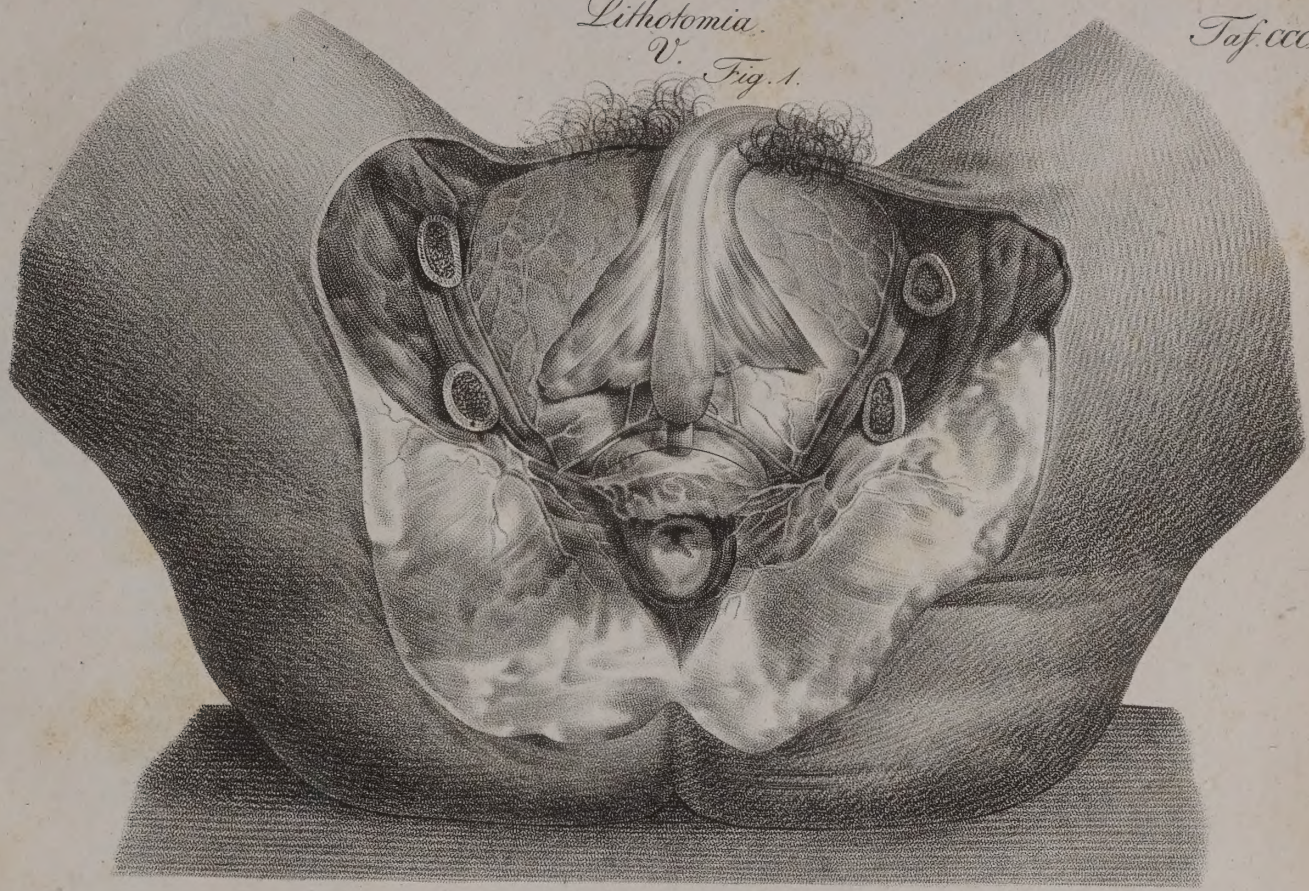

Fig. 2.

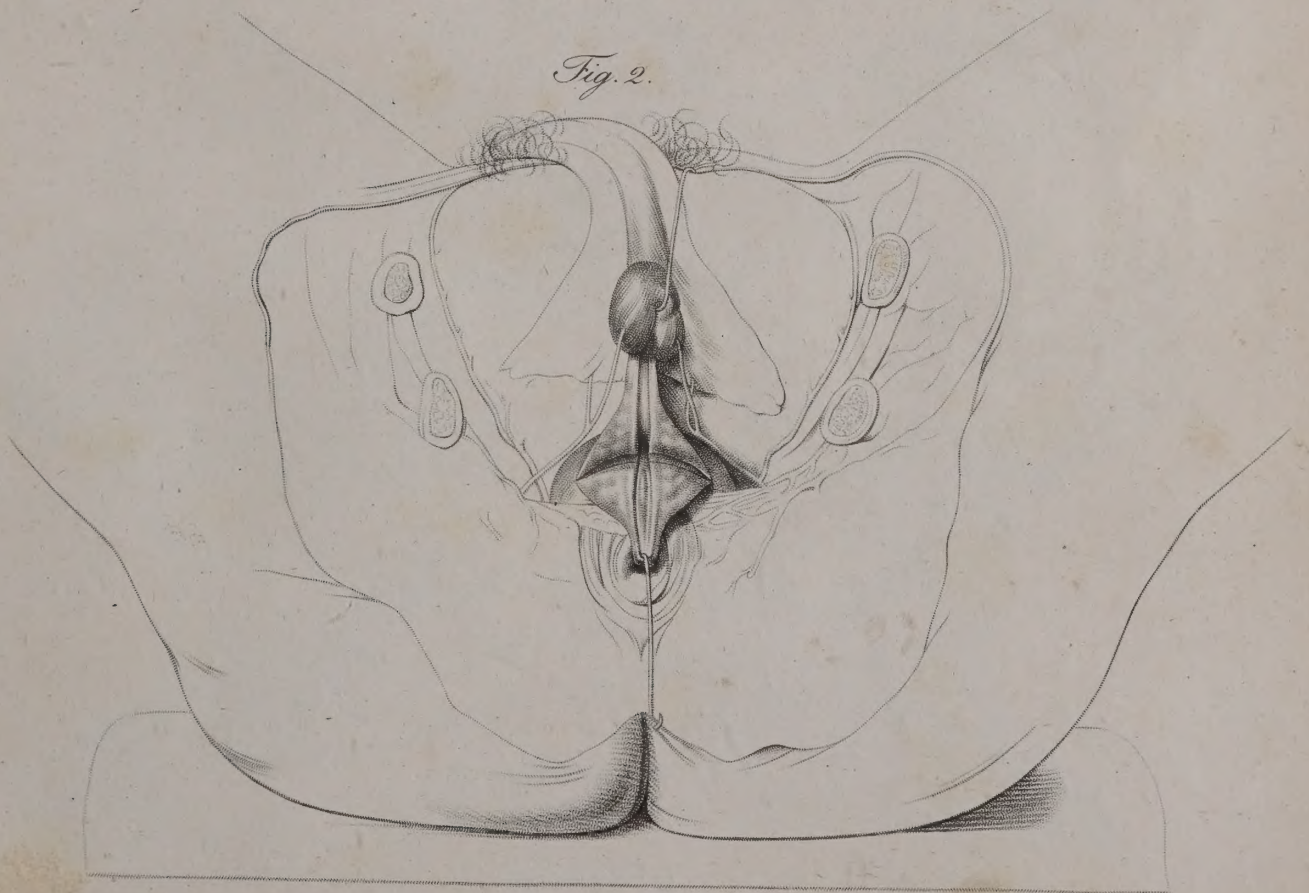

nach Dupuytren.

Lithotomia.
W.

Taf. CCCLXI.

Fig. 1.

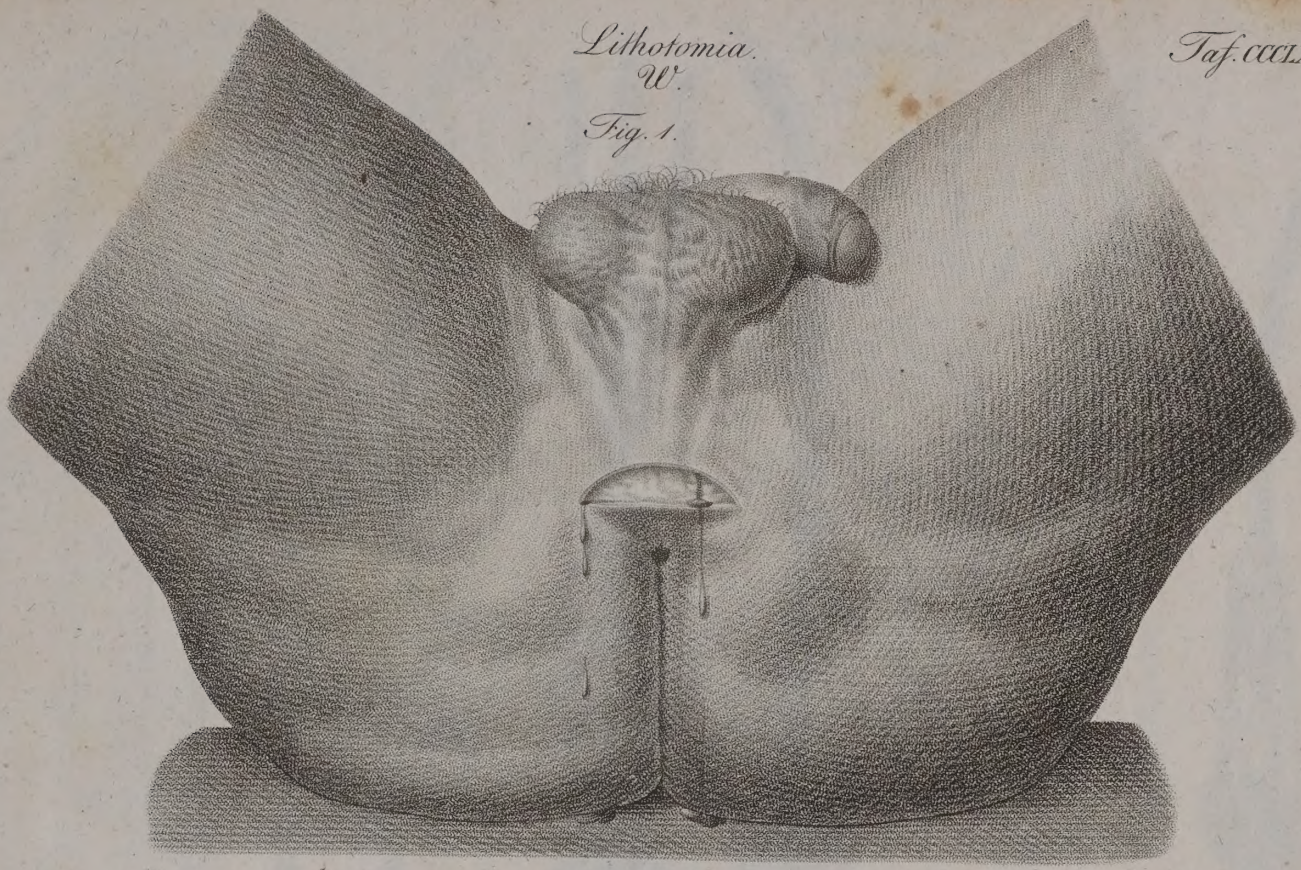

Fig. 2.

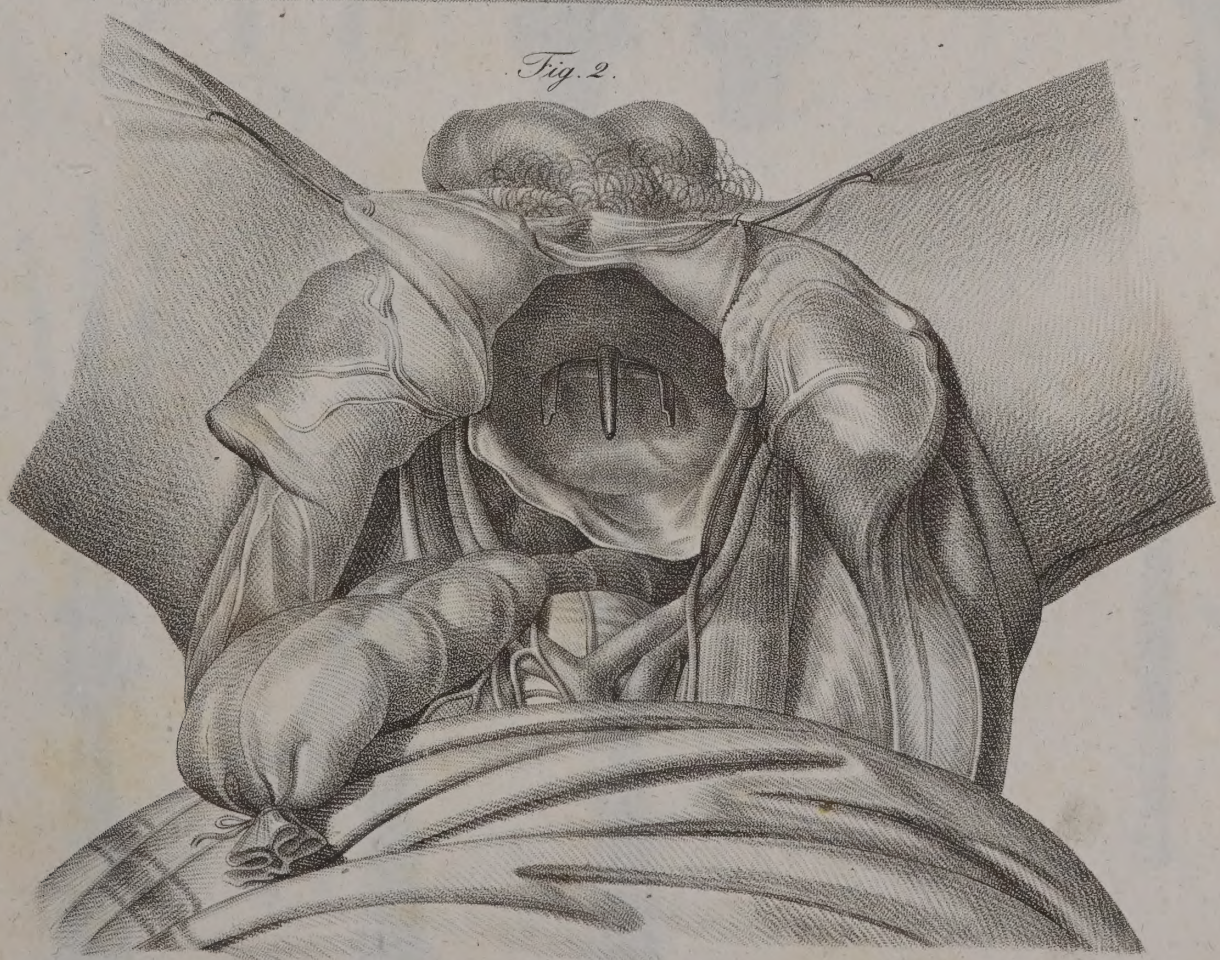

nach Dupuytren.

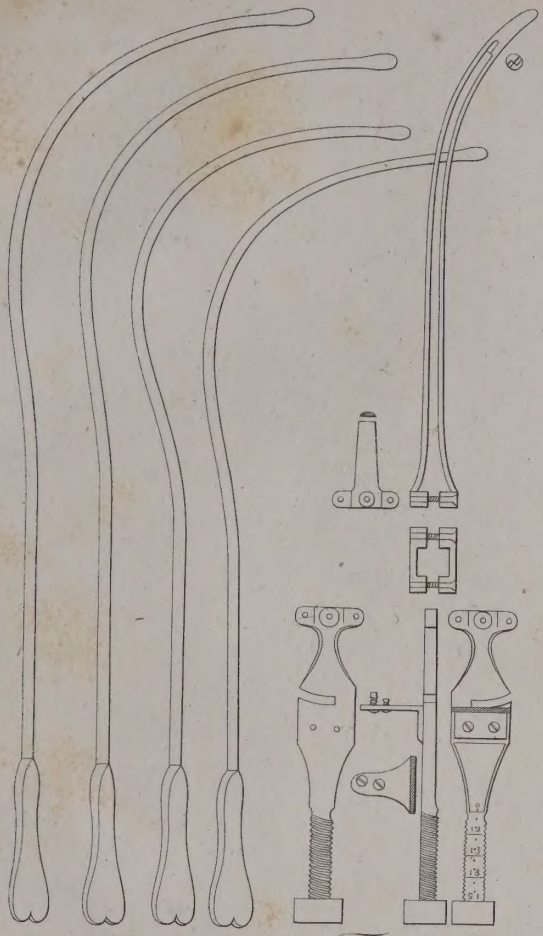

Fig. 1.

Fig. 6.

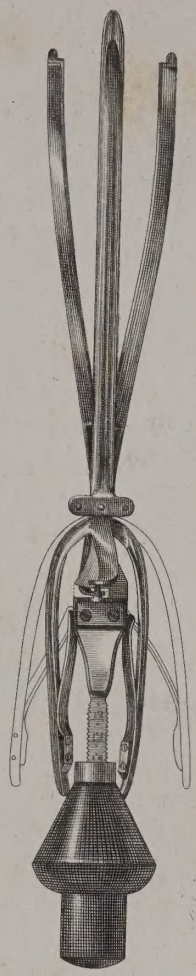

Fig. 5.

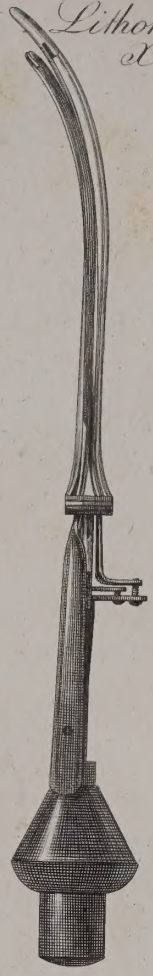

Fig. 4.

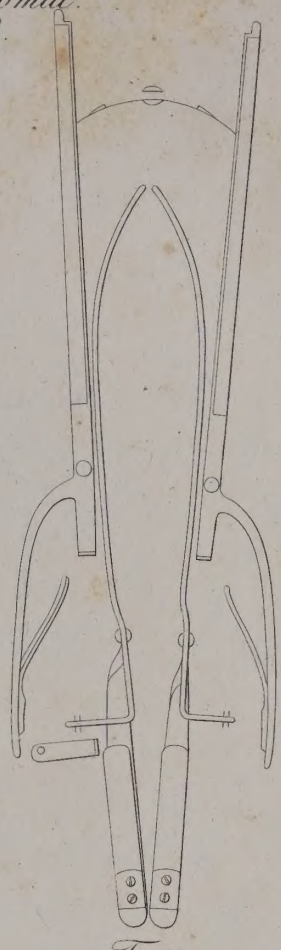

Fig. 7.

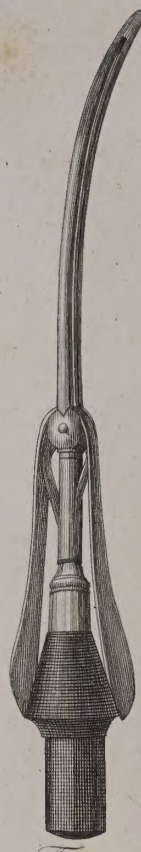

Fig. 3.

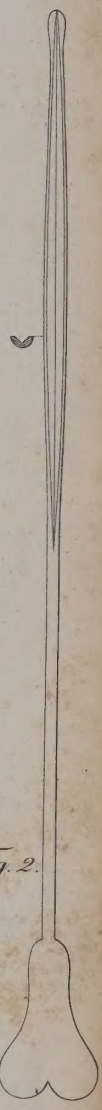

Fig. 2.



Fig. 8.

Fig. 9.

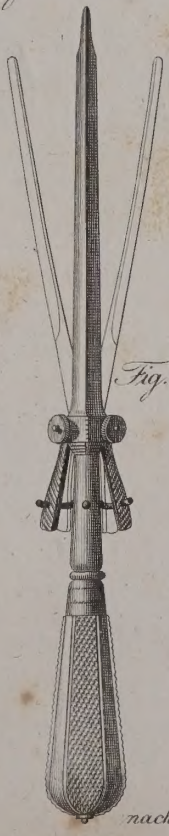

Fig. 10.

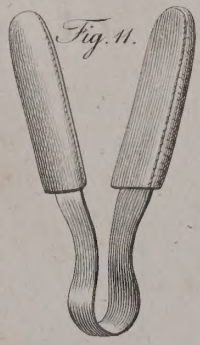

Fig. 11.

Fig. 12.

nach Dupuytren.

Cornu praeputiale. Taf. CCCLXIII. CCCLXIV.

B.

Fig. 1.

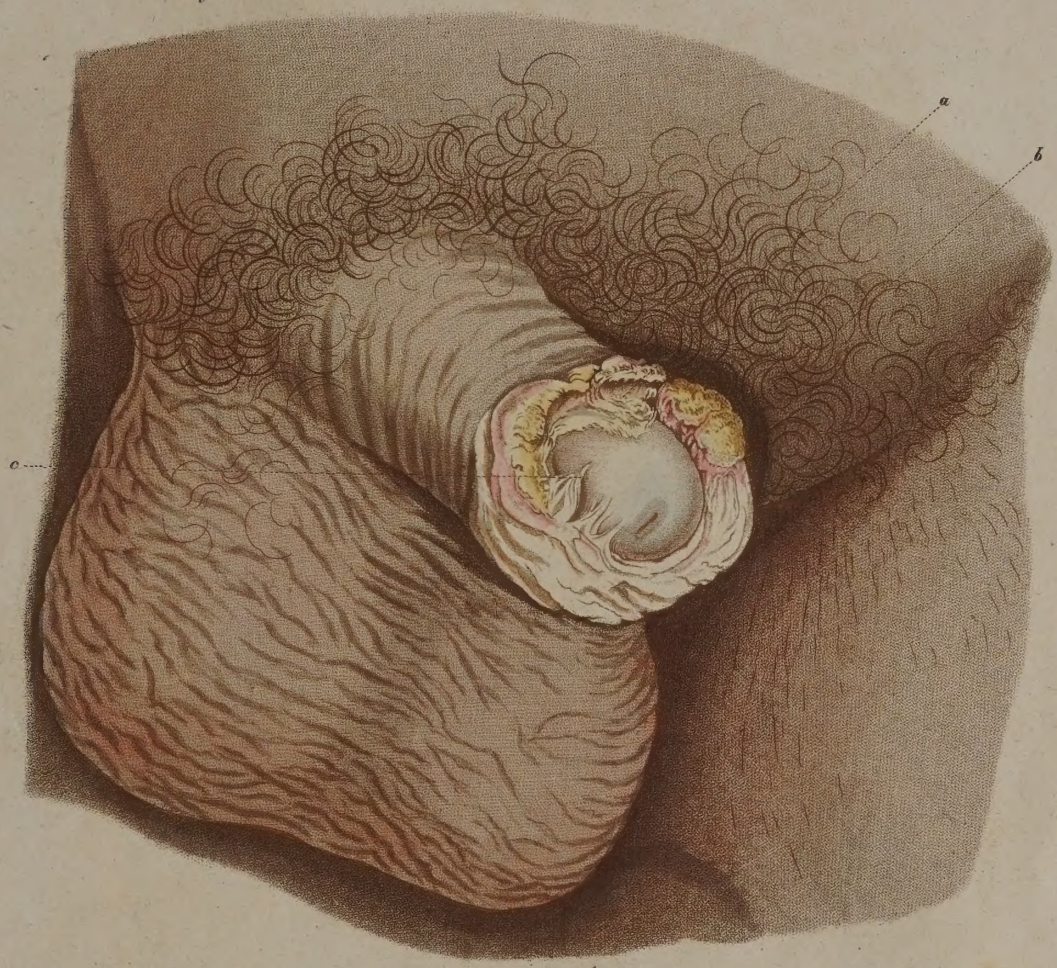

Fig. 2.

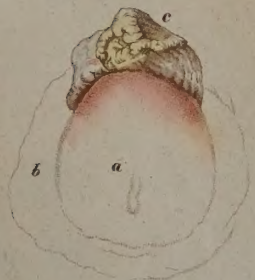

Fig. 3.

Fig. 4.

Fig. 5.

Dr. Robert Froriep ad nat. pinx.

Aneurisma.

Taf. CCCLXV.

Fig. 1.

Fig. 2.

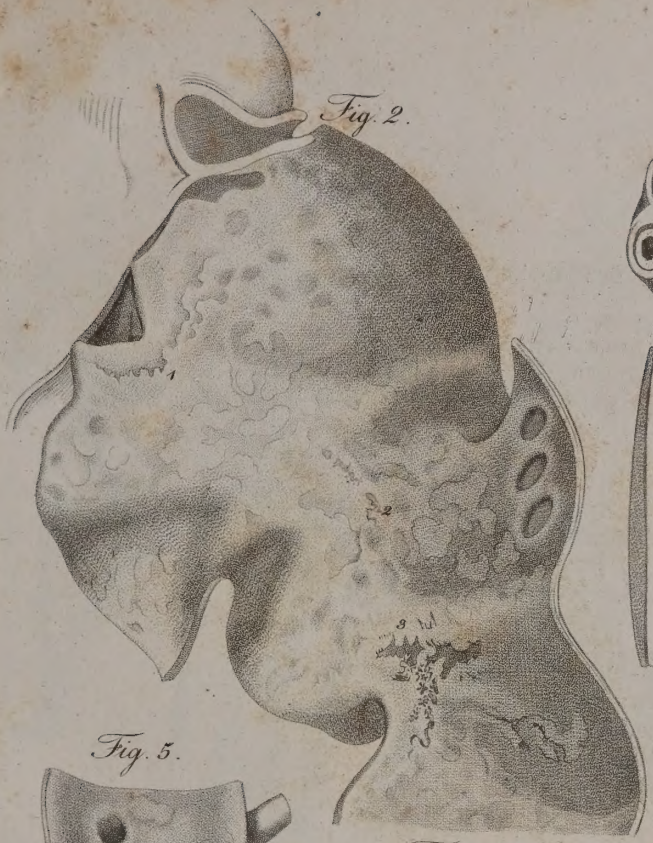

Fig. 3.

Fig. 4.

Fig. 5.

Fig. 6.

Fig. 7.

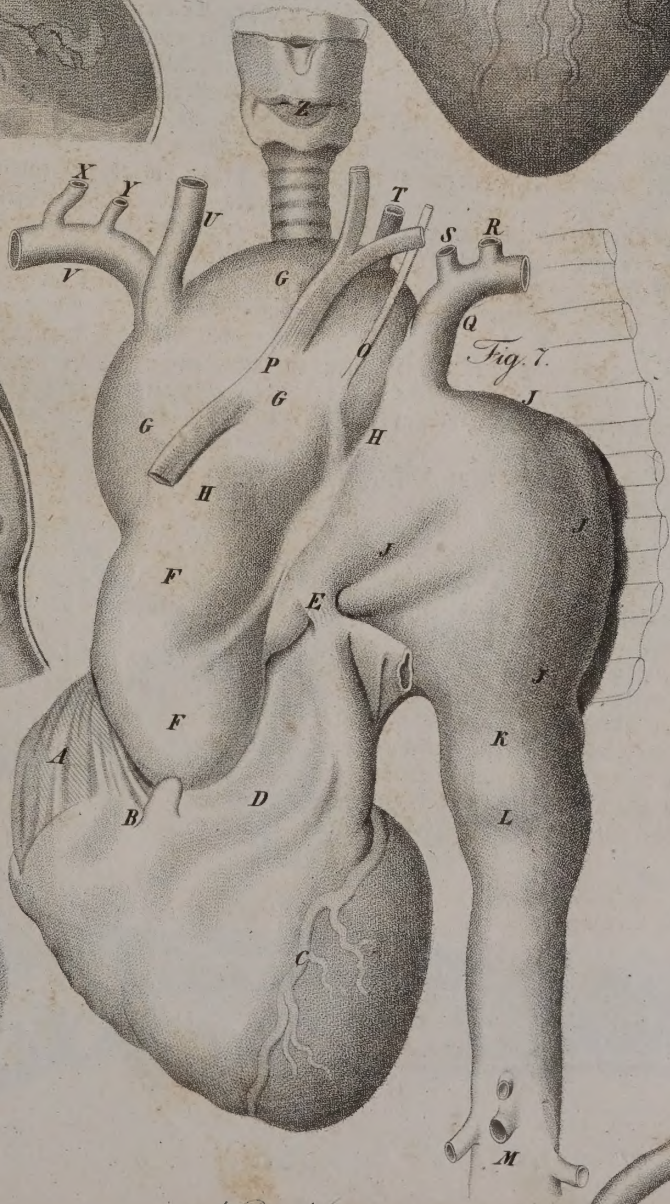

Fig. 8.

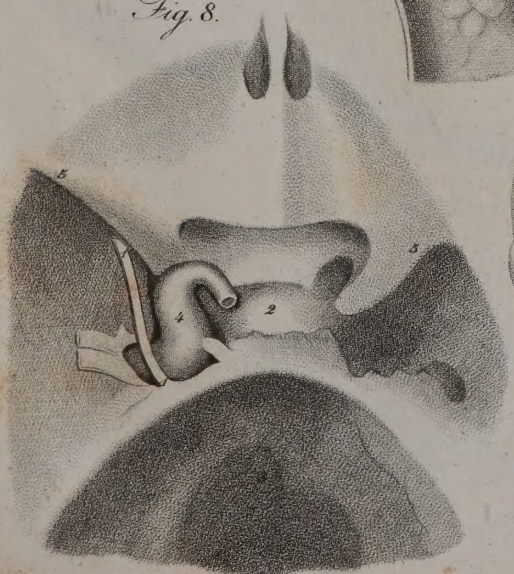

nach Breschet

Aneurisma.

Taf. CCCLXVI.

Fig. 1.

Fig. 2.

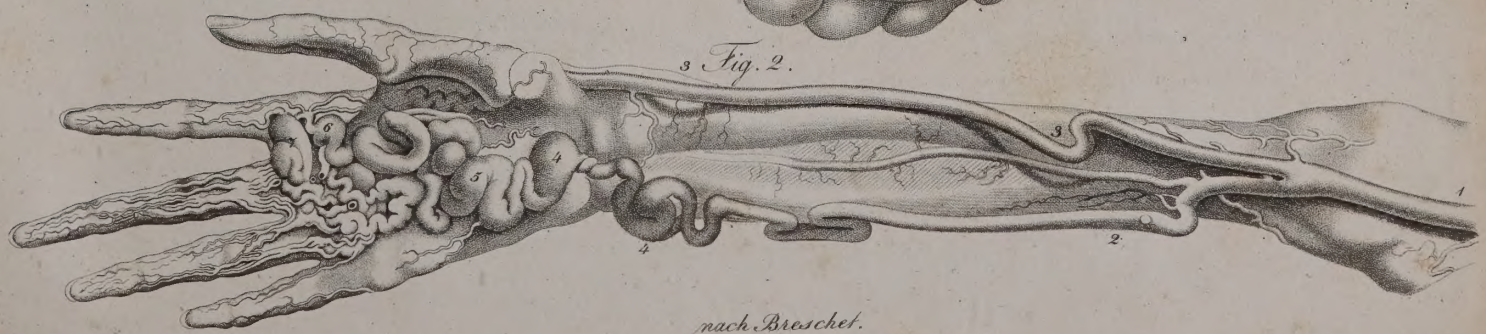

Fig. 3.

Fig. 4.

Fig. 5.

Fig. 6.

Fig. 7.

Fig. 8.

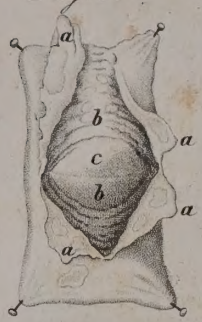

nach Breschet.

Fig. 1.

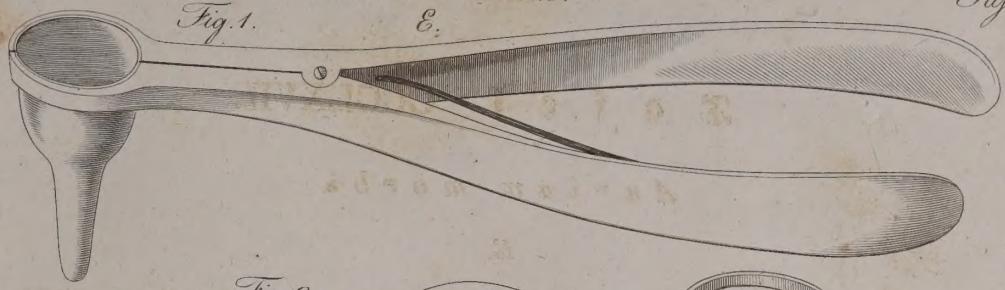

Fig. 2.

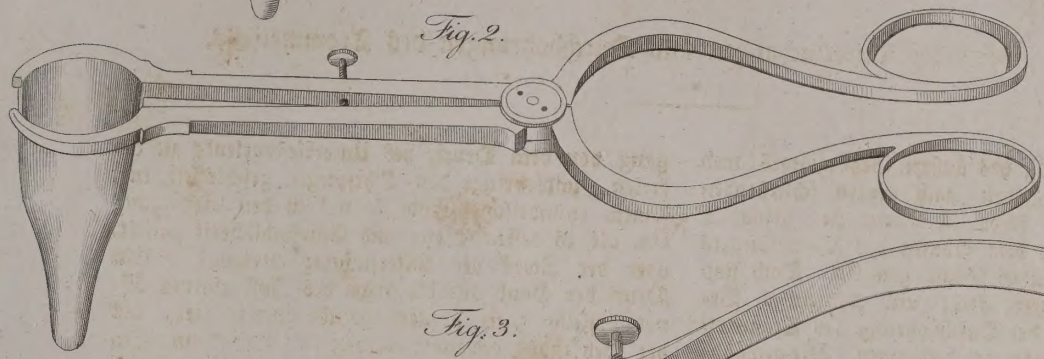

Fig. 3.

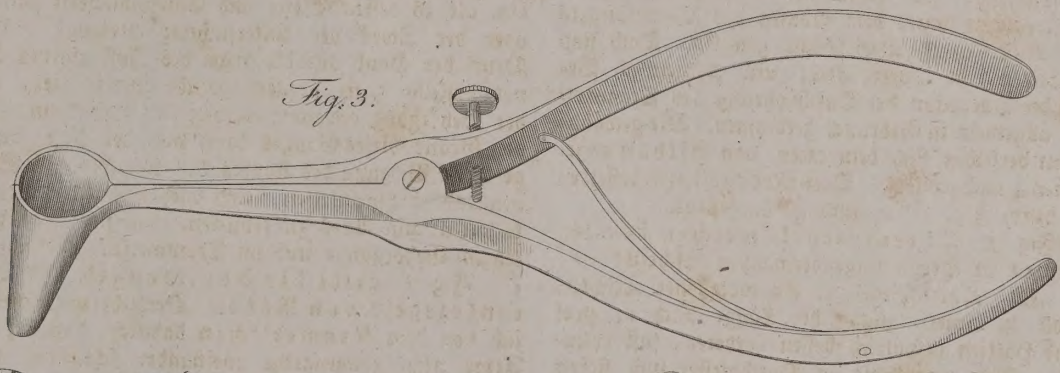

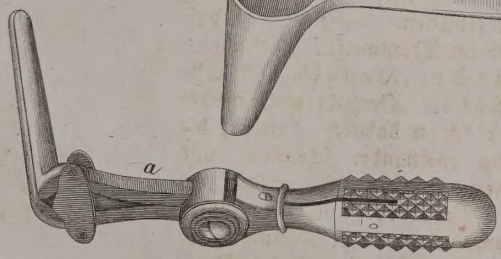

Fig. 4.

Fig. 5.

Fig. 6.

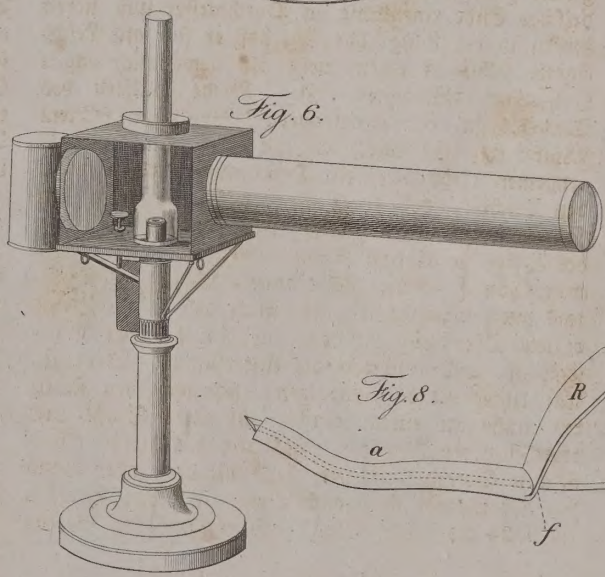

Fig. 8.



Fig. 7.

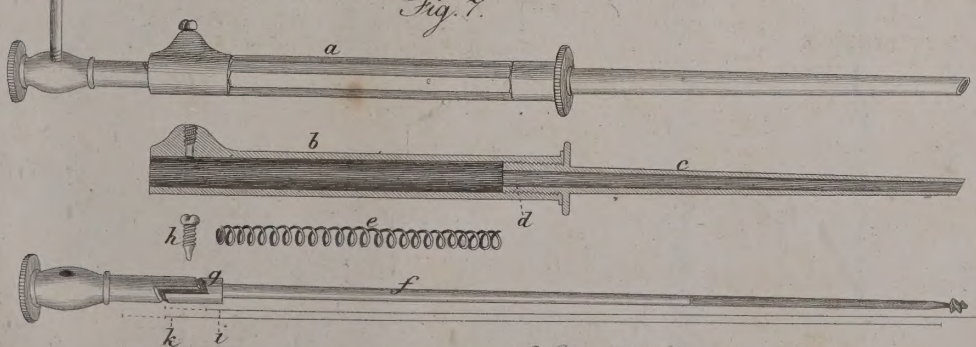

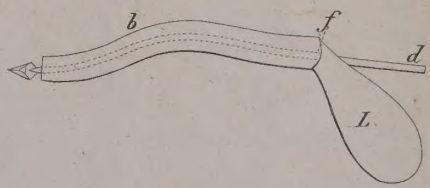



nach Kramer, Weiss, Gairal und Originalzeichnungen.

Labium leporinum.

Fig. 1. Fig. 2. Fig. 3. Fig. 4. Fig. 5. Fig. 6. Fig. 7. Fig. 8. Fig. 9. Fig. 10. Fig. 11. Fig. 12. C. Fig. 13. Fig. 14. Fig. 15. Fig. 16.

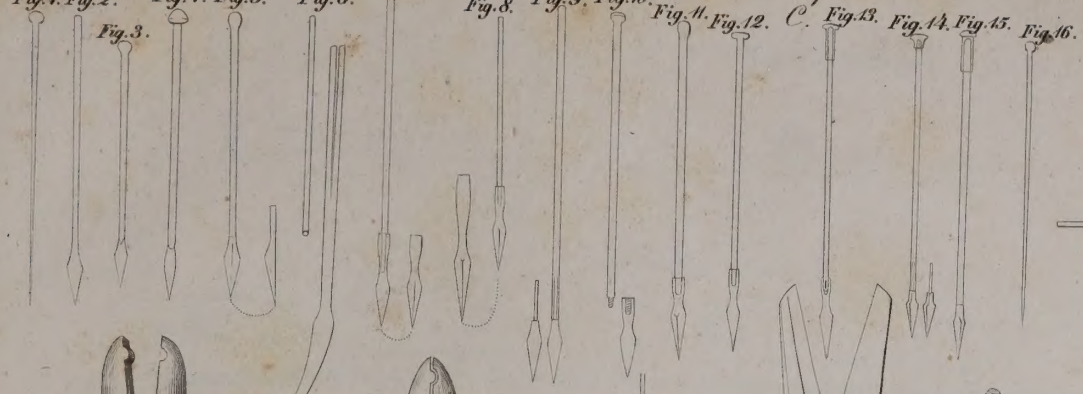

Fig. 23.

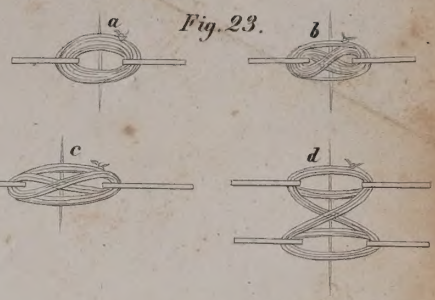

Fig. 24.

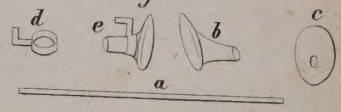

Fig. 18.

Fig. 22.



Fig. 19.

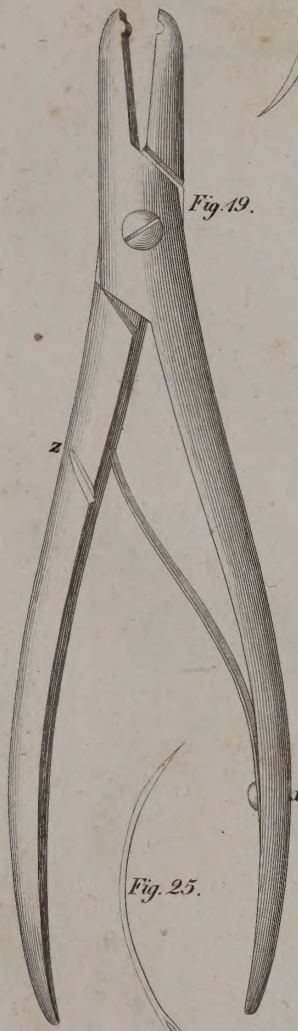

Fig. 21.

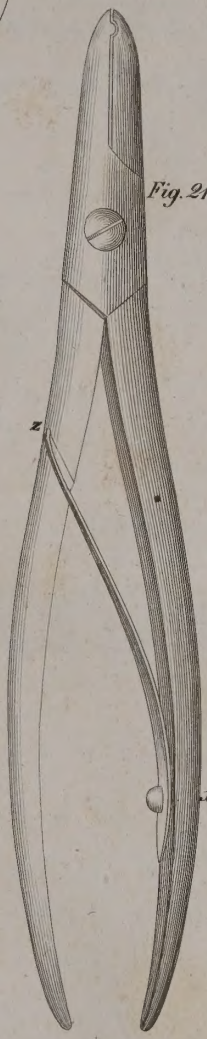

Fig. 20.

Fig. 17.

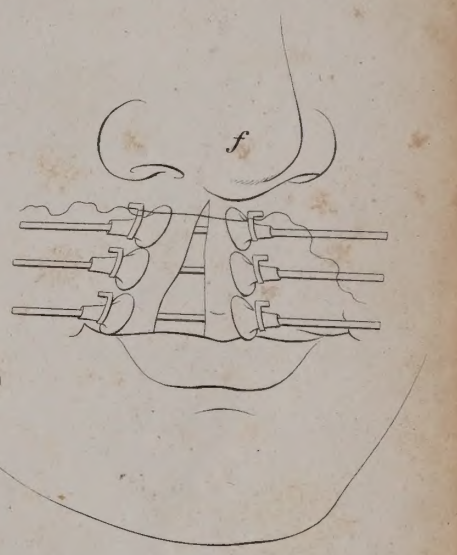

Fig. 25.

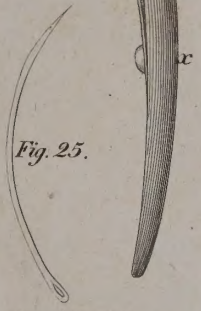

Fig. 26.

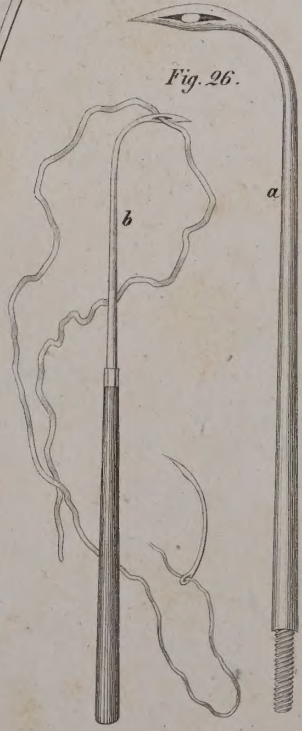

Fig. 29.

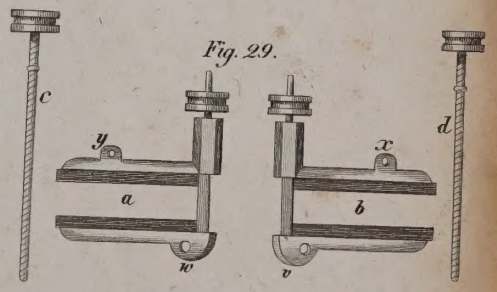

Fig. 27. a

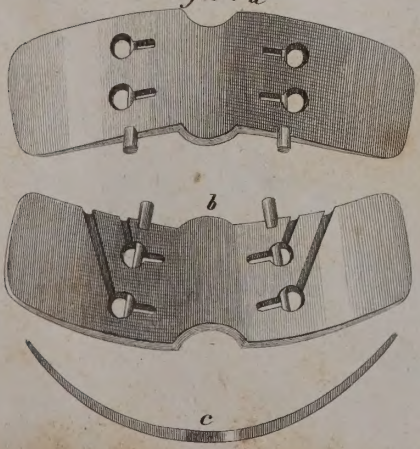

Fig. 28.



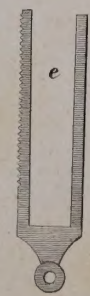

Fig. 30.

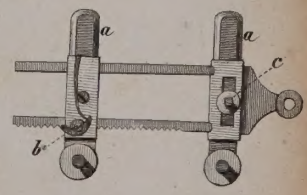

nach Originalzeichnungen, Meyer, Rieg und Seerig.

Aurium morbi.

F.

Taf. CCCLXIX.

Fig. 1.

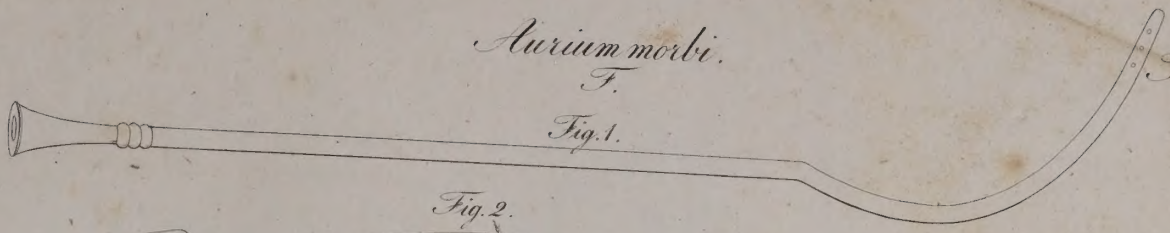

Fig. 2.



Fig. 3.



Fig. 4.

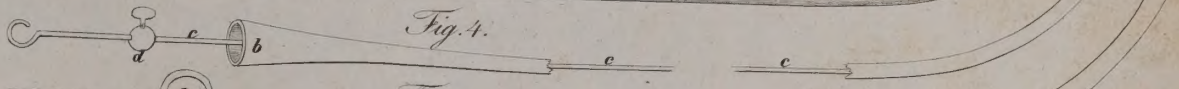

Fig. 6.

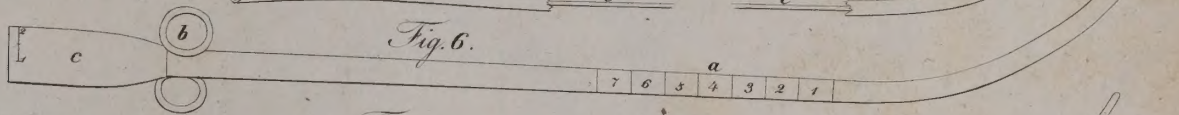

Fig. 5.



Fig. 7.



Fig. 8.



Fig. 9.



Fig. 10.



Fig. 12.

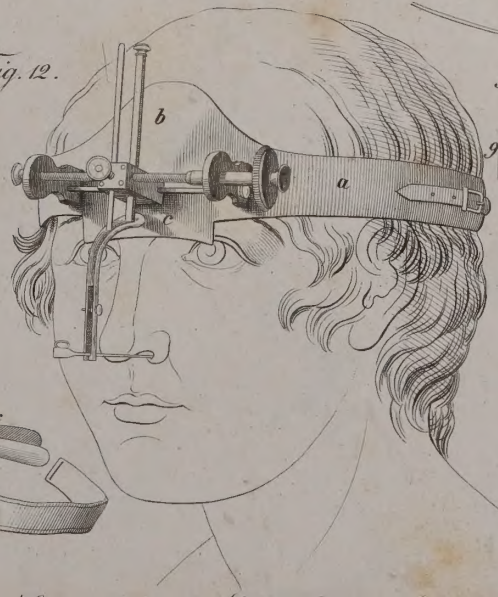

Fig. 13.

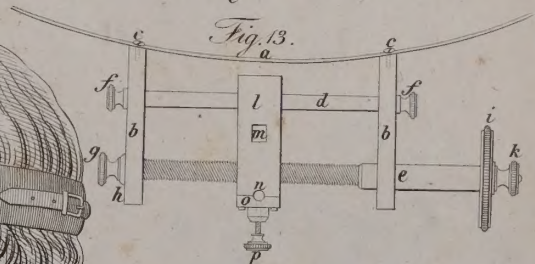

Fig. 11.

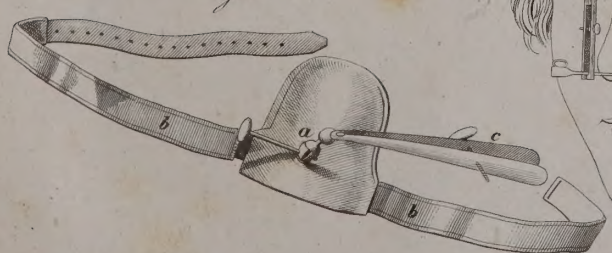

Fig. 15.

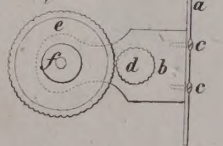

Fig. 14.

Fig. 1.

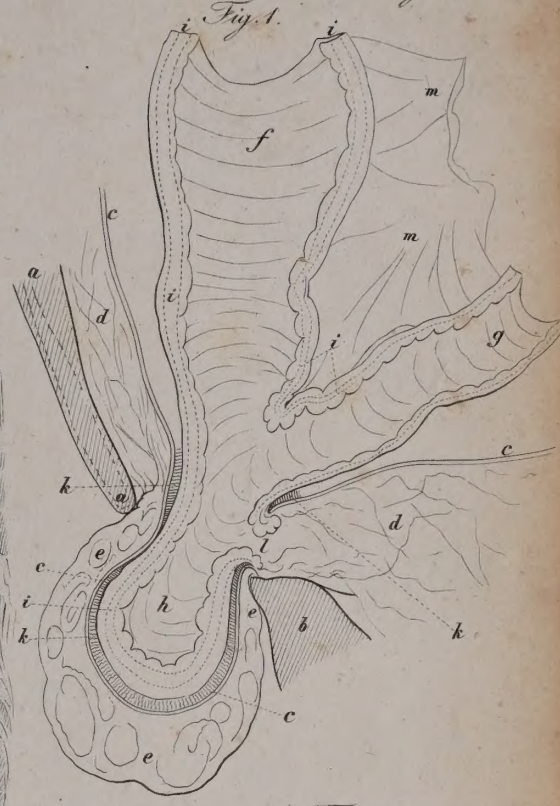

Fig. 2.

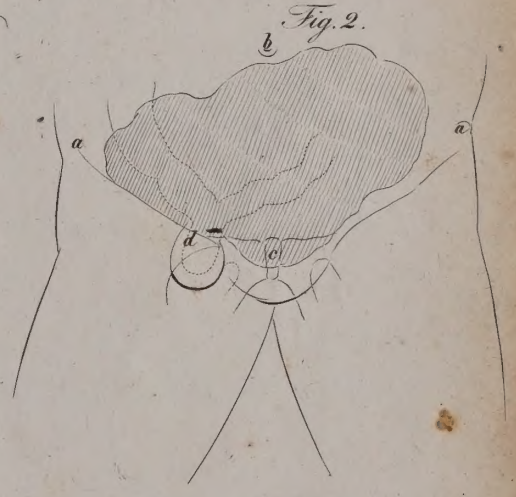

Fig. 3.

Fig. 5.

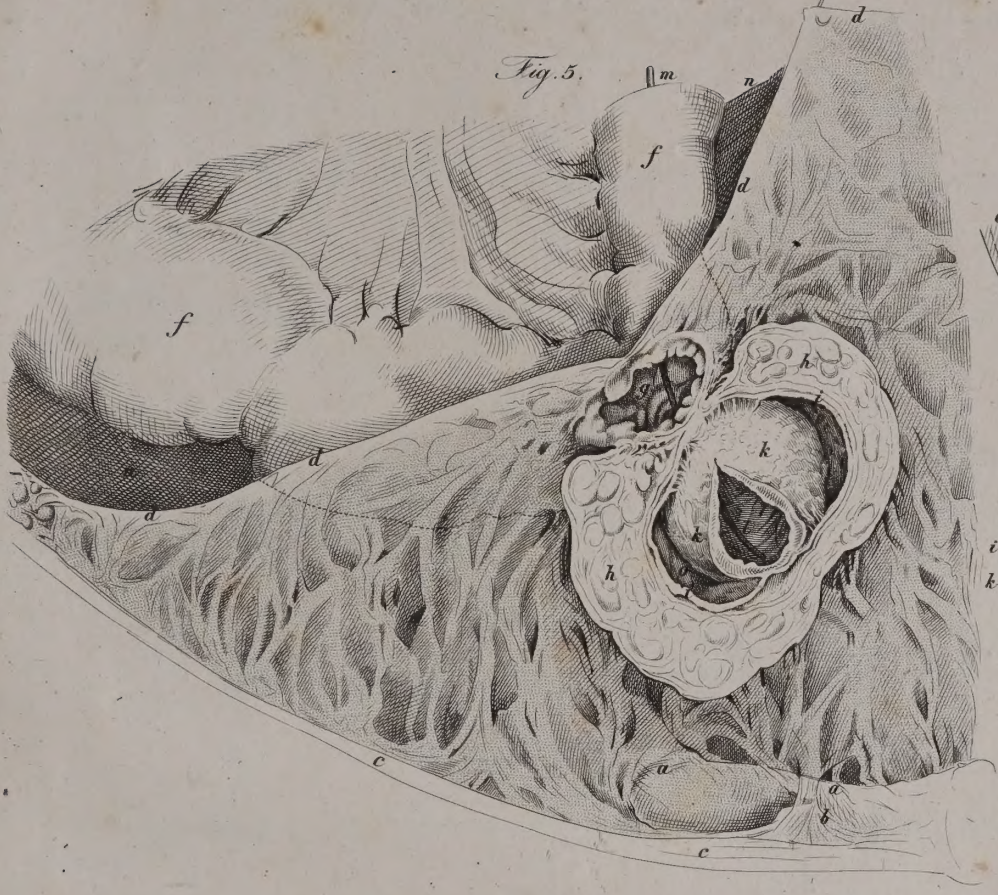

Fig. 4.

Lithotomia.

Fig. 1.



Fig. 2.



Fig. 3.



Fig. 4.



Fig. 5.



Fig. 6.



Fig. 7.



Fig. 8.



Fig. 9.



Fig. 10.



Fig. 11.



nach Originalzeichnungen.

Fig. 4.

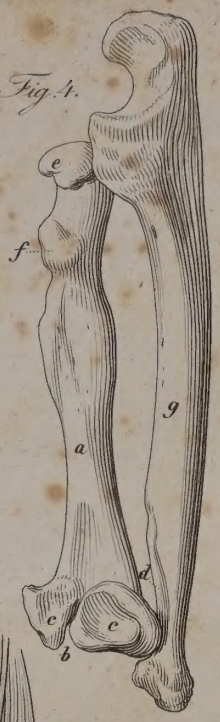

Fig. 5.

Fig. 1.

Fig. 2.

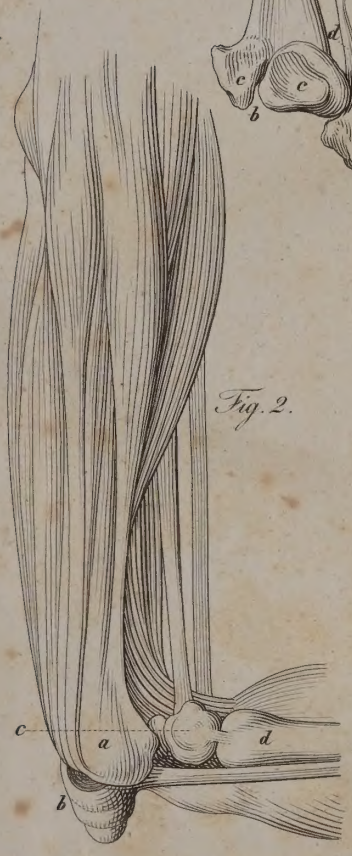

Fig. 3.

Fig. 6.

Fig. 7.

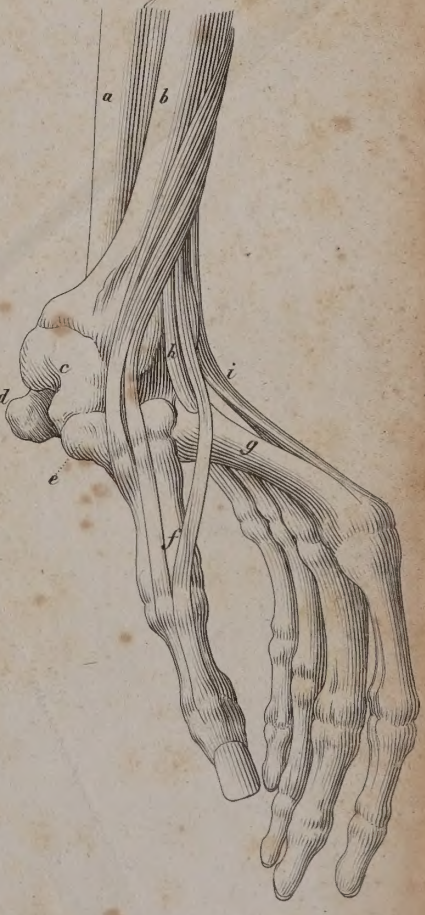

Fig. 8.

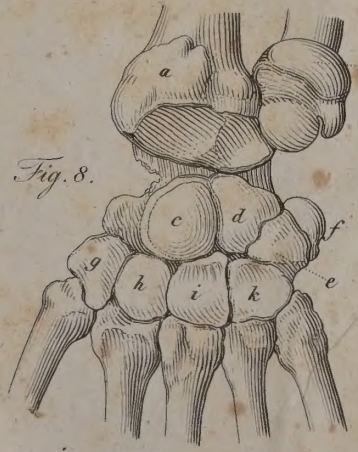

nach Cruveilhier.